

# **Outcomes of double miniplate osteosynthesis in the immediate management of infected mandible fractures**



**UNIVERSITY** *of the*  
**WESTERN CAPE**

**Zain Dangor**  
**3582337**

**A thesis submitted in partial fulfilment of the requirements for the MChD degree in  
Maxillofacial and Oral Surgery**

**Supervisor: Dr. D. A. Smit**  
**Co-Supervisor: Dr. G. Hein**

**2020**

# TABLE OF CONTENT

|   |      |
|---|------|
| TABLE OF CONTENT                                | i    |
| DEDICATIONS                                     | iii  |
| ACKNOWLEDGEMENT                                 | iv   |
| DECLARATIONS                                    | vi   |
| LIST OF ABBREVIATIONS                           | vii  |
| LIST OF APPENDICES                              | viii |
| KEY WORDS                                       | ix   |
| ABSTRACT  | x    |
| LIST OF TABLES                                  | xi   |
| LIST OF FIGURES                                 | xii  |
| CHAPTER 1: INTRODUCTION                         | 1    |
| CHAPTER 2: LITERATURE REVIEW                    |      |
| 2.1 Epidemiology                                | 2    |
| 2.2 Anatomy of fractures                        | 2    |
| 2.3 Classification of fractures and wounds      | 3    |
| 2.4 Fixation methods                            | 4    |
| 2.5 Aetiology of infected mandible fractures    | 6    |
| 2.6 Traditional management                      | 7    |
| 2.7 Fixation methods                            | 8    |
| 2.8 Importance of antibiotics                   | 8    |
| 2.9 Outcomes of osteosynthesis                  | 9    |
| 2.10 Assessment of fracture healing             | 10   |
| 2.11 Analysis of previous research on the topic | 11   |

|                                      |    |
|--------------------------------------|----|
| CHAPTER 3: AIM                       | 12 |
| CHAPTER 4: OBJECTIVE                 | 13 |
| CHAPTER 5: METHOD AND MATERIALS      |    |
| 4.1 Study design                     | 14 |
| 4.2 Study site                       | 14 |
| 4.3 Study participants               | 14 |
| 4.4 Inclusion and exclusion criteria | 14 |
| 4.5 Surgical procedures              | 14 |
| 4.6 Post-operative protocols         | 17 |
| 4.7 Post-operative sepsis protocol   | 18 |
| 4.8 Parameter recordings             | 18 |
| 4.9 Data capture and analysis        | 19 |
| 4.10 Ethics approval                 | 19 |
| CHAPTER 6: RESULTS                   | 20 |
| CHAPTER 7: DISCUSSION                |    |
| 7.1 Introduction                     | 25 |
| 7.2 Age and Gender                   | 25 |
| 7.3 Infection and antibiotic therapy | 26 |
| 7.4. Fixation method                 | 27 |
| 7.5 Factors influencing prognosis    | 27 |
| 7.6 Limitation                       | 28 |
| CHAPTER 8: CONCLUSION                | 29 |
| CHAPTER 9: REFERENCES                | 30 |
| CHAPTER 10: APPENDICES               | 36 |

## DEDICATION

This thesis is dedicated to my loving wife, Tasmeeya and my angels, Amani, Ammarah and Mohammed for their sacrifice, motivation and continuous love and support throughout the years.



## ACKNOWLEDGEMENTS

Embarking on this journey to attain my MDS degree in Maxillofacial and Oral Surgery has been tremendous sacrifices, many late nights and hard work. I could not do this alone and thus would like to show my appreciation and gratitude to:

- The Almighty for granting me the knowledge, strength and capabilities. I am only successful because of his bounty and blessings.
- Prof. J. A. Morkel: Chief Specialist and Head of Department of Maxillofacial and Oral Surgery and Anesthesiology & Sedation at University of Western Cape, for his continuous support, motivation and encouragement. He has been instrumental to my successful completion of this study.
- My Supervisor, Dr. D. A. Smit: Senior Lecturer/Specialist: Department of Community Oral Health, for his continuous assistance and guidance. Providing valuable information and guidance to me for which I am highly grateful.
- My Co – Supervisor, Dr. G. Hein: Senior Specialist. Maxillofacial and Oral Surgery, for always having the time to assist me no matter the time and place. The vast knowledge passed on and the continuous encouragement.
- My pillar of strength and confidant; my wife, Tasmeeya for the sacrifice, motivation and continuous love and support throughout the years.

- To my fellow registrars for the support.
- To Dr. F. Tinchini, for his encouragement and guidance in the project.




## DECLARATION

I declare that this dissertation has been completed by me and has not been copied elsewhere.

Furthermore, it has not been submitted for any examination or degree at any other university.

All sources quoted and used, have been marked and acknowledged by complete references.




Zain Dangor

January 2020



## LIST OF ABBREVIATIONS

| <b>Terms</b>   | <b>Abbreviations</b> |
|--|----------------------|
| Cone-beam computed tomography  | CBCT                 |
| Computer Tomography  | CT                   |
| Fracture   | #                    |
| General Anaesthesia  | GA                   |
| Inferior alveolar nerve canal  | IANC                 |
| Intensive Care Unit  | ICU                  |
| Local Anaesthesia  | LA                   |
| Maxillomandibular fixation   | MMF                  |
| Open Reduction and Internal Fixation                                     | ORIF                 |
| Arbeitsgemeinschaft fur Osteosynthesefragen Craniomaxillofacial Fixation | AOCMF                |





## LIST OF APPENDICES

Appendix 1: Consent Form

Appendix 2: Patient Information Letter

Appendix 3: Data Capturing Sheet – Preoperative Assessment

Appendix 4: Data Capturing - Postoperative Assessment

Appendix 5: Research Ethics Approval letter

Appendix 6: Permission letter from Groote Schuur Hospital Research Committee



## KEY WORDS

- Infected
- Sepsis
- Mandible
- Fracture
- Fixation
- Miniplate
- Osteosynthesis



## ABSTRACT

**Introduction:** A common complication of poorly managed mandible fractures is infection. There is a consensus amongst clinicians in treating infected mandible fractures in an immediate setting. The approach includes drainage of the purulent discharge, debridement of the fracture, removal of teeth in the fracture line and immediate fixation. Fixation can be load bearing or load sharing in nature. Although clinicians advocate for the use of a reconstruction load bearing plate, a double miniplate fixation could be an alternative.

**Aim:** The aim is to assess the outcomes of double miniplate osteosynthesis in the immediate management of infected mandible fractures

**Material and method:** A prospective cohort study was conducted. The sample size was 20 (n =20). Infections were treated with an incision and drainage and the fractures fixated with a double miniplate fixation system. Pain scores, fracture union, fracture stability and surgical times were measured. Follow-up visits included one week, six weeks and three months respectively.

**Results:** Mandibular angle fractures were most commonly infected. The most common cause of infection were teeth in the line of fracture. The buccal fascial space was the most commonly involved fascial space in regard to spread of infection. Nineteen of the twenty cases attained fracture stability. However, complications commonly encountered were persistent infection and wound dehiscence.

**Conclusion:** Although a limited number of clinical cases were treated, the results correspond with the current literature when an immediate miniplate fixation protocol is used in infected mandible fractures. However, complications encountered in the study included the persistence of infection and wound dehiscence.

## LIST OF TABLES

|         |  |    |
|---------|--|----|
| Table 1 | Analysis of previous research on the topic                                     | 11 |
| Table 2 | Tooth in line of fracture  | 21 |
| Table 3 | Presence of infection in the mandible at different time intervals              | 22 |
| Table 4 | Five cases presenting with persistent infection and the fascial space involved | 22 |
| Table 5 | Gram-staining and culture with antimicrobial susceptibility                    | 23 |
| Table 6 | Presence of wound dehiscence at different time intervals                       | 24 |



## LIST OF FIGURES

|          |   |    |
|----------|---|----|
| Figure 1 | Illustrating load sharing in which the bone assumes most of the functional loads.   | 4  |
| Figure 2 | Illustrating load bearing in which the plate assumes 100% of the functional loads.  | 5  |
| Figure 3 | Illustrating fixation of a mandible fracture. A superior plate fixated in lines of tension and inferior plate in lines of compression respectively. | 17 |
| Figure 4 | Distribution of infection according to fascial spaces involved.   | 20 |
| Figure 5 | Bar graph showing sample distribution location of infected mandibular fracture.   | 21 |



# 1. INTRODUCTION

A common complication of mismanaged mandible fractures is infection. There is a consensus opinion among surgeons that an open mandibular fracture not treated within 48-hours is classified as an infected fracture (Maloney *et al.* 2001). Alpert *et al.* (2008) cited that an infected mandible fracture requires the presence of frank purulent drainage from the fracture site, either intra-orally or through an extra-oral sinus.

Infected mandibular fractures can further be sub-classified as primary and secondary infected, with the former defined as an infected fracture with no history of previous management and the latter in which the plates and screws had loosened, becoming unstable, compromised and insufficient (Alpert *et al.* 2008).

With reference to Cienfuegos *et al.* (2003), the AO Foundation simplified a protocol for management of infected mandible fractures. A diagnosis includes determining the reasons for infection and removing the cause. Removal of sepsis is of paramount. A combination of empirically based antibiotics with adequate incision and drainage is required. There are diverse protocols described for the management of infected mandible fractures (Alpert *et al.* 2008; Johansson 1988; Koury *et al.* 1994)

The controversy lies in the timing of fixation. There are surgeons who follow a more orthodox management protocol in which fixation is delayed, until infection is eliminated. Orthopaedic data has supported the conservative approach in which no hardware should be placed in a presence of infection (Chen *et al.* 2005).

Several authors alluded to the positives of rigid internal fixation, i.e., a reconstruction plate, which provide fracture stability and resolution of infection (Iizuka 1991; Koury *et al.* 1994; Alpert 2008). They demonstrated positive results with rigid fixation in the management of infected mandible fractures, of which all candidates treated attained osseous union and none requiring removal of the fixation devices.

## 2. LITERATURE REVIEW

### 2.1 Epidemiology

A few epidemiological studies have assessed the prevalence of maxillofacial fractures in South Africa (Mogajane *et al.* 2018). In an epidemiological study conducted by Bataineh (1998), the incidence of maxillofacial fractures were more commonly seen in the male population. These findings concurred with Natu *et al.* (2012) who noted the presence of males in eighty percent of cases treated, and Mogajane *et al.* (2018) who also noted eighty percent of cases involved were males of an age group between 20-39 years.

The evolution in modern high-speed travel, with the increasing prevalence of social violence has escalated facial trauma to a form of a social disease. In the South African demographics, injuries commonly associated with facial fractures were assaults followed by road traffic accidents (Mogajane *et al.* 2018).

### 2.2 Anatomy of fractures

The mandible has a unique ‘U-shaped’ configuration which articulates with the cranial base at the temporomandibular joints (TMJs). The dental occlusion forms the functional interface between maxilla and mandible. The internal structure of the mandible is bicortical in nature, with a thin medulla. The muscle attachments along the course of the mandible play a pivotal role in the internal forces placed on the mandible. These muscles include the muscles of mastication, which are the temporalis, masseter, medial pterygoid and lateral pterygoid respectively as well as the accessory muscles such as the suprahyoid muscles, which include anterior digastric, geniohyoid, genioglossus and hyoglossus muscles respectively (Cienfuegos *et al.* 2003). In harmony, the mandible functions as a functional unit, however when a mandible fracture occurs, these muscles can potentially displace the fracture segment and disrupt healing process.

### 2.3 Classification of mandibular fractures and wounds

As described by Dingman and Natvig (1969), mandible fractures are systematized in several categories.

- The direction of fracture, whether the fracture is favourable in the horizontal and vertical plane;
- The severity of the fracture, closed or open to the oral cavity;
- The location of the fracture, symphysis, body, angle, condyle or coronoid process;
- The presence or absence of teeth in the jaw;
- The severity of the fracture is further classified as simple or comminuted. Simple fractures are characterized by only a single fracture line break whereas comminuted fractures are characterized by multiple fracture lines and bone fragments.

A comprehensive AOCMF classification was proposed by Cornelius *et al.* (2014).

- Mechanism (bending, burst or avulsive)
- Location of the fracture (symphysis, body, angle, coronoid or condyle)
- Number of fractures (single, double, triple or comminuted)
- Completeness of fracture (greenstick or complete)
- Fracture line course or shape (transverse, linear or oblique)
- Direction of fracture and favourability
- Dentition (presence of teeth adjacent to fracture and condition of teeth)
- Occlusion (no disturbance, malocclusion or edentulous)
- Presence of infection

The classification of wounds as described by Mangram (1999) by The Centre of Disease Control (CDC) included:

- Type I - clean – uninfected wound with no inflammation encountered.
- Type II - clean-contaminated – operative wound (respiratory, alimentary, urogenital) under control condition with no gross spillage.
- Type III - contaminated – operative wound, fresh or avulse with break in sterility and gross contamination.
- Type IV - infected – dirty and devitalized with presence of purulent discharge.



## 2.4 Fixation methods

In the attempt to overcome the disadvantages of intermaxillary fixation, the evolution of bone plates allowed for internal fixation. Initial plating material included the use of stainless steel. This lacked malleability, thus predisposing the plate to fracture. Michelet (1973) and Champy (1976) revolutionised the principles of fixation by using materials that are more malleable. Titanium followed, intriguing several authors in investigating its advantages. Lygidakis *et al.* (2007) yielded positive biocompatibility results to surrounding soft tissue adaptation, reporting no electrochemical changes on both titanium and surrounding tissue. However, in examining the effects of titanium on soft tissue, Langford *et al.* (2002) found traces of titanium in the soft tissues up to 13 years postoperatively. The soft tissue however, exhibited no evidence of inflammation (Langford *et al.* 2002). Osteosynthesis can be load bearing or load sharing in nature. A miniplate, an example of load sharing fixation, shares the load during function (Fig. 1).

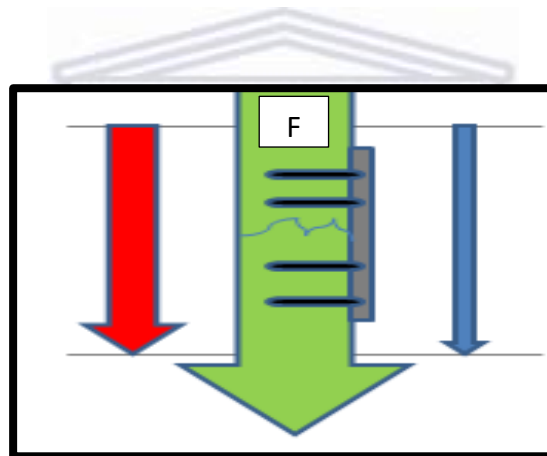


Fig. 1: Illustrating load sharing in which the bone (red arrow) and the miniplate (blue arrow) share the functional loads

A 2.3mm reconstruction plate, an example of a load bearing plate, primarily bears the full masticatory load during function (Fig. 2). The primary goal of fixation is to provide the maximum stability under functional load. It is believed that in an infected mandible, rigid fixation provides the ideal environment for faster resolution of sepsis, aiding in bone repair (Mehra *et al.* 2009).

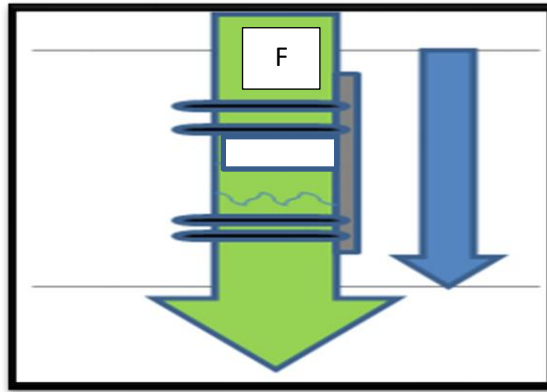


Fig 2: Illustrating load bearing in which the load bearing device i.e., the plate (blue arrow) assumes 100% of the functional loads

Champy *et al.* (1978) suggested that rigid osteosynthesis could be attained by engaging a single cortex. This concept however was challenged by several other authors who believed that to attain optimal rigid fixation bicortical fixation was essential (Levy *et al.* 1991; Choi *et al.* 1995, and Haug *et al.* 1996).

The stability at the fracture site is created by the fundamental relationship between the bone ends and the hardware, in which the frictional resistance between the two respectively creates the ideal fixation force. It is for this reason that load-sharing osteosynthesis cannot be used in large fracture defects or comminuted fractures, due to the lack of bony buttressing at the fracture site (Cienfuegos *et al.* 2003).

In considering the use of miniplates as a fixation method, several factors should be considered. These include the location and nature of the fracture. Minimal comminution with larger intact bone segments are ideal. Bolourian *et al.* (2002) investigated the treatment approach utilized by Champy *et al.* (1978) by using 2.0 mm miniplate fixation with two weeks of intermaxillary fixation. All cases were treated successfully achieving primary bone healing, However, two cases developed wound dehiscence which was treated conservatively.

## 2.5 Aetiology of infected mandible fractures

The aetiology of infection in fractured mandibles is multifactorial and can be attributed to fracture instability, mobile hardware, diseased teeth within the fracture line, patient non-compliance, and delayed management (Benson *et al.* 2006).

Zachariades *et al.* (1995) reported that the severity of injury contributes to the development of infection. Comminution, gross displacement, and complex multi-fragmental fractures are anatomical factors that can contribute to the development of infection. A study by Ellis *et al.* (2003) noted a strong relationship between severity of trauma and infection. Four of the six infected mandibles documented in the study were associated with multi-fragmental fractures (Ellis *et al.* 2003). Another study found that gunshot injuries were associated with increased bone fragmentation, which were associated with wound contamination and subsequent infection (Apert *et al.* 2008).

Delayed treatment is associated with increased risk of infection (Moreno *et al.* 2000). In a study of 334 patients, Malanchuk *et al.* (2007) reported a significant association between delayed treatment of greater than seven days and the development of infection.

It was concluded, that a major contributor to infection in delayed treatment, is fracture instability. Alpert *et al.* (1998) noted that the micro-movements between the fracture segments destabilized the haematoma, which directly induced microorganisms into the fracture site.

There is controversy regarding the ideal management of teeth within the fracture line with great concern directed to the possibility of inducing infection (Shetty 1989). Contamination can occur through the pulp or from the surrounding periodontal ligaments. There is a consensus among surgeons to remove the tooth only if it presents with loss of vitality, root fracture, loosening, or when interfering with fracture reduction (Ghanem *et al.* 2011). Infection however, may still occur. Alpert reported on secondary infection to socket contamination by the bacteria in the oral biofilm (Alpert *et al.* 1998).

Infection alters the balance between bone loss and repair, resulting in a painful non-union (Loi *et al.* 2016). The presence of an infection stimulates a local inflammatory response at the site of injury, creating a robust increase in pro-inflammatory cells and cytokines. In the acute stage of osteomyelitis, Karnes *et al.* (2015) reported a marked increase in TNF- $\alpha$  in the fracture sites contributing to the apoptosis and non-union.

## 2.6 Traditional management

A controversy exists in the literature concerning management of infected mandible. To achieve satisfactory results, surgeons should aim in restoring pre-trauma aesthetics, function and occlusion (Mehra *et al.* 2009).

Traditional methods were aimed to eradicate the infection, i.e., by incision and drainage with removal of tooth from the fracture line and treatment with long-term antibiotics. Prolonged intermaxillary fixation was historically used for fracture stabilization (Fischer-Brandies *et al.* 1984); however, this approach did have disadvantages. Not only were there malunion and non-union of fracture segments encountered, but patients had to endure multiple debridement procedures (Alpert *et al.* 2008). The downside to non-union was the need for an additional donor site for bone grafting to repair the bone defect (Benson *et al.* 2006). Several authors in the oral and maxillofacial field tend to disagree. Souyris *et al.* (1980) reported successful bone union in 25 mandibular fractures which were managed conservatively in the presence of infection in postoperative fixation. This publication reflected the findings in an earlier publication by Rittman in 1974 who experimentally conducted osteosynthesis on sheep femurs in the presence of *staphylococci* infection (Rittman *et al.* 1974).

Mehra *et al.* (2009) followed the immediate management protocol. Forty-four patients were included in the study. Eighteen patients were treated with soft tissue infection and twenty-six treated with bone infection. An overall success rate was 95% and the success of immediate management coincides with a previous study by Benson who achieved bone union in twenty of the twenty-one cases (Benson *et al.* 2006).

An important aspect in the management success is the removal of dead bone and sequestrum. It is essential for the screws to engage healthy bone in order to provide adequate fixation. Engagement of the infected bone will not provide adequate fixation and will lead to loosening of screws with worsening of the infection (Alpert *et al.* 2008; Cahill *et al.* 2015).

## **2.7 Fixation methods in sepsis**

There is controversy amongst clinicians on whether load-sharing fixation is comparable to load bearing fixation in providing rigid fixation in an infected mandible fracture (Johansson *et al.*, 1988). Koury and Ellis, (1994) describes the use of rigid fixation as biologically sound, reporting low rates of complications. In a study conducted by Ghanem *et al.* (2011) a 2.3mm reconstruction plate was implemented as a fixation method for the management of unstable fractures. Two groups were compared with each other. One group fixed with three screws on each side, and the other fixed with two screws. The group fixed with the 3-screw system showed a higher rate of bone union on postoperative radiographic assessment (Ghanem *et al.* 2011).

Johansson *et al.* (1988) investigated the use of miniplate osteosynthesis in infected mandibles. A success rate of 76% was achieved. However, a high complication rate was found, which was attributed to poor patient care, i.e., alcohol abuse and poor oral hygiene practice (Johansson *et al.* 1988). An earlier publication by Johansson *et al.* (1983), in which a single miniplate fixation protocol was employed; stated that if the fixation system was not mobile, nor any signs of bone resorption were present, the miniplate itself may be left within the infected site. Other sources of infection should be considered, which include a tooth within the fracture line and wound dehiscence (Johansson *et al.* 1983).

## **2.8 Importance of Antibiotics**

Antibiotics play a pivotal role in the management of infection. In the management of non-infected mandible fractures, a protocol advocated by Laskin, (2003) was the use of preoperative prophylaxis with a postoperative antibiotic course of no longer than 12 hours.

However in comparison, a double-blinded randomized control trial conducted by Abubaker *et al.* (2001), noted that poor patient care, i.e., poor oral hygiene practice, smoking, and alcohol consumption, was attributed to higher incidence of post-operative infection and that post-operative prophylactic antibiotics had no positive influence in reducing the incidence of infection.

An infected mandible fracture is classified as a dirty wound (Ben *et al.* 2016). Maloney (2001) showed that a varying degree of soft tissue injury had a direct influence on the infection rate. The intra-oral flora contains a diverse polymicrobial population with a larger number of bacteria capable of producing infection (Mdlalose 2015). This is supported by a study done by Sarvan (2009) who found odontogenic infection to be the most common cause of orofacial sepsis. Furthermore, Amaidas (1990) found a prevalence of 56.7% for odontogenic causes and 21.7%, where teeth were left in the fracture line.

“Empiric antibiotic therapy”, is based on the nature of local pathogens and the antibiotic sensitivities, as well as by the nature and severity of the patient’s condition, duration of hospitalization, location in the hospital (general ward vs. ICU), previous infection or colonisation with particular pathogens and previous antibiotic therapy” (Oliver 2013). Several clinicians commonly prescribe a combination of penicillin and metronidazole as the regimen of choice for empiric therapy (Alpert *et al.* 2008; Mehra *et al.* 2009; Mdlalose 2015).

## **2.9 Outcomes of osteosynthesis**

The presence of infection after fixation may represent either an unresolved pre-treatment infection or a post-operative site infection that had developed as a complication of treatment.

Risk factors that may influence the outcome of treatment include the presence of infection prior to treatment, pre-operative site preparation, antibiotic prophylaxis, surgical technique and wound management (Ban *et al.* 2016).

In achieving success in treatment, the osteosynthesis system must stabilize the inter-fragmentary movements. It is reported that micro-movement between inter-fragments play a role in callus formation (Marsh and Li 1999).

However, macro-movements is associated with malunion, non-union, infection and screw loosening (Abdelfadil *et al.* 2013).

## **2.10 Assessment of fracture healing**

It is crucial to determine the weight-bearing status under function, and diagnosis and treatment of non-union. Fracture healing can be assessed under three categories: clinical examination assessing stiffness and stability, imaging studies assessing new bone formation and serologic markers of healing (Morshad 2014).

There is a no clear standardized clinical definition of fracture union. This can be affected by observer variability among clinicians and researchers. Stiffness and stability correlates well with strength in the early phases of callus formation after injury (Morshed 2014). A systematic review by Morshad *et al.* (2008), noted the defining criteria for successful healing included the absence of pain or tenderness at the fracture site on weight-bearing and the absence of pain on palpation at the site of fracture.

Despite the advancement in computed imaging techniques, plain radiography remains the most used radiographic tool for assessing fracture healing. Reasons included a lower cost, wider availability, and lower radiation exposure (Morshad 2014). However, a study by Davis *et al.*, (2004) questioned the reliability in detecting healing in internally fixated bone being inconclusive in determining the stage of union. Kawai *et al.* (1997) assessed the radiographic changes during bone healing after mandibular fractures with different treatment modalities. During the first month non-osteogenic changes was more common. However, at two months, osteogenic changes predominated and at three and four months respectively, union was established radiographically by the presence of new bone formation and absence of fracture discontinuity (Kawai *et al.* 1997).



## 2.11 Analysis of previous research on the topic

An in depth search using PubMed / ClinicalKey and the Cochrane library making use of the keywords: ‘mandible fracture’ in combination with the keywords: ‘miniplate osteosynthesis’, ‘infected mandible fractures’ and ‘immediate management of infected mandible fracture’, a total of 16 articles were examined of which four met the criteria for the topic under investigation (Tab. 1). Studies undertaken by Alpert *et al.* (2008), Mehra *et al.* (2009) and many others investigated the success of a reconstruction in the management of infected mandible fractures. Mdlalose (2015) made use of a randomised control study to compare results of immediate versus delayed management of infected mandible fractures. Johansson *et al.* (1988) was the only research paper that investigated miniplate osteosynthesis in infected mandible. A Champy miniplate was used to treat infected angle fractures of the mandible (Johansson *et al.* 1988).

| Study   | Sample size                                | Outcomes   |
|---|--|--|
| Johansson <i>et al.</i> 1988<br><b>Miniplate osteosynthesis of infected Mandible Fractures</b>    | Prospective study including of 37 patients | 42 infected fractures treated.<br>Nine patients developed post-operative infection   |
| Mdlalose 2015<br><b>Immediate versus delayed Surgical management of septic mandible fractures</b> | Randomised control trial of 20 patients    | No statistically difference in clinical parameters.<br>However, the hospital time spent was less in the immediate protocol |
| Mehra <i>et al.</i> 2009<br><b>Rigid internal fixation of infected mandible fractures</b>         | Retrospective study including 44 patients  | The protocol was successful (100%) in treating for soft tissues infection and 92% for hard tissue infections.              |
| Alpert <i>et al.</i> 2008<br><b>Contemporary management of infected mandible fractures</b>        | Prospective study including 19 patients    | 21 infected fracture treated with 20 achieving primary union.  |

Table 1: Analysis of previous research on the topic




### **3. AIM OF STUDY**

To assess the outcome of double miniplate osteosynthesis in the immediate management of infected mandible fractures.



## 4. OBJECTIVES

1. To analyse the age and gender of the patients presenting with infected mandible fractures.
2. To assess the following clinical parameters at week 1 post-operative (T0), 6 weeks post-operative (T1) and 3 months post-operative (T2):
  - Infection
  - Wound dehiscence
  - Fracture stability
3. To assess the following radiological parameter at day one:
  - Status of fixation devices
4. To assess the following radiological parameters at 3 months post-operative (T2):
  - Status of fixation devices
  - Fracture healing
5. To compare the clinical parameters of T0, T1 and T2.



## **5. MATERIALS AND METHODS**

### **5.1 Study design**

A prospective cohort study based on the principles of fracture management in the presence of infection was conducted. A double miniplate fixation method was employed in the immediate management of infected mandible fractures.

### **5.2 Study site**

The Department of Maxillofacial and Oral Surgery, Groote Schuur Hospital was chosen as the study site. The Department of Maxillofacial and Oral Surgery at Groote Schuur Hospital is one platform of the Faculty of Dentistry at the University of the Western Cape.

### **5.3 Study participant**

Patients presenting with infected mandible fractures were treated at the Department of Maxillofacial and Oral Surgery, University of Western Cape, Groote Schuur Hospital.

The sample size was 20 patients. A follow-up period over 3 months was used to assess the success for fracture union, fracture stability and to identify possible post-operative complications.

### **5.4 Inclusion and exclusion criteria**

Inclusion:

- Mandibular fractures, unilateral or bilateral in nature, not older than three weeks, with the presence of purulent discharge in the fracture site
- Fracture sites included angle, body, and symphysis.
- Patients who were 18 years and older
- Patients with well controlled systemic medical conditions i.e. Diabetes Mellitus, HIV positive patients with a CD4>400

Exclusion:

- Severely medically compromised patients
- Severe cellulitis or the presence of Ludwig's Angina
- Presence of pathological fracture
- Comminuted fractures
- Complex fracture
- Severely atrophic mandible
- Condyle fractures
- Chronic osteomyelitis
- Previous radiation therapy
- Patients on Bisphosphonate therapy

## **5.5 Surgical procedure**

Based on surgical protocols of general and maxillofacial surgery approved and employed in previous surgical studies, the surgical procedure for the above study employed the surgical protocol used in the Department of Maxillofacial and Oral Surgery, University of Western Cape, Tygerberg and Groote Schuur Academic Hospitals.

### **5.5.1 Pre-operative protocol**

Patients were assessed for underlying co-morbidities and previous illnesses that would require further pre-operative special investigations, which may include chest radiographs and echocardiograms. All patients were assessed regarding inflammatory markers which included full blood count (FBC) and C-reactive protein (CRP).

### **5.5.2 General Anaesthesia**

All surgeries were performed under general anaesthesia. Nasal intubation was the choice of intubation and throat packs were placed.

### **5.5.3 Surgery**

The surgical procedure was performed by a single operator. Local anaesthesia with a vasoconstrictor (Xylotox E80A 2%) was administered to control intraoperative bleeding.

### **5.5.4 Incision and drainage**

An incision and drainage was performed on each case, which included an extra-oral skin and intraoral incision. A pus swab was taken and sent for microbial culture and sensitivity analysis. Corrugated drain/s were placed through the extra-oral incision for drainage and grossly carious teeth were extracted. Copious irrigation with saline followed.

### **5.5.5 Open reduction internal fixation**

A full thickness mucoperiosteal flap was raised exposing the fracture ends. Fracture debridement followed, with the removal of tooth fragments and necrotic bony fragment. The fracture was reduced. The pre-injury occlusion was restored using intermaxillary fixation.

Synthes Matrix Mandible<sup>®</sup> was choice of plating system employed uniformly for all the cases. A double miniplate fixation was used, which included a 1.25mm miniplate at the superior border, in the zone of tension and 1.5mm miniplate at the lower border, in the zone of compression, respectively with a minimum of four screws per plate (Fig. 3). The latter protocol used is prescribed by the AOCMF (Priem *et al.* 2012). Intermaxillary fixation was released to assess the occlusion and eyelet wires/archbars removed prior to extubation.

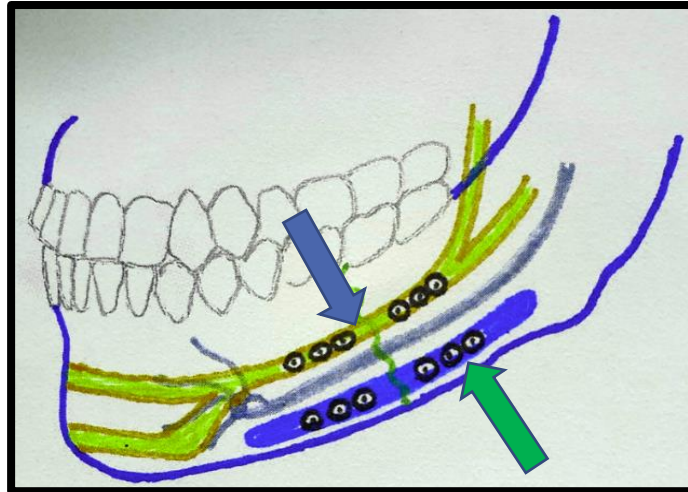


Figure 3: Illustrating the ideal lines of osteosynthesis. A superior plate (blue arrow) fixated in lines of tension and inferior plate (green arrow) in lines of compression respectively (Picture: Z Dangor)

### 5.5.6 Closure of wound

An interrupted suture technique was employed for wound closure, using 3/0 chromic catgut absorbable sutures. A corrugated drain was placed from extra-orally and secured using 2/0 nylon in an interrupted suture technique. The protocol for closure was followed for each patient treated.

### 5.6 Post-operative protocol

1. Patients were nursed in a low Fowler's position.
2. Irrigation of drain with saline were done periodically at 6-hour intervals. Drains were removed in the absence of pus discharge at day two.
3. Medical treatment protocol included:
  - Augmentin 1.2g IVI 8-hourly
  - Metronidazole 500mg IVI 8-hourly
  - Ibuprofen 400mg orally 8-hourly
  - Paracetamol 500mg orally 8-hourly
  - Chlorhexidine gluconate 0.2% mouth rinse 5ml, 6-hourly
  - Patients discharged on Paracetamol and Ibuprofen for analgesia
  - Escape opioid analgesia was prescribed

(N.B.) - If penicillin allergy was noted, clindamycin 300mg IVI 6-hourly was prescribed. Antibiotics therapy was adjusted according to the results from the culture and sensitivity of pus swab.

### **5.7 Post-operative sepsis protocol**

In the event of a persisting infection, the treatment protocol employed included:

- Repeated incision and drainage, with placement of extra-oral corrugated drain.
- Routine six hourly irrigation of the drains with saline
- If sepsis was related to fixation failure, manipulates were removed and followed by the placement of a load bearing reconstruction plate

### **5.8 Parameter recordings**

Clinical parameters and blood tests, which included full blood count and C-reactive proteins were measured both pre- and post-operatively. A Visual Analogue Scale (VAS) was used to periodically assess the pain. This provided adequate data to the clinician in determining whether patient was in state of sepsis or recovering. Fracture stability was confirmed clinically by manual manipulation of the fracture site. The researcher's ability to assess stability was verified by a specialist maxillofacial surgeon.

Radiographs that included a pantomograph and a posterior-anterior mandible radiograph were taken pre-operatively to determine the classification of the fracture favourability and the degree of fracture displacement. Post-operative radiographs were taken at day one post-operative to determine adequate reduction of fractures and at three month post-operatively to assess for adequate fracture union. Post-operative recalls recall visits was included at week 1 post-operative (T0), 6 weeks post-operative (T1) and 3 months post-operative (T2).

## **5.9 Data capture and analysis**

Data was captured on a Microsoft Excel spreadsheet. Epi Info V7 was used to do statistical analysis.

## **5.10 Ethics Approval**

Ethical approval (BM18/5/26) was obtained from the UWC Bio-Medical Research Ethics Committee (BMREC) (appendix). All aspects of the proposed study have been designed in accordance to the UWC research ethics policy. Further permission was granted from the Groote Schuur Hospital (GSH) Research Ethics Committee (Appendix 6).

Due to the voluntary nature of the project, the study was clearly explained to the participants, along with any potential risks, benefits, compensation or complaints that may result due to taking part in this study.

Written and informed consent was obtained from all participants (Appendix 1 and 2). All participants remained anonymous and all information kept on a password-protected computer. All participants were also informed that they could withdraw from the study at any stage and that their decision would not negatively affect future treatment. There were no extra cost incurred by the patients as routine treatment protocols were followed. Routine radiographs were used and patients were not subjected to any additional radiation.



## 6. RESULTS

### 6.1 Age and gender information

Twenty patients (n = 20) with infected mandible fractures, of which 17 patients (85%) were males and three (15%) were females, participated in the study. The mean age was 34.7 years (SD = 10.3; range = 18 - 55). The mean age of the male, patients were 34.4 years and 36.3 years for females. There was no significant difference in mean age between males and females (p > 0.5).

### 6.2 Clinical parameters

#### 6.2.1 Fascial space involvement

The buccal space was the most common fascial space involved accounting for nine cases (45%). Six cases (30%) presented with submental abscesses, which were commonly associated with symphysis and parasymphyseal fractures (Fig. 4).

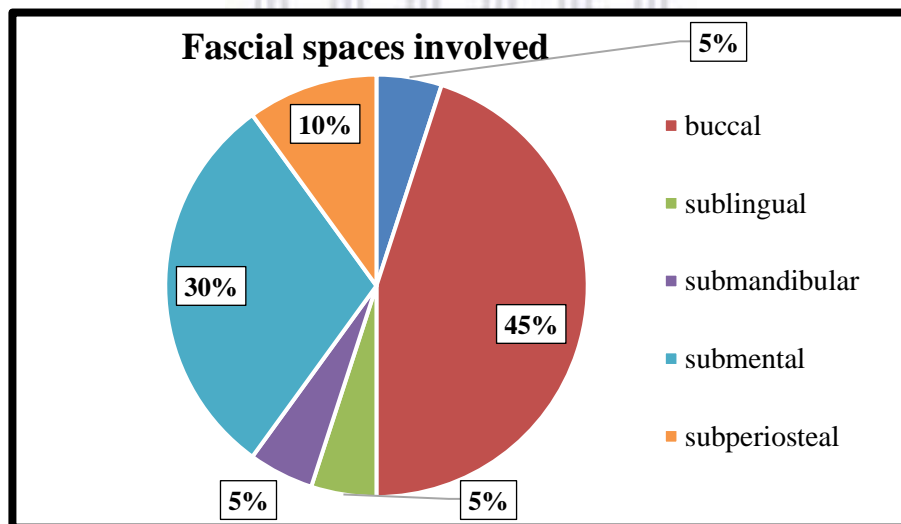


Figure 4: Distribution of infection according to fascial spaces involved

### 6.2.2 Fracture location and teeth in fracture line

Bilateral fractures were seen among 60% of the sample. Mandibular angle fractures were most common with almost half (40%) of the sample presenting with this fracture location. Parasymphyseal fractures were second most common location of infected fractures followed by body and symphysis respectively (Fig. 4).

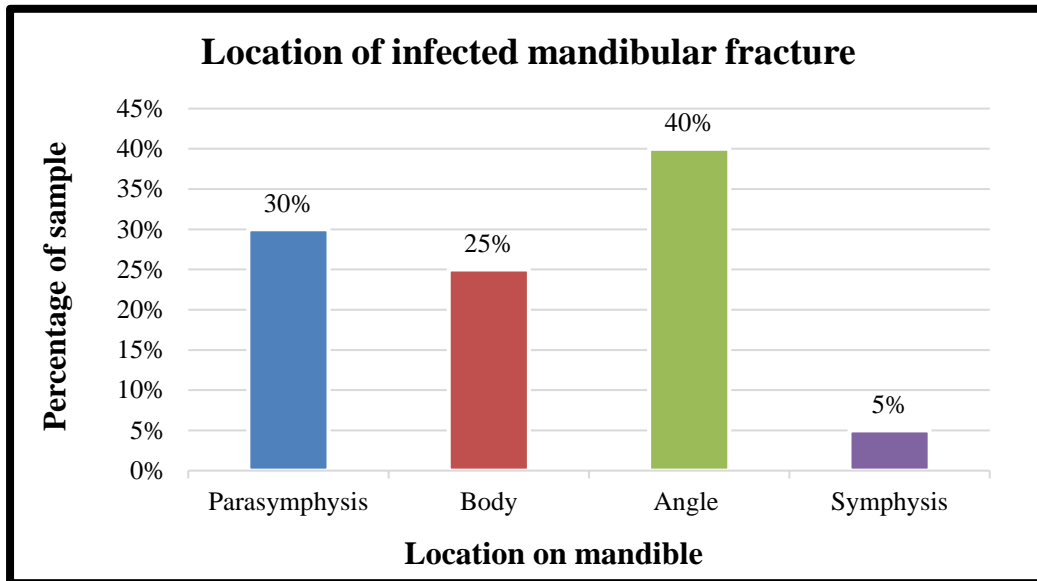


Figure 5: Bar chart showing sample distribution location of infected mandibular fracture

This assessment coincided, with presence of teeth in the line of fracture, in which ten cases were associated with molar teeth (Tab. 5).

|                 | n  | % of sample |
|-----------------|----|-------------|
| <b>Incisor</b>  | 2  | 10%         |
| <b>Canine</b>   | 1  | 5%          |
| <b>Premolar</b> | 3  | 15%         |
| <b>Molar</b>    | 10 | 50%         |
| <b>n/a</b>      | 4  | 20%         |
| <b>Total</b>    | 20 | 100%        |

Table 2: Tooth in line of fracture

### 6.2.3 Infection

In the post-operative phase, five patients presented with persistent infections. Subsequent to an incision and drainage; and oral antibiotics, the infections settled, with two patients presenting with infection at T1 (one month) and one patient at T2 (three months).

|                      |                   | <b>n</b> | <b>% of sample presenting with infection</b> |
|----------------------|-------------------|----------|--|
| <b>Time interval</b> | <i>Pre-Op</i>     | 20       | 100%   |
|                      | <i>Post-Op T0</i> | 5        | 25%  |
|                      | <i>Post-Op T1</i> | 2        | 10%  |
|                      | <i>Post-Op T2</i> | 1        | 5%   |

Table 3: Presence of infection in the mandible at different time intervals

The mean time (days) from injury to treatment was 12 days (SD = 4.29; range = 6 – 18) and from injury to infection of the fracture site was nine days (SD = 3.5; range = 4 – 15).

| <b>Patient no.</b> | <b>Tissue space involved</b> |
|--------------------|------------------------------|
| 5                  | Subperiosteal                |
| 7                  | Subperiosteal                |
| 13                 | Buccal                       |
| 14                 | Submandibular                |
| 16                 | Buccal                       |

Table 4: Five cases presenting with persistent infection and the tissue space involved

#### 6.2.4 Cultured organism and sensitivity

| Patient no | Microscopy                   | Organism isolated                  | Antimicrobial susceptibility  |
|------------|------------------------------|------------------------------------|---|
| 1          | Neutrophils, cocci+ bacilli- | Oral flora                         | -   |
| 2          | Neutrophils                  | Skin flora                         | -   |
| 3          | Neutrophils                  | Oral flora                         | -   |
| 4          | Neutrophils, cocci+ bacilli- | Oral flora                         | -   |
| 5          | Neutrophils                  | Oral flora                         | -   |
| 6          | Neutrophils, cocci+ bacilli- | Oral flora                         | -   |
| 7          | Neutrophils                  | Oral flora                         | -   |
| 8          | Neutrophils                  | Oral flora                         | -   |
| 9          | Neutrophils cocci+ bacilli-  | Oral flora                         | -   |
| 10         | Cocci+ bacilli+ bacilli-     | Strep anginosus                    | Penicillin/clindamycin/erythromycin                                       |
| 11         | Neutrophils                  | No bacteria                        | -   |
| 12         | Neutrophil                   | No bacteria                        | -   |
| 13         | Neutrophils cocci+ bacilli-  | Strep parasanguinis                | Penicillin  |
| 14         | Neutrophils cocci+ bacilli-  | Strep constellatus<br>Enterobacter | Ampicillin /clindamycin<br>Ciprofloxacin/gentamicin Resistant- ampicillin |
| 15         | Neutrophils                  | No bacteria                        | -   |
| 16         | Neutrophils cocci+ bacilli-  | Strep mitis                        | Penicillin/clindamycin/erythromycin                                       |
| 17         | Cocci+ bacilli               | Strep milleri                      | Penicillin/clindamycin/erythromycin                                       |
| 18         | -                            | -                                  | -   |
| 19         | -                            | -                                  | -   |
| 20         | Cocci+ bacilli-              | Strep milleri                      | Clindamycin/erythromycin  |

Table 5: Gram-staining and culture with antimicrobial susceptibility

Eighteen of the twenty cases were registered with two samples lost in transport. Organisms cultured were predominately that of the oral flora. One case cultured skin flora, two cases *streptococcus milleri*, and one case *streptococcus mitis*, *streptococcus parasanguinis* and *streptococcus anginosus* respectively. A case of polymicrobial infection which cultured *Streptococcus constellatus* and *Enterobacter cloacae*.

### 6.2.5 Wound dehiscence

Nine cases (45% of sample) presented with wound dehiscence at T0, three cases (15% of sample) at T1 and one patient (5% of the sample) at T2 respectively.

|               |                   | n  | % of sample presenting with wound dehiscence |
|---------------|-------------------|----|--|
| Time interval | <i>Pre-Op</i>     | 20 |  |
|               | <i>Post-Op T0</i> | 9  | 45%  |
|               | <i>Post-Op T1</i> | 3  | 15%  |
|               | <i>Post-Op T2</i> | 1  | 5%   |

Table 6: Presence of wound dehiscence at different time intervals

### 6.2.6 Fracture stability

Nineteen (95%) of the twenty participants exhibited adequate stability at T0 (one week), T1 (six weeks) and T2 (three months). One patient required removal of plates due to fixation failure and required rigid fixation at T2 due fracture mobility upon clinical examination by manual manipulation of the fracture.

### 6.2.7 Radiographic assessment

All fractures treated were successfully anatomically reduced (100%). In the assessment of healing at three months (T2), 19 of the 20 cases treated showed positive signs of bone healing radiographically. One patient exhibited signs of non-union with an ill-define radiolucency at the margins of the fracture which correlated clinically with mobility of the fracture.

## 7. DISCUSSION

### 7.1 Introduction

The evolution in the management of infected mandible fractures has dramatically changed from long periods of immobilization with intermaxillary fixation to open reduction internal fixation with load bearing rigid fixation (Ellis 2003). Current literature supporting the use of load bearing fixation in infected fractures, theorized that by eliminating the movement of the fracture, a stable environment is created, thus, allowing the body's defence to not only eliminate the infection but also transform the infected site into a healing one (Alpert 2008, Koury *et al.* 1992)

### 7.2 Age and Gender

In this study, 20 patients (17 males and 3 females) presented with 32 mandible fractures of which 20 were infected mandible fractures. This compares to Alpert *et al.* (2008) who treated 21 infected mandible fractures in 19 patients and Johansson *et al.* (1988) who treated 37 patients with infected mandible fractures of which 29 were males and eight were female.

From the 20 patients in this study, only eight received prophylactic antibiotics from their referring practitioners. The time lapsed from date of injury to the development of infection was nine days with patients seeking treatment on average four days after the development of infection. In comparison, Koury *et al.* (1992) noted a mean time of 15 days from injury to the development of an infection.

The angle of the mandible was the most common site presenting with an infection. These findings concur with the findings of Koury *et al.* (1992), suggesting that the angle and the body are commonly associated with a higher risk of developing an infection. The present study showed that there might be an association between the development of an infection and a delay in treatment.

### 7.3 Infection and antibiotic therapy

Fascial spaces commonly involved in the current study included the buccal (45%), submental (30%), submandibular (10%) and sublingual spaces (5%). The fascial spaces involved corresponded to the anatomic sites of fracture presented. Infections originating from the angle and the body of the mandible drained into buccal and submandibular fascial spaces and required an extra-oral incision for drainage. Infected fractures of the symphysis presented with submental fascial space infections. Koury *et al.* (1992) noted a higher prevalence of posterior mandible fractures associated with submandibular fascial space involvement and which required extensive incision and drainage.

In the current study, microscopy revealed mixed polymicrobial infections, of which the oral flora predominated. There were six cases which cultured atypical organisms of which five were sensitive to penicillin. In contrast, one case cultured positive for *Enterobacter cloacae* which was resistant to penicillin and cephalosporins, with sensitivity to gentamicin. In this case, the antimicrobial therapy was changed with patient experiencing no further complications.

In comparison, in a study involving forty-four cases treated at Boston University Medical Centre, Mehra *et al.* (2009) noted a mixed polymicrobial of which *alpha* and *beta*-haemolytic *streptococcus* were isolated. Methicillin-resistant *staphylococcus aureus* was isolated in three cases which were treated with vancomycin (Mehra *et al.* 2009).

### 7.4 Fixation method

In terms of fixating an infected fracture, it is recommended that a form of rigid fixation be utilized abiding to the rules of load bearing fixation. As described by Mehra *et al.* (2009), a single-stage protocol with rigid internal fixation can be effectively utilized in treating infected mandible fractures. In the current study, two miniplates fixation method (Cienfuegos *et al.* 2003), was employed providing load-sharing fixation.

Fixation failure was noted in two patients (10%). In the first patient, the superior miniplate was removed due to mobile screws adjacent to the fracture. In the second patient, both miniplates exhibited mobility and required removal. In a similar study conducted by Johansson *et al.* (1988) nine patients (24.3%) exhibited delayed healing in which three required plate removal. In a study by Mehra *et al.* (2009) where 44 patients were treated with load bearing noncompression reconstruction plates, a success rate of 95% was found.

### **7.5 Factors influencing prognosis**

The prognostic outcomes were based on absence of clinical signs of infection, the absence of wound dehiscence, the stability of the fracture and the radiographic evidence of osseous union.

Of the 20 patients treated in the present study, five patients (25%) presented with ongoing sepsis, i.e., presence of purulent discharge at the fracture site, at the first week of recall. The complication rate incurred was significantly higher to that of Alpert *et al.* (2008) who noted failure in treatment in one of the twenty-one patients (4.8%) treated. The patient was immunocompromised and continued to drain pus, with subsequent loss of the graft and fixation which required an additional procedure.

Patients in the study who presented with ongoing infection were treated with repeat incision and drainage. Of these five patients, two patients (10%) required surgery for removal of the hardware. In the first patient, the reason for ongoing sepsis was attributed to fixation failure and mobility of the superior plate. The superior fixation miniplate was removed with the inferior miniplate exhibiting adequate fixation stability. The second patient was lost to follow-up and presented on day 28 with infection secondary to plate mobility. There was good clinical bony union and a satisfactory occlusion. An incision and drainage was done with subsequent resolution at the next follow-up. The third patient initially presented with no complications at the week one follow-up, but at the sixth week follow-up, she presented with local wound sepsis at the operative site. The fixation was stable and infection resolved after incision, drainage and medical management. The fourth patient presented with ongoing sepsis at week one (T0). Following an incision and drainage and a change in antibiotics, the infection resolved and the fixation stable at six week and three-month recall

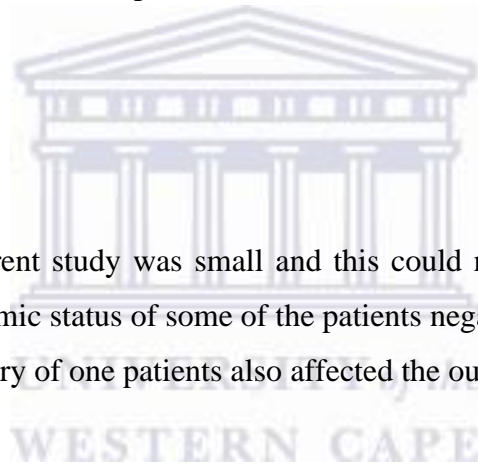


The fifth patient initially presented at week one (T0) with no infection, however at week six (T1), a purulent discharge was noted which was managed via incision, drainage and antibiotic therapy. At the three-month (T2) recall, the patient presented with mobility and infection at the fracture site. History revealed a new event of blunt trauma to the left angle of the mandible on the side of the previously operated site. The previous loose fixation devices were removed and replaced with rigid fixation via a reconstruction plate. Further healing was uncomplicated.

Based on current literature, wound dehiscence prevails as the most common complication in treating infected mandible fractures. A study conducted by Alpert *et al.* (2008) noted four patients (4.8%) who developed minor wound dehiscence intraorally which spontaneously granulated over with wound area. This finding concur with the results of the present study that found that 5% of cases developed minor wound dehiscence at interval T2. Although secondary healing may be attained with satisfactory results, the process occurs over a long period of time that may make the operative site susceptible to bacterial contamination, infection and eventual failure of treatment.

## **7.6 Limitation**

The sample size in the current study was small and this could not give a statistical relevant outcome. Low socio-economic status of some of the patients negatively affected the recall and communication. Repeat injury of one patients also affected the outcome of the study.



## 8. CONCLUSION

With reference to current literature, treatment of infected mandible fractures in an immediate setting, i.e., incisions and drainage with rigid fixation; yields positive results. However, little is made mention of fixation using load sharing double miniplate osteosynthesis.

In the current study, the results do not support the use of double miniplate osteosynthesis in infected mandible fractures. A high complication rate was found and therefore further research involving more cases is suggested to assess the efficacy of load sharing miniplate osteosynthesis in infected mandible fractures.



## 9. REFERENCES

Abdelfadil, E., Salem, A., Samah, I., Al-Belasy, F.A. 2013. Infected mandible fractures: risk factors and management. *J Oral Hyg Health* 1:102-108.

Abubaker, A.O. Rollert, M.K. 2001. Postoperative antibiotic prophylaxis in mandibular fractures: A preliminary randomized, double-blind, and placebo controlled clinical study. *J Oral Maxillofac Surg*, 59:1415-1419.

Alpert, B. 1998. Management of the complications of mandibular fracture treatment. *Operative Techniques in Plastic and Reconstructive Surgery*, 5: 325-333.

Alpert, B., Kushner, G.M., Tiwana, P.S. 2008. Contemporary Management of Infected Mandibular Fractures. *Craniofacial Trauma and Reconstruction*, Nov: 25-29.

Amaldas, V.D. 1990. Cervicofacial infections. A three-year retrospective study. MChD, MFOS thesis. Department of Library and Information Science, University of the Western Cape.

Ban, K.A., Minei, J.P., Laronga, C., Harbrecht, B.G., Jensen, E.H., Fry, D.E., Itani, K.M., Dellinger, E.P., Ko, C.Y., and Duane, T.M. 2016. American College of Surgeons and Surgical Infection Society: Surgical site infection guidelines, 2016 update.

Bataineh, A.B. 1998. Aetiology and incidence of maxillofacial fractures in the north of Jordan. *Oral Surgery, Oral Medicine, Oral Pathology, Oral Radiology, and Endodontics*, 86, 31–35.

Benson. P., Marshall, M., Engelsted, M. 2006. The Use of Immediate Bone Grafting in Reconstruction of Clinically Infected Mandibular Fractures: bone grafts in the presence of pus. *J Oral Maxillofac Surg*, 1:122-126.

Bolourian, R., Lazow, S., Berger, J. 2002. Transoral 2.0-mm miniplate fixation of mandibular fractures plus 2 weeks' maxillomandibular fixation: a prospective study. *J Oral Maxillofac Surg*, 60: 167-170.

Brandies, F.E., Dielert, E. 1984. The infected mandible fracture. *Arch Orthop Trauma Surg*, 103: 337-441.

Cahill, T., Gandhi, R., Allori, A.C., Alexander, C.M., Jeffrey, R., Davids, P., Detlev, E, and Howard, L. 2015. Hardware Removal in Craniomaxillofacial Trauma. A Systematic Review of the Literature and Management Algorithm. *Ann Plast Surg*, 75: 572-578.

Champy, M., Lodde, J.P., Schmitt, R., Jaeger, J.H., and Muster, D. 1978. Mandibular osteosynthesis by miniature screwed plate via a buccal approach. *J. Maxfac Surg*, 6: 14-21.

Chritah, A., Lazow, S.K., Berger, J.R. 2005. Transoral 2.0-mm locking miniplate fixation of mandibular fractures plus 1 week of maxillomandibular fixation: a prospective study. *J Oral Maxillofac Surg*, 63: 1737-1741.

Chen, X., Tsukayama, D.T., Kidder, L.S., Bourgeault, C.A., Schmidt, A.H., and Lew, W.D. 2005. Characterization of a chronic infection in an internally stabilized segmental defect in the rat femur. *J Orthopaedic Research*, 23: 816-823.

Cienfuegos, R., Cornelius, C., Ellis, E., Kushner, G. AO Foundation – official site, AOCMF. <https://www.aofoundation.org>

Cornelius, C.P., Audige, L., Kunz, C., Rudderman, R., Buitrago-Tellez, C.H., Frodel, J., and Prein, J. 2014. The Comprehensive Classification System: Mandible fractures Level 3 Tutorial. *Craniomaxillofacial Trauma and Reconstruction* 7: s 31- 43.

Danda, A.K. 2010. Comparison of a single noncompression miniplate versus 2 noncompression miniplates in the treatment of mandibular angle fractures: a prospective, randomized clinical trial. *J Oral Maxillofac Surg*, 68: 1565- 1567.

Davis, B.J., Roberts, P.J., Moorcroft, C.I., Brown, M.F., Thomas, P.M., and Wade, R.H. 2004. “Reliability of radiographs in defining union of internally fixed fractures,” *Injury*, 35: 557–561.

Dingman, R., Natvig, P. 1969. Surgery official fractures. Saunders Company, USA. P. 142-144.

Ellis, E., Moos, K.F., El Attar, A. 1985. "Ten years of mandibular fractures: an analysis of 2,137 cases." *Oral Surgery Oral Medicine and Oral Pathology*, 59: 120–129.

Ellis, E. 3<sup>rd</sup>, Muniz, O., Anand, K. 2003. Treatment considerations for comminuted mandibular fractures. *J Oral Maxillofac Surg*, 61: 861-870.

Fox, A.J., Kellman, R.M. 2003 Mandibular angle fractures: two-miniplate fixation and complications. *Arch Facial Plast Surg*, 5: 464-469.

Garner, J.S. 1986. CDC Guideline for prevention of surgical wound infection, 1985 superseded guideline for prevention of surgical wound infections published in 1982. *Infect Control*, 3: 193-200.

Ghanem, W.A., Elhayes, K.A., Saad, K. 2011. The management of unstable oblique mandibular fractures with a 2.3mm mandibular osteosynthesis reconstruction bone plate. *J Craniomaxillofac Surg*, 39: 600-605.

Johansson, B., Andersson, L., Kerekmanov, L. 1983. Bone –apposition, bone resorption and post-operative infection in connection with metal plate-method of fixation of mandibular fractures, a follow-up study. *Int J Oral Surg*, 4: 163-173.

Johansson, B., Krekmanov, L., Thomsson, M. 1988. Miniplate Osteosynthesis of Infected Mandible Fracture. *J Cranio-maxfacial Surg*, 16: 22-27.

Karnes, J.M., Daffner, D.F., Watkins, C.M. 2015. Multiple roles of tumour necrosis factor-alpha in fracture healing. *J Bone*, 58: 87-93.

Kawai, T., Murakami, S., Hiranuma, H., and Sakuda, M. 1997. Radiographic changes during bone healing after mandibular fractures. *Br J Oral Surg*, 35(5), 312–318.

Koury, M., Ellis, E. 1992. Rigid internal fixation for the treatment of infected mandibular fractures. *J Oral Maxillofac Surg*, 50: 434–443.

Koury, E., Perrott, H., Kaban, B. 1994. The use of rigid internal fixation in mandible fractures complicated by osteomyelitis. *J Oral Maxillofac Surg*, 52: 1114-1119.

Langford, R.J., Frame, J.W. 2002. Tissue changes adjacent to titanium plates in patients. *J Craniomaxillofac Surg*, 30: 103-107.

Laskin, D. 2003. The use of prophylactic antibiotics for the prevention of postoperative infection. *Oral Maxillofac Surg Clin N America*, 15: 155-160.

Iizuka, T., Lindqvist, C., Hallikainen, D., and Paukku, P. 1991. Infection after rigid internal fixation of mandibular fractures: a clinical and radiographic study. *J Oral Maxillofac Surg*, 49: 585-593.

Loi, F., Córdova, L.A., Pajarinen, J., Lin, T.H., Yao, Z., and Goodman, S. 2016. Inflammation, fracture and bone repair. *J Bone*, 86: 119-130.

Lygidakis, T.N., Eliades, I.G., Papanikolaou, S. 2007. A retrieval study on morphological and chemical changes of titanium osteosynthesis plates and adjacent tissues. *J Craniomaxillofac Surg*, 35: 168-176.

Maloney, P.L., Lincoln, R.E., Coyne, C. P. 2001. A protocol for the management of compound mandibular fractures based on the time from injury to treatment. *J Oral Maxillofac Surg*, 59: 879–884.

Malanchuk, V.O., Kopchak, A.V. 2007. Risk factors for development of infection in patients with mandibular fractures located in the tooth-bearing area. *J Craniomaxillofac Surg*, 35: 57-62.

Marsh, D.R., Li, G. 1999. The biology of fracture healing: optimising outcome. *Br Med Bull*, 55: 856-869.

Mogajane, B.M., Mabongo, M. 2018. Epidemiology of maxillofacial fractures at two maxillofacial units in South Africa *SADJ April*, vol 32, 132 -136.

Morshed, S., Corrales, L., Genant, H., and Miclau, T. 2008. "Outcome assessment in clinical trials of fracture-healing," *J Bone and Joint Surg*, vol. 90, pp. 62–67.

Morshad. 2014. Current Options for Determining Fracture Union. *Adv Med*, vol. 14, pp 1-12.

Marx, R.E. 2004. Platelet-rich plasma: evidence to support its use. *J Oral Maxillofac Surg*, 62: 489-96.

Mdlalose, L. 2015. Immediate versus Delayed Surgical Management of Septic Mandible Fracture. MChD. MFOS thesis. Department of Library and Information Science, University of the Western Cape.

Mehra, P., Van Heukelom, E., Cottrell, D.A. 2009. Rigid Internal Fixation of Infected Mandibular Fractures. *J Oral Maxillofac Surg*, 67: 1046-1051.

Moreno, J.C., Fernández, A., Ortiz, J.A., and Montalvo, J.J. 2000. Complication rates associated with different treatments for mandibular fractures. *J Oral Maxillofac Surg*, 58: 273-280.

Natu, S., Gupta, S., Shankar, R., Gupta, H., Alam, S., Kohli, M., and Agarwal, A. 2012. An Epidemiological Study on Pattern and Incidence of Mandibular Fractures. *Plastic Surgery International* Volume 2012, Article ID 834364.

Oliver, S. 2013. Western Cape Academic Hospitals Antimicrobial Recommendation. National Health Laboratory Service (NHLS).

Politis, C., Schoenaers, J., Jacobs, R., and Agbaje, J.O. 2016. Wound Healing Problems in the Mouth. *Front Physiol*, 7: 507.

Prein, J., Ehrenfeld, M., and Manson, P. 2012. Principles of Internal Fixation of the Craniomaxillofacial Skeleton – Trauma and Orthognathic Surgery. Thieme.

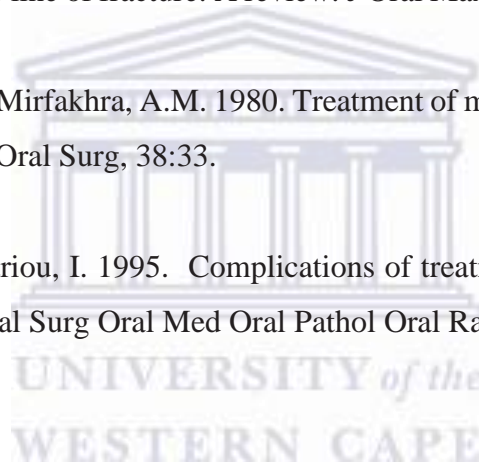Rittmann, W.W., Perren, S.M. 1974. Cortical Bone Healing after Internal Fixation and Infection. New York, NY, Springer Verlag.

Sarvan, I. 2009. Orofacial sepsis and HIV at the Maxillofacial Surgery unit in the Western Cape. MChD. MFOS thesis. Department of Library and Information Science, University of the Western Cape.

Shetty, V. 1989. Teeth in the line of fracture: A review. *J Oral Maxillofac Surg*; 47: 1303-1306.

Souyris, F., Lamarche, J.P., Mirfakhra, A.M. 1980. Treatment of mandible fractures by intraoral placement of bone plates. *J Oral Surg*, 38:33.

Zachariades, N., Papademetriou, I. 1995. Complications of treatment of mandibular fractures with compression plates. *Oral Surg Oral Med Oral Pathol Oral Radiol Endod*, 79: 150-153.





## Appendix 1: Consent Form



UNIVERSITY of the  
WESTERN CAPE  
Department of Maxillofacial and Oral Surgery  
Faculty of Dentistry and WHO Oral Health Collaborating Centre  
University of the Western Cape  
Cape Town

I, Mr/Mrs/Miss .....

Date of Birth: ..... Hospital File No: .....

|         |
|---------|
| STICKER |
|---------|

I am **willing** to participate in the study as described to me by Dr Zain Dangor. I understand the participation is voluntary. I have been adequately informed about the objectives of the study and the complications. I do know that I have the right to withdraw from the study at any stage, which will not prejudice me in any way regarding further treatment. My rights will be protected and all my details be kept confidential

The study is approved by the Bio-medical and Research and Ethics Committee of the University of the Western Cape.

I, hereby give consent to be part of the research/study

Patient's name or guardian name: .....

Patient's or guardian signature: .....

Witness:

.....

## Appendix 2: Patient Information Letter

### Patient Information



UNIVERSITY of the  
WESTERN CAPE

Department of Maxillofacial and Oral Surgery  
Faculty of Dentistry and WHO Oral Health Collaborating Centre  
University of the Western Cape  
Cape Town

I, Dr Zain Dangor, currently enrolled as a residence in the field of Maxillofacial and Oral Surgery; plan to conduct a prospective clinical study in determining efficacy of double miniplate osteosynthesis in the immediate management of infected mandible fractures.

All patients will undergo clinical examination, special investigations, which include radiographic examination, blood testing and pus swab testing; and an operation. The operation will include incision and drainage of the infection, extraction of teeth and plating of the fractures using a double miniplate fixation method. You may withdraw from the study at any time. Participating in the study will definitely benefit you and future patients. Participating in the study or refusing the participation will not harm or prejudice you in any way.

Thank you for your participation

Dr Zain Dangor (Researcher)

Registrar (Maxillofacial and oral Surgery)

Department of Maxillofacial- and Oral Surgery

Faculty of Dentistry

University of the Western Cape

Cape Town

I, (patient's name) ..... Fully understand the information  
supplied to me by Dr Zain Dangor.

Signature: ..... Date: .....

### Appendix 3: Data Capturing Sheet - Preoperative Assessment

| Patient no | gender | Age | Race | MH | A/B | Unilateral / Bilateral | Body / Angle | Tooth Inline fracture | Time from injury to dev. infection | Time for injury to treatment | Facial space involvement | MCS |
|------------|--------|-----|------|----|-----|------------------------|--------------|-----------------------|------------------------------------|------------------------------|--------------------------|-----|
|            |        |     |      |    |     |                        |              |                       |                                    |                              |                          |     |
|            |        |     |      |    |     |                        |              |                       |                                    |                              |                          |     |
|            |        |     |      |    |     |                        |              |                       |                                    |                              |                          |     |
|            |        |     |      |    |     |                        |              |                       |                                    |                              |                          |     |
|            |        |     |      |    |     |                        |              |                       |                                    |                              |                          |     |
|            |        |     |      |    |     |                        |              |                       |                                    |                              |                          |     |
|            |        |     |      |    |     |                        |              |                       |                                    |                              |                          |     |
|            |        |     |      |    |     |                        |              |                       |                                    |                              |                          |     |

### Outcomes

#### Pain score

| Patient no | Day 1 | Day 2 | Day 3 | Day 4 | Day 5 | T1 (6 weeks) | T2 (3 months) |
|------------|-------|-------|-------|-------|-------|--------------|---------------|
|            |       |       |       |       |       |              |               |
|            |       |       |       |       |       |              |               |

#### Post-operative infection

| Patient no | T 0 (post-operative) | T1 (6 weeks post-op) | T2 ( 3 months post-op) |
|------------|----------------------|----------------------|------------------------|
|            |                      |                      |                        |
|            |                      |                      |                        |

**Post-operative wound dehiscence**

| <b>Patient no</b> | <b>T 0 (post-operative)</b> | <b>T1 (6 weeks post-op)</b> | <b>T2 ( 3 months post-op)</b> |
|-------------------|-----------------------------|-----------------------------|-------------------------------|
|                   |                             |                             |                               |
|                   |                             |                             |                               |

**Fracture Stability**

| <b>Patient no</b> | <b>T 0 (post-operative)</b> | <b>T1 (6 weeks post-op)</b> | <b>T2 ( 3 months post-op)</b> |
|-------------------|-----------------------------|-----------------------------|-------------------------------|
|                   |                             |                             |                               |
|                   |                             |                             |                               |





## Appendix 5: BMREC Approval Form

 **OFFICE OF THE DIRECTOR: RESEARCH  
RESEARCH AND INNOVATION DIVISION**

Private Bag X17, Bellville 7535  
South Africa  
T: +27 21 959 4111/2948  
F: +27 21 959 3170  
E: [research-ethics@uwc.ac.za](mailto:research-ethics@uwc.ac.za)  
[www.uwc.ac.za](http://www.uwc.ac.za)

10 July 2018

Dr Z Dangor  
Faculty of Dentistry

**Ethics Reference Number:** BM18/5/26

**Project Title:** Outcomes of double mini plate osteosynthesis in the immediate management of infected mandible fractures

**Approval Period:** 09 July 2018 - 09 July 2019

I hereby certify that the Biomedical Science Research Ethics Committee of the University of the Western Cape approved the scientific methodology and ethics of the above mentioned research project.

Any amendments, extension or other modifications to the protocol must be submitted to the Ethics Committee for approval.


**Please remember to submit a progress report in good time for annual renewal.**

The Committee must be informed of any serious adverse event and/or termination of the study.



*Ms Patricia Josias  
Research Ethics Committee Officer  
University of the Western Cape*

## Appendix 6: Permission letter from GSH Research Committee



Western Cape  
Government  
Health



### GROOTE SCHUUR HOSPITAL

Engelies: Dr Bernadette Eick  
E-mail : [Bernadette.Eick@westerncape.gov.za](mailto:Bernadette.Eick@westerncape.gov.za)

Dr Zain Dangor  
UWC - FACULTY OF DENTISTRY

E-mail: [zaindangor@uwc.ac.za](mailto:zaindangor@uwc.ac.za)

Dear Dr Dangor,

**RESEARCH PROJECT: Outcomes Of Double Mini Plate Osteosynthesis In The Immediate Management Of Infected Mandible Fractures**

Your recent letter to the hospital refers.

You are granted permission to proceed with your research, which is valid until 9 July 2019.

Please note the following:

- a) Your research may not interfere with normal patient care.
- b) Hospital staff may not be asked to assist with the research.
- c) No additional costs to the hospital should be incurred i.e. Lab, consumables or stationary.
- d) **No patient folders may be removed from the premises or be inaccessible.**
- e) Please provide the research assistant/field worker with a copy of this letter as verification of approval.
- f) Confidentiality must be maintained at all times.
- g) Should you at any time require photographs of your subjects, please obtain the necessary indemnity forms from our Public Relations Office (E45 OMS or ext. 2187/2188).
- h) Should you require additional research time beyond the stipulated expiry date, please apply for an extension.
- i) Please discuss the study with the HOD before commencing.
- j) Please introduce yourself to the person in charge of an area before commencing.
- k) On completion of your research, please forward any recommendations/findings that can be beneficial to use to take further action that may inform redevelopment of future policy / review guidelines.
- l) **Kindly submit a copy of the publication or report to this office on completion of the research.**

I would like to wish you every success with the project.

Yours sincerely

**DR BERNADETTE EICK**  
**CHIEF OPERATIONAL OFFICER**  
Date: 10 September 2018

C.C. M.L. Naideo  
Dr B. Jacobs  
Ms. W. Bryant

G46 Management Suite, Old Main Building,  
Observatory 7925  
Tel +27 21 404 6268 Fax +27 21 404 6125

Private Bag X,  
Observatory, 7935  
[www.capegateway.gov.za](http://www.capegateway.gov.za)



<http://etd.uwc.ac.za/>