



**UNIVERSITY** *of the*  
**WESTERN CAPE**

**The accuracy of the mental foramen position on panoramic radiographs and CBCT**



**K.R BESHTAWI**

**SUPERVISOR: PROFESSOR M.E. PARKER**

**CO-SUPERVISOR: DR.EMAD QIRRESH**

“Submitted in partial fulfilment of the requirements for the degree M.Sc. Maxillofacial Radiology in the Department of Diagnostics and Radiology, Faculty of Dentistry, University of the Western Cape”

## ABSTRACT

**Aim:** To compare the linear measurements obtained from digital panoramic radiographs and CBCT views for the determination of the mental foramen position.

**Material and methods:** Data was analysed from 31 archived cone-beam computed tomography (CBCT) images and Digital panoramic radiographs (DP) for the same patients taken on the same x-ray machine (Carestream® CS9000 3D). The position and demarcations of mental foramen were identified and then compared by means of linear measurements performed using the manufacturer provided software. Distances measured for the mental foramen in CBCT reformatted panoramic views (CRP) and digital panoramic radiographs (DP) were obtained and compared for both the vertical and horizontal positions. CBCT oblique coronal views (CORO) were studied for the vertical position of the mental foramen and compared to those obtained from CRP and DP for the same distance.

**Results:** The study showed that there was a difference in measurements between CRP and DP views of the tested distances (X1, X2, MH, MW, and Y1). All the *p*-values for the studied distances (X1, X2, MH, MW) indicated statistical significance (*p*-value < 0.05). The *p*-values of X1, X2, MH, MW were 0.0412, 0.0023, 0.0018, and 0.0456, respectively. The statistical analysis of the vertical distance Y1 obtained from the three views (DP, CRP, and CORO) showed statistically significant differences in the mean distance over the three different techniques (*p*<0.000) and the greatest mean difference of 1.59mm (*p*<0.05) was obtained for Y1 (DP-CORO). The inter-examiner and intra-examiner agreements were analysed using Intra-class correlation coefficient (ICC). The inter-examiner analysis indicated “excellent” agreements in all the variables studied while the intra-examiner analysis indicated “excellent” and “good” agreements.

**Conclusion:** Although there were differences between the digital and CBCT reformatted panoramic views in terms of horizontal and vertical linear measurements, the mean of differences may be clinically acceptable. However, clinically significant measurement discrepancies were found between the panoramic views (DP, CRP) when compared to the coronal views with regards to the vertical position of the mental foramen. Clinical application of the coronal view measurements may therefore reduce the risk of neurovascular injury .

## DECLARATION

I declare that “**The accuracy of the mental foramen position on panoramic radiographs and CBCT**” is my own work, that it has not been submitted before for any degree or examination in any other university, and that all the sources I have used or quoted have been indicated and acknowledged as complete references.

Khaled Beshtawi: .....

August 2017: .....

## ACKNOWLEDGEMENTS

I would like to express my sincere thanks and appreciation to the following people for their respective contributions during this study:

- My supervisor, Professor Mohammed Ebrahim Parker for his insightful guidance and unwavering support.
- My co-supervisor Dr. Emad Qirresh for his assistance and constructive criticism.
- Professor Barrie and Professor Neil Myburgh, Department of Community Dentistry (Faculty of Dentistry of the University of the Western Cape).
- Dr. Ayman Duzdar, for all his assistance.
- Dr. Faheema Kimmie-Dhansay, for her generous assistance.
- Prof C.J. Nortje, Ms J. Botha and Ms M. Coetzee.
- A special thank you to the staff of the Department of Oral and Maxillofacial Radiology. Thank you to Ms. K. Crombie and all the staff at Mitchell's Plain, Mrs J. Palmer and all the staff at Tygerberg hospital, my colleague Dr. F. Opondo.
- To my beloved 'second' family in South Africa, Ahmad and Nathirah Jardien.
- To my beloved friends in South Africa and Palestine.
- To Dr. Shoayeb Shaik for his support and advise over the last few years.

## **DEDICATION**

*This thesis is dedicated to:*

*To my beloved family: My father, My mother, My brother, My grandmother, uncles and aunties.*

*My Countrymen - the people of Palestine*

*My people that I watched and empathized with from afar. This is for you!*

## TABLE OF CONTENT

ABSTRACT.....	II
DECLARATION .....	III
ACKNOWLEDGEMENTS .....	IV
DEDICATION .....	V
LIST OF TABLES .....	IX
LIST OF FIGURES .....	IX
LIST OF CHARTS .....	XI
LIST OF ABBREVIATIONS AND ACRONYMS.....	XII
KEYWORDS.....	XIII
CHAPTER 1 : INTRODUCTION .....	1
CHAPTER 2 : LITERATURE REVIEW .....	3
2.1 Panoramic radiography role in practice .....	3
2.2 Anatomical overview of the mental foramen.....	4
2.3 Mental foramen position .....	4
2.4 Mental foramen size.....	5
2.5 Mental foramen shape.....	6
2.6 Accessory mental foramen (AMF) incidence and position.....	6
2.7 CBCT accuracy in linear measurements .....	7
2.7.1 Overview .....	7
2.7.2 CBCT reformatted panoramic view:.....	8
2.8 Panoramic radiographs linear measurements accuracy.....	9
2.9 Conclusion .....	11
CHAPTER 3 : AIMS AND OBJECTIVES .....	12
3.1 Aim: .....	12
3.2 Objectives: .....	12
CHAPTER 4 : MATERIALS AND METHODS .....	13
4.1 Study design.....	13
4.2 Instruments and machines.....	13
4.3 Target Population.....	14
4.4 Sample selection process and size: .....	14

4.5 Inclusion criteria: .....	14
4.6 Exclusion Criteria: .....	14
4.7 Data analysis: .....	15
4.8 The proposed methodology.....	15
4.8.1 Conditions of measurements .....	15
4.8.2 Measurements methodology .....	16
4.8.3 Choosing reference points.....	16
4.8.4 Mental foramen demarcation and measurements process.....	18
4.8.5 Measurements on the digital panoramic radiograph (DP) .....	18
4.8.6 Measurements on the CBCT views.....	19
4.9 Ethical Consideration.....	20
4.10 Budget.....	20
4.11 Example of measurements carried out .....	20
CHAPTER 5 : RESULTS .....	26
5.1 Results Overview: .....	26
5.2 Statistical analysis of the results: .....	27
5.2.1 Observations deleted due to outliers .....	28
5.2.2 Statistical analysis of variable X1:.....	30
5.2.3 Statistical analysis of variable X2:.....	30
5.2.4 Statistical analysis of variable MH: .....	31
5.2.5 Statistical analysis of variable MW: .....	32
5.2.6 Statistical analysis of the vertical distance Y1 .....	32
5.3 General interpretation of the values: .....	35
5.3.1 Maximum and Minimum values:.....	35
5.3.2 Ranges of differences calculated: .....	36
5.3.3 Comparison between the variables difference values: .....	37
5.4 Inter-observer agreement analysis .....	38
5.5 Intra-observer agreement analysis .....	40
CHAPTER 6 : DISCUSSION.....	42
6.1 Results discussion:.....	42
6.2 Effects of anatomical variations of the mental foramen on the linear measurements.....	45
6.3 The effect of the vertical slope of mental canal on the MF's radiographic presentation .....	53

6.4 The effects of the horizontal mental canal directions on the MF’s radiographic presentation ...	57
6.5 The effects of the bone marrow variability on the identification of MF on panoramic radiographs.....	58
6.6 Limitations .....	61
CHAPTER 7 : CONCLUSION AND RECOMMENDATIONS .....	62
7.1 Conclusion .....	62
7.2 Recommendations.....	62
REFERENCES .....	63
APPENDICES .....	68
APPENDIX 01: DATA COLLECTION SHEET .....	68
Appendix 02: LETTER OF REQUEST FOR ACCESS TO THE PATIENTS FILES .....	69
Appendix 03: AUTHORIZATION LETTER THE RADIOLOGY CENTER TO ACCESS THEIR DATABASE .....	70
Appendix 04: ETHICAL APPROVAL AND PROJECT REGISTRATION LETTER .....	71



## LIST OF TABLES

Table 4.1. The variables (distances) studied on the radiographic views.....	17
Table 4.2. The values obtained from the measured variables (distances).....	20
Table 5.1. Deleted observations.....	28
Table 5.2. Summary statistics of X1, X2, Mental Height, Mental Width, and Y1 values .....	29
Table 5.3. Summary statistics X1, X2, Mental Height, Mental Width, and Y1 difference values .....	29
Table 5.4. Paired T-test results for the difference in means of X1DP1 and X1CRP1 .....	30
Table 5.5. Paired T-test results for the difference in means of X2DP1 and X2CRP1 .....	31
Table 5.6. Paired T-test results for the difference in means of MHDP1 and MHCRP1 .....	31
Table 5.7. Paired T-test results for the difference in means of MWP1 and MWCBC1 .....	32
Table 5.8. Summary statistics of Y1 values obtained from DP, CRP, and CORO views.....	32
Table 5.9. Maximum and Minimum of variables (measurements) difference values.....	35
Table 5.10. Ranges of variables (distances) difference.....	36
Table 5.11. Numbers of patients showed (more or less) values compared between DP, CRP, and CORO views .....	37
Table 5.12. Intra-class correlation coefficient and level of agreement for inter-observers.....	38
Table 5.13. Intra-class correlation coefficient and level of agreement for intra-observers.....	40

## LIST OF FIGURES

Figure 4.1. Measurement methods.....	17
Figure 4.2. Panoramic view shows measuring Y1 from a standard point vs. any point from the tangent .....	19
Figure 4.3. Digital panoramic view (DP), shows the measurement of X1 (14.8mm).....	21
Figure 4.4. Digital panoramic view (DP), shows the measurement of X2 (4.7 mm).....	21
Figure 4.5. Digital panoramic view (DP), shows the measurement of MW (2.5mm) .....	22
Figure 4.6. Digital panoramic view (DP), shows the measurement of Y1 (13.5mm).....	22
Figure 4.7. Digital panoramic view (DP), shows the measurement of MH (2.6 mm) .....	23
Figure 4.8. CBCT reformatted panorama (CRP), shows the measurements of X1, X2, MW (17.2mm, 3.0mm, 2.8mm, respectively).....	23
Figure 4.9. CBCT reformatted Panorama (CRP), shows the measurement of Y1 (13.5mm) .....	24
Figure 4.10. CBCT reformatted panorama (CRP), shows the measurements of MH (2.7mm) .....	24
Figure 4.11. CBCT coronal view (CORO), shows the measurements of Y1 (13.0mm).....	25

Figure 5.1. Part of the ANOVA tests carried out for the analysis of Y1 of three different radiographic views. .... 33

Figure 6.1.(A), an oblique coronal view (CORO), the horizontal plane crosshair (yellow line) was set at the lower border of the mental canal opening, the correspondent CRP view (Figure B) in contrast was pointed at the upper border of the identified MF in the same view. .... 48

Figure 6.2.(A), CRP view; the coronal plane crosshair (Blue vertical line) was set at the mesial border of the mental foramen; the axial crosshair (Yellow horizontal line) was roughly set at the middle of MF. (B), the corresponding CBCT axial view; as seen at this axial slice, there was no evidence of any opening on the outer mandibular cortex compared with the CRP view at the same horizontal level... 48

Figure 6.3. (A) CRP view; the vertical crosshair (blue line) was set at the mesial border of the MF. (B) The correspondent axial view, as shown there was no evidence of any opening on the outer mandibular cortex at these vertical and horizontal levels. (C) CRP view, the vertical crosshair (blue line) was set at the distal border of the MF; the correspondent axial view (D) also did not show any evidence of any opening on the outer mandibular cortex. .... 49

Figure 6.4.CBCT axial view (The horizontal axial level was selected at a point higher than the MF's upper border seen on CRP view). This bony inclusion seen in the axial view represented the actual opening of the MF (please note the corresponding coronal view in the same figure). .... 49

Figure 6.5. (A) DP view, (B) CRP view. Both views demonstrate the identified mental foramen (blue solid arrow); the MF is clearly visible and well-demarcated. .... 51

Figure 6.6. (A) An oblique coronal view; the horizontal crosshair (Yellow line) was set at the lower edge of the mental canal opening. (B) The corresponding CRP view shows the horizontal crosshair situated at a higher level from the upper margin of the MF visible on the same view. .... 51

Figure 6.7.Y1 measurements were carried out in DP view (A), CRP view (B), and CORO view (C). Y1DP1=16.7 mm, Y1CRP1=16.4mm, Y1CORO1=11.4mm. .... 52

Figure 6.8. (A) Axial view; AMF was visible and opens far distally from the main MF. (B) The correspondent CRP view shows the crosshair pointed far distally to the main MF seen on the same view..... 52

Figure 6.9. (A) A DP view shows measurements of Y1. (B) A CRP view shows the calculation of Y1 value. (C) The correspondent oblique coronal view for the same Y1 slice level measured on CRP view..... 54

Figure 6.10. (A) A DP view shows measurements of Y1. (B) A CRP view shows the calculation of Y1 value. (C) The correspondent oblique coronal view for the same Y1 slice level measured on CRP view..... 55

Figure 6.11. (A) A DP view shows measurements of Y1. (B) A CRP view shows the calculation of Y1 value. (C) The correspondent oblique coronal view for the same Y1 slice level measured on CRP view..... 56

Figure 6.12. (A) A CBCT axial view; the crosshair was set at the distal end of MF in the horizontal plane (Blue line). (B) The correspondent CRP view shows the crosshair situated at a farther distance distally from the MF identified on the same view. .... 57

Figure 6.13. (A) DP view shows the mental foramen with well corticated and defined margins and with no evidence of AMF. (B) CRP view represents the MF with an extended mental foramen upper margin compared to that seen on DP view; also shows a small radiolucency distal to the main MF

(AMF). (C & D), ML calculations on DP, CRP views (2mm, 3.5mm, respectively). (E) An axial slice shows clearly the AMF distal to the main foramen. .... 59

Figure 6.14. (A) DP view, shows the mental foramen with well-defined margins. (B) CRP view shows the shadow of the mental loop much clearly; there was no evidence that the previously identified MF on the DP view was evident on this view. (C) An oblique coronal view (the slice was selected in the middle of the foramen on identified on the CRP); this view shows that mental canal was ascending and overlying the tooth's #35 root tip (about 4mm). .... 60

## LIST OF CHARTS

Chart 5.1. Box plot showing the outliers observations .....	28
Chart 5.2. Maximum and minimum of variables (measurements) difference values .....	35
Chart 5.3. Ranges of differences for each variable studied.....	36
Chart 5.4. Numbers of patients showed (more or less) values compared between DP, CRP, CORO views .....	37
Chart 5.5. Dot plot of inter-observer measurements using digital panorama (DP) and CBCT.....	39
Chart 5.6. Dot plot of inter-observer measurements using digital panorama (DP) and CBCT.....	41

## LIST OF ABBREVIATIONS AND ACRONYMS

	Description
<b>AMF</b>	Accessory mental foramen.
<b>CBCT</b>	Cone beam computed tomography.
<b>CCD</b>	Charge-coupled device.
<b>CI</b>	Confidence interval.
<b>CMOS</b>	Complementary metal-oxide-semiconductor.
<b>CORO</b>	CBCT oblique coronal view.
<b>CRP</b>	CBCT-reformatted panoramic view.
<b>CT</b>	Computed tomography.
<b>DP</b>	Digital panorama.
<b>DT</b>	Distal tangent.
<b>Eq. Al.</b>	Aluminium equivalent
<b>ICC</b>	Intra-class correlation coefficient.
<b>ID</b>	Inferior dental
<b>L1</b>	Distal line (a vertical straight line dropped down from the mid of root apex of a tooth distal to the mental foramen).
<b>L2</b>	Mesial line (a vertical straight line dropped down from the mid of root apex of a tooth mesial to the mental foramen).
<b>MF</b>	Mental foramen.
<b>MH</b>	The internal height of the mental foramen.
<b>MH (DP-CRP)</b>	The difference between MH (DP) and MH (CRP) value
<b>MH 1DP1</b>	The internal height of the mental foramen measured in the DP view.
<b>MHCRP1</b>	The internal height of the mental foramen measured in the CRP view.
<b>MM</b>	Millimetre.
<b>MT</b>	Mesial tangent.
<b>MW</b>	The internal width of the mental foramen.
<b>MW (DP-CRP)</b>	The difference between MW (DP) and MW (CRP) value.
<b>MW 1DP1</b>	The internal width of the mental foramen measured in the DP view.

<b>MWCRP1</b>	The internal width of the mental foramen measured in the CRP view.
<b>PC</b>	Personal computer.
<b>ST</b>	Superior tangent.
<b>X1</b>	The horizontal distance measured from L1 – DT.
<b>X1 (DP-CRP)</b>	The difference between X1(DP) and X1(CRP) value.
<b>X1CRP1</b>	The horizontal distance measured from L1 – DT measured in the CRP view.
<b>X1DP1</b>	The horizontal distance measured from L1 – DT measured in the DP view.
<b>X2</b>	The horizontal distance measured from L2 – MT.
<b>X2 (DP-CRP)</b>	The difference between X2(DP) and X2(CRP) value.
<b>X2CRP1</b>	The horizontal distance measured from L2 - MT measured in the CRP view.
<b>X2DP1</b>	The horizontal distance measured from L2 – MT measured in the DP view.
<b>Y1</b>	The vertical distance measured from ST – superior alveolar ridge.
<b>Y1 (CRP-CORO)</b>	The difference between Y1CRP and Y1CORO value.
<b>Y1 (DP-CORO)</b>	The difference between Y1DP and Y1CORO value.
<b>Y1 (DP-CRP)</b>	The difference between Y1 (DP) and Y1 (CRP) value.
<b>Y1CRP1</b>	The vertical distance measured from ST – superior alveolar ridge measured in the CRP view.
<b>Y1DP1</b>	The vertical distance measured from ST – superior alveolar ridge measured in the DP view.

## **KEYWORDS**

Mental foramen, CBCT, Panoramic radiograph, CBCT reformatted panoramic view, horizontal position, vertical position, measurements, difference.

## Chapter 1 : INTRODUCTION

Dental radiography remains a core component of the diagnostic process in modern dental practice. Although a multitude of techniques and technical innovations have been made in maxillofacial radiography, basic imaging modalities, such as panoramic radiography, that are of high quality and dimensionally accurate remain as the baseline for diagnosis and treatment planning (Suomalainen *et al.*, 2015; Rushton & Horner 1996; Devlin & Yuan 2013; Assaf & Abu Gharbyah 2014).

In recent years, the development and integration of affordable cone beam computed tomography (CBCT) into dental practice has introduced a new dimension in the diagnostic capabilities of dentists. This allows a three-dimensional perspective to surgical planning and the use of computer aided surgical procedures. Furthermore, the resultant multiplanar images are reconstructed with highly reproducible dimensions (Shah *et al.*, 2014; Moshfeghi *et al.*, 2012; Stratemann *et al.*, 2008). Moreover, The CBCT reformatted panoramic view offers a superior panoramic view of the jaw and produces a clear sliced image free of inherited distortions (magnification and superimposition) compared to digital panorama (Angelopoulos *et al.*, 2008).

The evaluation of the indications, advantages, and drawbacks of each radiographic modality is essential to achieve optimum treatment outcomes to prevent unnecessary radiation exposure (Shah *et al.*, 2014).

The mental foramen (MF) is a bilateral aperture found on the buccal side of the mandible, from which the neurovascular bundles of the inferior dental canal emerge (Phillips *et al.*, 1990; Gupta *et al.*, 2015). This aperture is the termination of the mental canal that starts from inside the bone and ends on the buccal surface in different directions (Phillips *et al.*, 1990; Gupta *et al.*, 2015)

The proper understanding of the mental foramen's anatomy and its variations is essential to accurately manage the neurovascular structures during different clinical procedures (Budhiraja *et al.*, 2013). The nature and sensitivity of the dental procedure intended, and the proximity of vital structure such as the mental foramen, may play a vital role in the decision of the radiographic modality required. Several daily dental procedures may be carried out in close proximity to the mental foramen, which necessitates accurate visualisation and assessment. These procedures may include endodontic treatment, mental nerve anaesthesia, surgical

procedures including osteotomies, elevation of flaps, teeth impactions, removal of cysts and tumors, dental implants, and various incisions (Von Arx *et al.*, 2013).

One of the most important requirements of a specific technique is the ability to provide an accurate estimation of the dimensions and linear measurements that are carried out on the anatomical structures of the skull (Nagalaxmi *et al.*, 2015).

Current evidence comparing the dimensional differences between a standard panoramic view and a CBCT reformatted panoramic view are scarce. Additionally, there is a widespread impression that the data related to the dimensional accuracy of the CBCT reformatted panoramic views compared with real measurements is inadequate. It is unknown which panoramic view is a more reliable indicator of the mental foramen's position when compared to real anatomy. The dimensional differences between these two modalities remain unexplored and may have clinical significance in surgical treatment planning. This is particularly true as many clinicians prefer to use the digital panoramic view (over more invasive imaging modalities) in several dental procedures including implants planning (Kayal 2016; Vazquez *et al.*, 2011; Kim *et al.*, 2011).

This study explores the dimensional differences between digital panoramic radiographs (DP) and CBCT views (CBCT reformatted panoramic view (CRP) and oblique coronal view (CORO)) by evaluating the position of the mental foramen (Vertically and horizontally). The linear measurements of the MF's structure were analysed and compared between the two panoramic views to test the correlation of the MF's position. In addition, the mental foramen's vertical position was analysed and compared using three different views. Such an analysis would draw the attention of clinicians about the mental foramen presentation on different views.

## Chapter 2 : LITERATURE REVIEW

### 2.1 Panoramic radiography role in practice

The use of panoramic radiographs is very popular in the routine daily dental practice. In addition to examining the teeth and surrounding bony structures, different practitioners use panoramic radiographs for implant treatments (Suomalainen *et al.*, 2015; Vazquez *et al.*, 2008; Devlin & Yuan 2013; Assaf & Abu Gharbyah 2014).

The simplicity of the procedure, availability, lower costs and lower radiation dose of panoramic radiography (when compared with more sophisticated imaging techniques such as C.T or CBCT) , made it the most commonly used type of radiographs (Assaf & Abu Gharbyah 2014; Vazquez *et al.*, 2008; Kim *et al.*, 2011).

On the other hand, many disadvantages also exist, mainly those related to the image quality and sharpness such as distortion, vertical or horizontal magnification and subsequent measurement discrepancy, 2-dimensional limitation, focal trough limitations, and overlapping (Rondon *et al.*, 2014; Rushton & Horner 1996; Walker *et al.* 2009; Devlin & Yuan 2013; Wikner *et al.*, 2016; Nagarajan *et al.*, 2014; Shah *et al.*, 2014).

Nagarajan *et al.*, (2014) reported that the radiographic modality to be used in implant treatments should allow for adequate assessment of the treatment indication, possible pathologies found in the bone, the location and distances of vital anatomical structures, and the bone quantity with accurate dimensions in the vertical, horizontal, and buccolingual directions. This information is essential to determine the right length and width of the implant to be used.

Although three-dimensional modalities provide a better dimensional accuracy, many dentists still prefer to use panoramic radiographs for the purposes of implant assessment (Devlin & Yuan 2013). The use of panoramic radiograph is not limited to general assessment, but also to assess the vertical bone dimensions (Kayal 2016; Vazquez *et al.*, 2011; Kim *et al.*, 2011).

A study done by Monsour & Dudhia (2008) showed that using panoramic radiographs for pre- and post-implant assessment carries several limitations and drawbacks. These include the two-dimensional limitations, the inability to assess the bone width, and the inherent image distortions that might be encountered e.g. distortion in the horizontal plane and magnification that may occur in the vertical plane. They further added that the extent of accuracy and distortion would primarily depend on the operator skills and the position of the patient.



Panoramic radiography has some challenges from a practical sense, especially those related to the positioning procedures of patients. A sharp and undistorted radiograph could be obtained with optimum positioning of the patient in the machine and according to the manufacturer instructions (Dhillon *et al.*, 2012). Positional errors will lead to major distortions in the panoramic image, which is due to vertical and horizontal magnification discrepancy (Dhillon *et al.*, 2012).

Several studies reported that as a requirement, the measurement error obtained from different radiographic modalities need to be less than 1 mm for the purpose of implant placement (Ganguly *et al.*, 2011; Nikneshan *et al.*, 2014).

## **2.2 Anatomical overview of the mental foramen**

The third division (mandibular) of the fifth cranial nerve (trigeminal nerve) passes through the mandibular foramen in the mandible then travels anteriorly whilst located in the inferior dental canal. The nerve then crosses over from the lingual to the buccal side of the mandibular jaw and terminates in the anterior area of the mandible (Wadu *et al.*, 1997; Greenstein &Tarnow 2006).

Usually, in the first molar area, the inferior dental canal runs in the middle of the buccolingual space (Greenstein &Tarnow 2006; Juodzbaly *et al.*, 2010).

Studies illustrated that the inferior dental nerve splits into two distinctive branches somewhere in the molar area. The two branches are the mental and incisive nerves, which run parallel to one another and communicate through a network of small fibres (Wadu *et al.*, 1997, Greenstein &Tarnow 2006). The incisive nerves then course down from the area of mental foramen forming another curvature ending in the anterior mandible area (Wadu *et al.*, 1997). The mental nerve then travels in an ascending direction and exits through the mental foramen. The skin covering and the mucous membranes lining of the mental area, lower lips, as well as the gingiva as far back as the second premolar, are all innervated by the mental nerve (Mraiwa *et al.*, 2003). Variations of MF in shape, position, and the presence of lateral or accessory foramen or even the absence of the mental foramen could be encountered (Budhiraja *et al.*, 2013).

## **2.3 Mental foramen position**

The mental foramina are located on the anterolateral buccal segments (right and left) of the mandible. Some variation in this anatomical structure (structural anatomy, position, existence, etc.) may be encountered in daily practice, so it is essential that an accurate pre-assessment of

the MF is carried out before performing any procedure related to that structure (Budhiraja *et al.*, 2013).

Due to the importance of the mental foramen, the position and the anatomical characteristics of the structure have been studied by various researchers using plain x-ray techniques and more sophisticated imaging modalities (Aminoshariae *et al.*, 2014; Mohammad *et al.*, 2016; Vujanovic-Eskenazi *et al.*, 2015; Bou Serhal *et al.*, 2002; Luangchana *et al.*, 2015; Pertl *et al.*, 2013).

The majority of the studies encountered, revealed that the mental foramen was found in an area beneath the apex of the second premolar or between the apices of the first and the second premolar (Dobrea *et al.*, 2015; Bharathi *et al.*, 2016; Afkhami *et al.*, 2013; Verma *et al.*, 2015; Parnami *et al.*, 2015). It has also been observed -but in lower percentages- under the apical area of the first premolar or in an apical area that lies between the second premolar and the mesial root of the first molar (Dobrea *et al.*, 2015).

Six hundred digital panoramic radiographs were studied in Palestine by Mohammad *et al.* in (2016) to determine the position of the mental foramen. The researchers found that 41.6% and 39.7% (right and left, respectively) of mental foramina were located between the first and second mandibular premolar. Furthermore, the researchers found that 37.5% and 39.4% (right and left, respectively) were located in line with the longitudinal axis of the second mandibular premolar (Mohammad *et al.*, 2016).

The majority of studies showed variations in the positions among individuals, populations, age, races, and ethnic groups (D'dharan *et al.*, 2015; Parnami *et al.*, 2015; Budhiraja *et al.*, 2013; Bharathi *et al.*, 2016).

A study by Bharathi *et al.*, (2016), found that the foramen's position is not always symmetrical, even for the same person.

It has been suggested that clinicians should cautiously identify the mental foramen, by investigating all influencing factors, prior to proceeding in their dental and surgical procedures (Parnami *et al.*, 2015).

#### **2.4 Mental foramen size**

A Morphometric study done on 22 Caucasian skulls showed that the height ranged from [2.5 to 5.5 mm] and the widths from [2 to 5.5 mm] (Neiva *et al.*, 2004).

Von Arx *et al.*, (2013) conducted a retrospective analysis on CBCT volumes to study the mental foramen anatomy and dimensions. The researchers found the MF height ranged from [1.8 to 5.1 mm] and the length from [1.8 to 5.5] mm.

A study in India conducted by Singh & Srivastav in (2010) on one hundred dried adult human mandibles found that the average horizontal size was 2.79 mm [1-5mm] on the right side while on the left side the average was 2.57mm [1-6mm].

Carruth *et al.*, (2015) studied the size and position of the MF on CBCT views (axial, tangential and coronal view). The researchers found that the mean width of the MF was 4.08 mm analysed on axial view and 4.12 mm analysed on tangential view. The mean height was 3.54 mm analysed on tangential view and 3.55 mm analysed on coronal view.

## **2.5 Mental foramen shape**

Singh & Srivastava in (2010) found that out of one hundred dried mandibles studied, the majority had round shaped MF with smaller percentages showing oval architecture. The right and left sides showed slight variations in the percentage of shape variation.

Mbajiorgu *et al.*, (1998) in Zimbabwe studied 32 mandibles concerning the mental foramen's shape and position. The researchers found that 43% of the MF were round (14/32) and the rest were oval (56.3%).

Mohammad *et al.*, (2016) conducted a study in Palestine to assess the position of the mental foramen. The researchers found that the MF showed round shape in 51.6% (right and left) of the studied specimen, oval shape in 8.3%, 10.5% (right and left respectively), and irregular in 40.1%, 43.6% (right and left, respectively). In addition, the study found that the radiographic appearance of MF on the panoramic radiographs studied was mostly the continuous type.

Yosue & Brooks in (1989) described and classified the appearance of mental foramen visible on panoramic radiographs into a continuous, separated, diffuse, or unidentified type.

## **2.6 Accessory mental foramen (AMF) incidence and position**

Singh & Srivastava (2010) found an accessory mental foramen in 13 out of 100 mandibles examined. Eight of these accessory foramina were found situated below the apex of the first molar and the other five were in the first and second premolars area. The average size reported was 1mm [0.6-1.5mm].

## 2.7 CBCT accuracy in linear measurements

### 2.7.1 Overview

One study conducted on dry human skulls and CBCT by Moshfeghi *et al.*, (2012) showed that the authors took measurements for specific landmarks on skulls using a calliper and then compared that measurement to measurements obtained from the CBCT. The results showed that in the axial and coronal planes, CBCT was very precise and could reproduce the linear measurements. The authors also recommended the use of larger voxel size when linear measurements assessment is required, as the voxel size does not alter the measurement accuracy while lowering the inflicted radiation dose and accelerating the volume depiction time.

It is mentioned that the CBCT imaging modality considered to be the greatest current imaging method in dental practice for the accurate assessment of the position, anatomy, and demarcations of the mental foramen (Aminoshariae *et al.*, 2014). They also discussed the shortcomings and some disadvantages that could be encountered in practice such as radiation biological effects, excessive costs, and the delay in time due to the reconstruction process of data by a computer (Aminoshariae *et al.*, 2014). In addition, the CBCT image quality could be compromised by highly dense structures that may be encountered. This will result in scatter and beam hardening artefacts on the resultant views (Shah *et al.*, 2014). Furthermore, the CBCT modality has a poor capacity for the estimation of bone density due to the distortion of Hounsfield Units (Shah *et al.*, 2014).

Another study was done in Japan (Stratemann *et al.*, 2008) to compare CBCT with physical measurements. The authors concluded that CBCT revealed highly accurate data and values when compared with the physical linear measurements obtained from human skulls, giving less than a 1% relative error.

Some of the studies reveal that there is a slight underestimation in CBCT measurements from the true anatomical measurements (Baumgaertel *et al.*, 2009; Luangchana *et al.*, 2015). The authors argued that this underestimation from a clinical point of view is safer than overestimation in terms of preserving vital structures during dental treatments at their vicinity (Luangchana *et al.*, 2015).

In a study conducted in Thailand (Luangchana *et al.*, 2015), the authors studied fifty implant sites from six skulls using CBCT, panoramic radiographs, and compared them with physical

measurements obtained using a digital calliper. The authors found that CBCT is a precise and reproducible technique regarding the vertical measurements assessment. The study also found that in CBCT, the position of the head during radiography did not have an impact on the measurements, while in panoramic radiography, accuracy of linear measurements is obtained only when the patient is correctly positioned.

A study conducted in Spain (2015) compared CBCT to panoramic radiography to evaluate the mental loop. Images with magnification were revealed by panoramic radiography compared to those obtained from CBCT. The authors discovered that the differences between the panoramic radiographs and CBCT in terms of identification and length of the mental loop were insignificant in terms of statistics. They reported that in a 2-dimensional image, one cannot expect that the assessment would be efficient at all times. The study, therefore, recommend CBCT when planning dental procedures that are in proximity to vital structures like the mental nerve (Vujanovic-Eskenazi *et al.*, 2015).

### **2.7.2 CBCT reformatted panoramic view:**

Angelopoulos *et al.*, (2008) showed that the CBCT reformatted panorama is much better than the digital panoramic radiographs in the identification of the inferior dental canal. The authors reported that the reformatted panoramic modality allows for the production of a clear sliced image free of inherited distortions (magnification, superimposition). Such image could offer better identification and demarcation of the anatomical structures studied.

Correa *et al.*, (2014) conducted a study on digital panoramic radiographs, CBCT reformatted panoramic views, and CBCT cross-sectional views. The study compared the implant size (width and length) planned on these radiographic views with four implant systems. The authors found that the planned implants were narrower when measured on the cross-sectional CBCT view compared with digital panorama and reformatted CBCT panoramic view. The authors also found that the implants width (but not the height) measured in the upper premolar area were different between panorama and CBCT panorama.

Alkhader & Hudieb in (2014) conducted a study on CBCT oblique, reformatted panoramic views (reformatted at the automatic horizontal level only). The authors measured the mesiodistal space of single-implant sites seen on both views. The study found that there was no significant difference between the results obtained from both views and that the measurements correlated with one another. As a result, they concluded that both CBCT views could be used for the purposes of mesiodistal dimensional analysis of single-implant sites.

Another study conducted by Alkhader *et al.*, (2016) measured the mesiodistal space of single-implant sites seen on reformatted panoramic views but generated at three different horizontal levels. The authors found that the mesiodistal distance calculated in reformatted panorama generated at lower levels (apices of incisors) as well as the horizontal automatic level, were significantly lower than the mean mesiodistal values generated at higher levels up (central incisal edges and crest of the ridge levels). The study concluded that the reformatted panoramic views could yield different horizontal measurements when generated at different horizontal levels.

### **2.8 Panoramic radiographs linear measurements accuracy**

Neves *et al.*, (2014) conducted a study that showed that although CBCT offers improved observation of vital anatomical structures including; position, precise demarcation and relationships with the surrounding structures, panoramic x-rays are still the conventional technique that can be efficiently used in the assessment and study of jaw anatomy i.e. the bifid mandibular canals. Thus, CBCT should be indicated when the clinician decides that there is a need for further anatomical information.

Another study (Bou Serhal *et al.*, 2002) assessed the accuracy of detection and position of the mental foramen using panoramic radiography, computed tomography (C.T) and real measurements in vivo during implant surgery using a special calliper. After assessing the vertical plane measurements, the study showed that measurements on the panoramic radiographs were significantly different from both the perioperative measurements and computed tomography (CT). On the other hand, CT displayed negligible difference. The authors expressed this difference in terms of numbers as an average of +0.6 mm overestimation of the distances in panoramic images and -0.3 mm in computed tomography. In general, the negative mean error found in (CT) could be due to the lack of magnification errors and the superior control over patient's position. In the discussion of the main reasons of measurement overestimation in panoramic radiographs and its dangerous outcomes clinically, it is believed that patient positioning is a major causative factor (Bou Serhal *et al.*, 2002).

A study in Austria researched the accurateness of measurements obtained from panoramic, CT scan, and CBCT radiographs and compared the results with real anatomical measurements obtained from ten human cadaver heads. Their study indicated inaccuracy of panoramic radiographs in the assessment of vertical distances, especially in the anterior regions when

compared to the posterior regions of the mandible. The authors also reported the accuracy of CT and CBCT measurements found in the study (Pertl *et al.*, 2013).

A comparative study to assess the vertical dimension measurements of the jaws using dried human skulls with metal markers and with different head positions was conducted (Zarch *et al.*, 2011). The authors found that measurements of panoramic radiographs were underestimated in 83 % of the samples with only 8.5% overestimation and 8.5% with no difference. The authors also found that in the posterior area of the mandible the linear measurements are more reliable.

In a similar study, Mehra & Pai (2012) assessed the vertical and horizontal accuracy of the panoramic radiographs. The authors found that panoramic radiographs were accurate concerning horizontal and vertical measurements and concluded that it is a reliable method for implant size estimation but clinicians must take into consideration the appropriate magnification factors.

A study conducted in Palestine to assess the vertical measurements accuracy in the posterior mandible regions using digital panoramic radiographs (Assaf & Abu Gharbyah 2014). The study showed that the vertical dimension could be reliably assessed in the posterior mandibular segment given that the machine is calibrated and the manufacturer software is used.

A study in Brazil (2010) to assess the accuracy of bone height in the mental foramen area using periapical radiographs, panoramic radiographs, and C.T volumes was conducted (Bahlis *et al.*, 2010). The authors used ten dry human mandibles for comparison purposes. The study found that the periapical radiography and computed tomography showed the best accuracy compared to panoramic radiographs. One of the vertical variables measured showed average difference values of 0.33 mm (periapical radiography), 0.35mm (C.T) and 0.85mm (panoramic radiography).

In 2017, a study compared vertical and horizontal measurements of the alveolar ridge in several jaws locations studied on panoramic radiographs and CBCT volumes (sagittal plane, coronal plane, and cross-sectional plane) (Tang *et al.*, 2017). The researchers found that the magnification rates studied on panoramic radiographs were different. Never the less, the measurements obtained from panoramic radiographs were highly correlated with those obtained from the CBCT volume.

It is mentioned in the literature that the mental foramen could be shifted distally and their size may be increased 23% when examined on panoramic radiographs (Phillips *et al.*, 1992).

## **2.9 Conclusion**

There are opposing views in the literature regarding the superiority of one imaging modality compared to another. Even though there is debate and variations in results reported in different papers about the panoramic radiography accuracy, it is still the most common radiographic technique used in various daily dental procedures. It is essential to keep in mind, that there are practitioners around the world that only use panoramic radiographs for dental implant treatment.

After reviewing the literature and investigating what the recent papers revealed, it can be concluded that there is a broad agreement about the accuracy of measurements of CBCT. At the same time, many authors support the reliability and the use of panoramic radiography, even though there are some debates and dissatisfaction about the inherited image errors that might be encountered.

To the best of this study's author knowledge, the literature on the accuracy of CBCT reformatted panoramic view is scant and needs more attention for prospective research. The studies conducted to compare the digital panoramic and CBCT reformatted panoramic measurements are particularly limited.

Therefore, this comparative study is intended to reveal some details about the comparability of CBCT panoramic views and digital panoramic radiographs using the position of MF as a parameter to study and compare.



## Chapter 3 : AIMS AND OBJECTIVES

### **3.1 Aim:**

To compare the linear measurements obtained from digital panoramic radiographs and CBCT views for the determination of the mental foramen position.

### **3.2 Objectives:**

- 1- Identify key reference points for linear measurements on the radiographs obtained from digital panoramic radiographs and CBCT volume.
- 2- Study the horizontal linear measurements on the digital panoramic radiographs and CBCT volume (X1, X2).
- 3- Study the vertical linear measurements on the digital panoramic radiographs and CBCT volume (Y1).
- 4- Study the internal dimensions of the mental foramen (height and width) on the digital panoramic radiographs and CBCT volume (MH, MW).
- 5- Compare the vertical, horizontal measurements as well as the mental foramen dimensions obtained from digital panoramic radiographs with those obtained from CBCT views.

## Chapter 4 : MATERIALS AND METHODS

### 4.1 Study design

The study was a retrospective cross-sectional analytical study. It was conducted on radiographs that were taken earlier for the purposes of general dental treatments. The database was analysed and the patients who met the inclusion criteria were selected for the analysis. All the measurements were conducted virtually using the software provided by the manufacturer.

### 4.2 Instruments and machines

The machine that was used in this study is the Carestream® CS9000 3D. The CBCT volumes and the digital panoramic radiographs were taken on the same machine. The software that was used to study the panoramic radiographs is the Carestream® Dental Imaging Software v6.13.1.12 and for the CBCT volumes was the Carestream® 3D imaging ® (v 3.3.11). The laptop that was used for the first observer was Lenovo® ThinkPad® E560 I7® with a 15.6" (HD (1366 x 768) Anti-glare LED-Backlit Display) display screen. The second observer used Dell® PC (DELL® OPTIPLEX® 3040 CORE I5 ®) with Dell® 20 Monitor P2017H (1600 x 900 at 60Hz, 94 PPI). The x-ray tube specifications : Tube voltage 60 - 90 kV (max), Tube current 2 - 15 mA (max) Tube focal spot 0.5 mm, and Total filtration > 2.5 mm eq. Al. The 3D Modality specifications: Volume size 50 x 37 mm, Voxel size 76 x 76 x 76 µm (isotropic voxel), and CMOS sensor with optical fibre. The panoramic Modality has a CCD Sensor technology (Optical fibre sensor), with Magnification 1.27, and the Exposure time (Depending on the program selected) ranges from 4 sec. to 16 sec (13.9 sec. for standard Adult and 13.2 sec for standard paediatric). Radiographs were taken by experienced and trained technicians in the centre with compliance to the manufacturer's instructions. The radiographs were taken under routine daily conditions and the head positions were not standardized for the purpose of our study.

### **4.3 Target Population**

The patients who presented at “Qirresh radiology centre –Ramallah City, Palestine” between December 2008 and December 2016. The CBCT volumes and digital panoramic radiographs for the same patients were selected.

### **4.4 Sample selection process and size:**

Samples were selected from the database records following systematic random sampling techniques. The sample patients were selected with respect to the inclusion and exclusion criteria shown below and after the examination of medical and personal history recorded for each patient.

The study was conducted on computer-based radiographic records of thirty-one patients.

### **4.5 Inclusion criteria:**

- 1- Patients over 18 years with fully erupted, present and fully root developed mandibular teeth (from the 3<sup>rd</sup> cuspid up to 2<sup>nd</sup> mandibular molars).
- 2- Patients with a panoramic radiograph and CBCT volume showing the mental foramen region.
- 3- High-resolution radiographs (Panoramic and CBCT views) of adequate diagnostic quality (sharp and free of distortion).
- 4- The mental foramen should be clearly visible and should be demarcated on both radiographic modalities (all the margins of the foramen must be clearly defined).
- 5- The apices of the reference teeth mesial and distal to the foramen must be clearly defined.
- 6- Reasonably aligned teeth in the area of study.

### **4.6 Exclusion Criteria:**

- 1- The presence of pathologies in the area of study (including radiolucencies in the jaw, periodontal lesions, etc.).
- 2- Missing teeth in the study area (missing mandibular canine, premolars and first mandibular molar).
- 3- Poor visualization of the mental foramen (Images should be clear enough to show the demarcation of the mental foramen).
- 4- Images with distinct distortion, artifacts and superimposed metal objects in the area of study.

#### **4.7 Data analysis:**

All descriptive data were presented with Mean, Standard deviation, and a 95% confidence Interval. Differences in means between two variables were assessed using a repeated measures t-test and if the data were found to follow normal assumptions, an appropriate nonparametric test was employed.

An ANOVA test was conducted to determine the difference in means between variables if the same area has been measured by more than two different techniques. If ANOVA assumptions were not met, an appropriate nonparametric test was employed. All results were deemed statistically significant if  $p < 0.05$ . All data were captured in Excel® and exported to STATA® for statistical analysis, StataCorp. 2011. *Stata Statistical Software®: Release 12*. College Station, TX: StataCorp LP.

The results were repeated by the primary observer to analyse the intra-observer agreement. And were repeated by a second observer to assess the level of agreement between the two observers (Inter-observer agreement).

#### **4.8 The proposed methodology**

##### **4.8.1 Conditions of measurements**

The measurements and the studies were carried out on the digital panoramic radiographs (**DP**), CBCT reformatted panorama (**CRP**), and CBCT oblique coronal view (**CORO**).

The digital panoramic radiographs (**DP**) were studied via the provided software and the sharp enhancement mode was active for the entire studied sample. The digital panoramic software provided a virtual ruler to conduct the measurements. The only limitation was that the software did not allow the observers to conduct all the measurements at once and only allowed three measurements to be conducted in every attempt.

The CBCT views were studied on the provided software and using the virtual ruler provided in the same software, which allowed all the measurements to be conducted at the same time. The CBCT views were studied on the curved slicing mode. The panoramic views were reformatted with a slice thickness of 15mm. Multiple points have been selected on the axial view (at the level of the mental foramen) to reconstruct the panoramic trough area, these points were selected in the middle of the ridge (buccolingually) .

The observers were allowed to modify brightness and contrast during the study in order to optimize the view and allow better identification of the anatomic structure on both radiographic modalities.

#### **4.8.2 Measurements methodology**

Distances mesial, distal, and superior to the mental foramen (MF) outer margins were measured and recorded. The mesial and distal distances (X1, X2) start from the tangents drawn on the outer margins of the MF and end in reference lines (L1, L2) dropped down from selected points on teeth's apices mesial and distal to the MF. The superior distance measured from the superior tangent of MF up to the superior alveolar cortex of ridge (Y1).

All the reference points, lines, and distances that were chosen and measured on the digital panoramic radiographs (**DP**) were reproduced on the corresponding CBCT views for the same patient (Figure 4.1). Table 4.1 summarizes all the measured distances.

#### **4.8.3 Choosing reference points**

Reference points were chosen in relation to the apices of the teeth that are in close proximity to the mental foramen. These reference points represent the points from where we dropped down straight vertical lines (L1, L2) to establish the mesial and distal ends of the measured distances from the MF lateral tangents. These points were selected in the middle of the root's apices of the selected teeth.

The teeth were selected to be at the closest measurable distance mesial and distal to the mental foramen on the horizontal plane. However, each patient may have his own distinct two reference points, based on his own variance in the mental foramen position, teeth available, anatomic variations, observer preference, and the radiographic picture. As a result, the patients may have different reference points selected from each other (but these points were reproduced the same on the other studied radiographic modalities). After these points have been chosen, they have been saved and screen captured for the reproduction of the same points on the other CBCT views.

In the case of a multi-rooted tooth, we have chosen the mesial or distal root depending on factors of clarity and presence of a measurable distance between them and the tangents of the mental foramen. However, the same selected root apex was selected on the corresponding CBCT views.

After the identification of the reference points, straight vertical lines were dropped down from these reference points (teeth apices) to act as vertical reference lines (L1 and L2) (Figure 4.1).

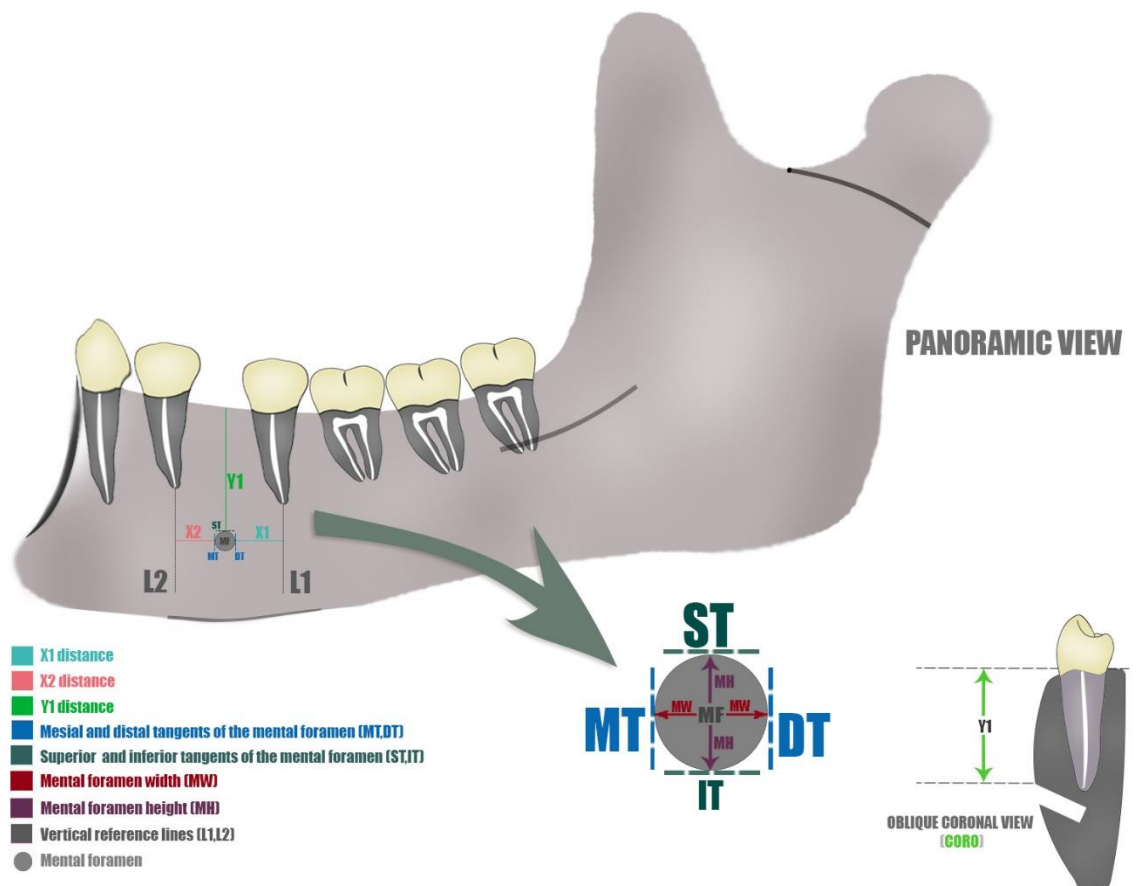


Figure 4.1. Measurement methods

Variables	Digital panorama (DP)	CBCT Reformatted Panorama (CRP)	CBCT Coronal (CORO)
X1 (distance from root tip distal to mental foramen to the distal tangent of the mental foramen)	YES	YES	NO
X2 (distance from root tip mesial to mental foramen to the mesial tangent of the mental foramen)	YES	YES	NO
Y1 ( vertical distance from the uppermost tangent ST of the mental foramen to the crest of the ridge)	YES	YES	YES
MW (mental width)	YES	YES	NO
MH (mental height )	YES	YES	NO

Table 4.1. The variables (distances) studied on the radiographic views

#### **4.8.4 Mental foramen demarcation and measurements process**

The shape and anatomy of the mental foramina are variable. However, they generally have circular or ovoid architecture on a radiograph whether it is regular or irregular in shape. In order to standardize the procedure, we decided to carry out our measurements depending on the outer point of the mesial and distal borders of the foramen. Thus, we drew a mesial (MT), distal (DT), superior (ST), and inferior tangent (IT) on the outermost borders of the mental foramen. These MF tangents were the starting limit of our distances measurements (the other measurement's limits are the L1, L2, and upper superior alveolar cortex) (Figure 4.1).

#### **4.8.5 Measurements on the digital panoramic radiograph (DP)**

##### **4.8.5.1 Horizontal measurements X1, X2 (Horizontal position of the MF):**

A measured horizontal line was drawn from the distal tangent of MF (DT) to the distal reference line (L1) to measure the distal distance X1 (L1 – MT.) Another Measured line was drawn from the mesial tangent of MF (MT) to the mesial reference line (L2) to measure the mesial distance X2(L2-DT.) X1, X2 represent the horizontal distance of the mental foramen (Figure 4.1).

##### **4.8.5.2 Internal dimensions of the mental foramen**

The height and width of the mental foramen were measured. Horizontal measured straight line between the mesial tangent (MT) and distal tangent (DT) of the MF was drawn to measure the width of the foramen (MW). Another vertical straight measured line between the superior tangent (ST) and inferior tangent (IT) of the MF was drawn to measure the height of the mental foramen (MH) (Figure 4.1).

##### **4.8.5.3 Vertical measurements Y1 (vertical position of the MF):**

A vertical straight measured line was drawn from a standardized point on the superior margin of the mental foramen (not the superior MF tangent (ST)) and up to the upper alveolar cortex (Figure 4.2). That distance represents the vertical position of the mental foramen (Y1).

In order to standardize the measurements between the panoramic modality and the CBCT views, we started our vertical measurement from a standardized point on the superior margin of the mental foramen and not from the superior MF tangent (ST). We draw our point from the most superior point identified on the MF at a horizontal level of the mid-distance of the mental foramen width (MW) (as a horizontal reference).

The vertical distance Y1 may vary between the radiographic modalities and between observers if the vertical measurement starting point was randomly selected on the superior margin or

even on the superior tangent (ST). That is due to the fact that the upper alveolar cortex levels and superior margin of the MF may not be straight and uniform, so various heights could be obtained as you go in a mesial or distal directions (Figure 4.2). This method would allow the comparison of Y1 value not only with the CBCT reformatted panorama (CRP) but also with the coronal view as you can identify the exact corresponding coronal slice.

In cases where the patient was dentate, the upper limit was an estimated imaginary line connecting the interproximal bones (in case the bone level was not demarcated). In cases where the bone level was demarcated and superimposed over the tooth structure, the measurements were carried out to the visible bone level on that view.

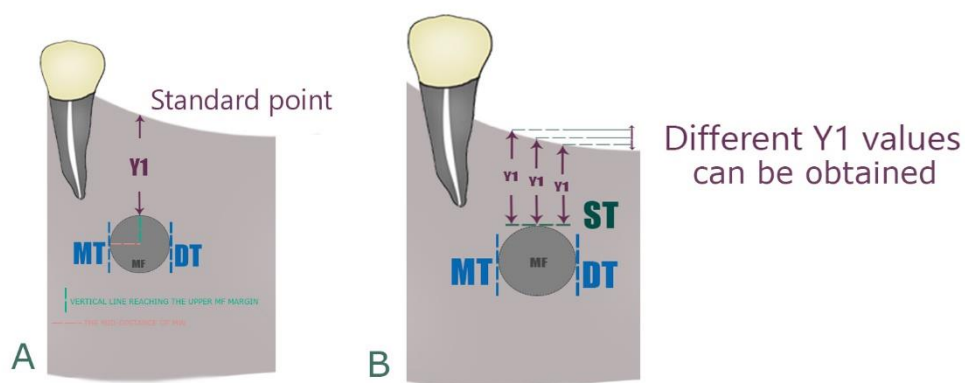


Figure 4.2. Panoramic view shows measuring Y1 from a standard point vs. any point from the tangent

#### 4.8.6 Measurements on the CBCT views

The measurements of the distances (X1, X2, Y1, MH, and MW) were reproduced on a CBCT reformatted panoramic view. The vertical distances Y1 were also studied in the coronal view.

##### 4.8.6.1 Measurements on the CBCT reformatted panoramic view (CRP)

The exact same procedures were applied to the CBCT reformatted panoramic view. The same variables (X1, X2, Y1, MW, and MH) were measured according to the same selected reference points for the same patient (Figure 4.1).

In regard to the Y1 variable, we used the same standardized starting point (the middle of the distance of MW value that is measured on the CRP view).

##### 4.8.6.2 Oblique coronal CBCT view

The corresponding coronal slices of the Y1 line previously drawn on CRP view were selected. That was possible due to the fact that the CBCT software allows the user to navigate between the different views and planes simultaneously.



A horizontal line was drawn crossing the uppermost margin of the alveolar bone cortex. In addition, a horizontal line at a vertical level of the uppermost border of the MF was also drawn. Finally, a vertical measured line between these two horizontal lines was dropped down to measure the coronal Y1 distance (Figure 4.1).

#### 4.9 Ethical Consideration

The research was submitted to the Senate Research Ethics Committee of the University of Western Cape for approval and permission to carry out the study.

Permission was obtained from the director of “Qirresh Dental and maxillofacial radiology center” in Palestine to allow the usage of the patients’ records.

All the information obtained during this study were confidential and no personal identification of the patients was disclosed. All the radiographs were documented as allocated numbers.

The author does not have any conflict of interest in any brand or products that were used during the study.

#### 4.10 Budget

This research was a self-funded project.

#### 4.11 Example of measurements carried out

The following is an example of the measurements carried out during the study (Figures 4.3-4.11). Table 4.2 shows the obtained values.

Digital panorama (DP)					CBCT Reformatted Panorama (CRP)					CBCT Coronal (CORO)
X1DP1	X2DP1	Y1DP1	MHDP1	MWDP1	X1CRP1	X2CRP1	Y1CRP1	MHCRP1	MWCRP1	Y1CORO1
14,8	4,7	13,5	2,6	2,5	17,2	3	13,5	2,7	2,8	13

Table 4.2. The values obtained from the measured variables (distances)

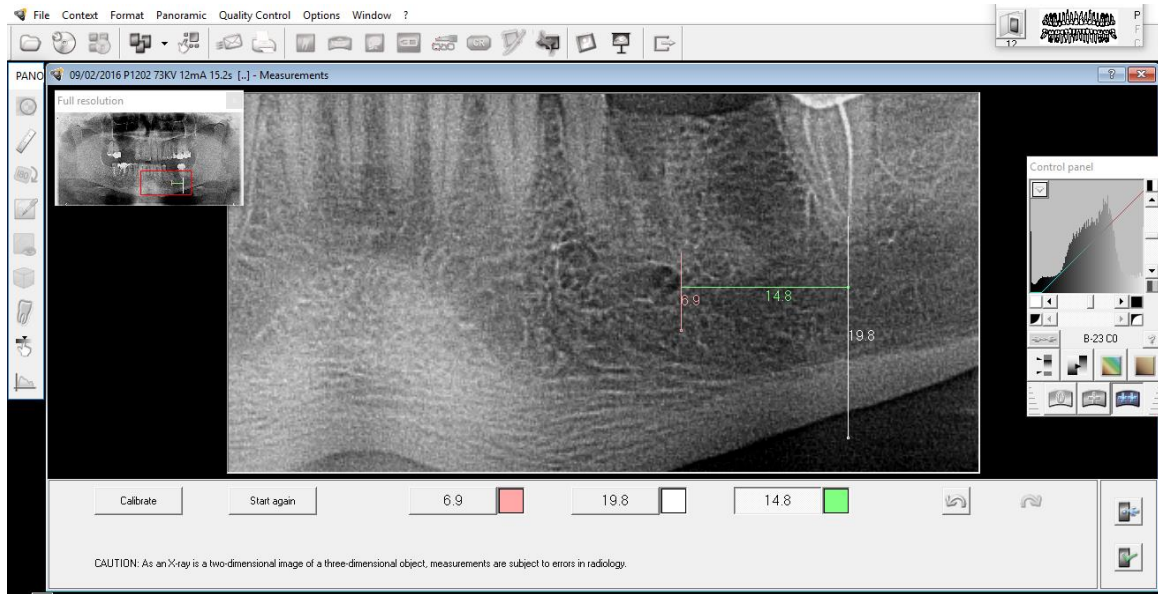


Figure 4.3. Digital panoramic view (DP), shows the measurement of X1 (14.8mm)

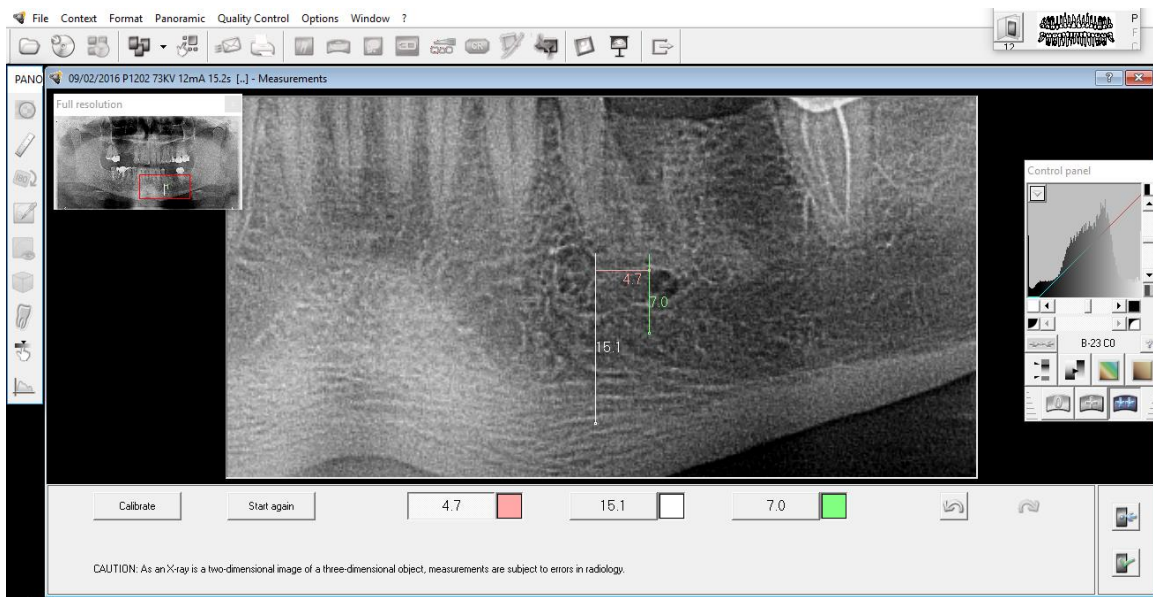


Figure 4.4. Digital panoramic view (DP), shows the measurement of X2 (4.7 mm)

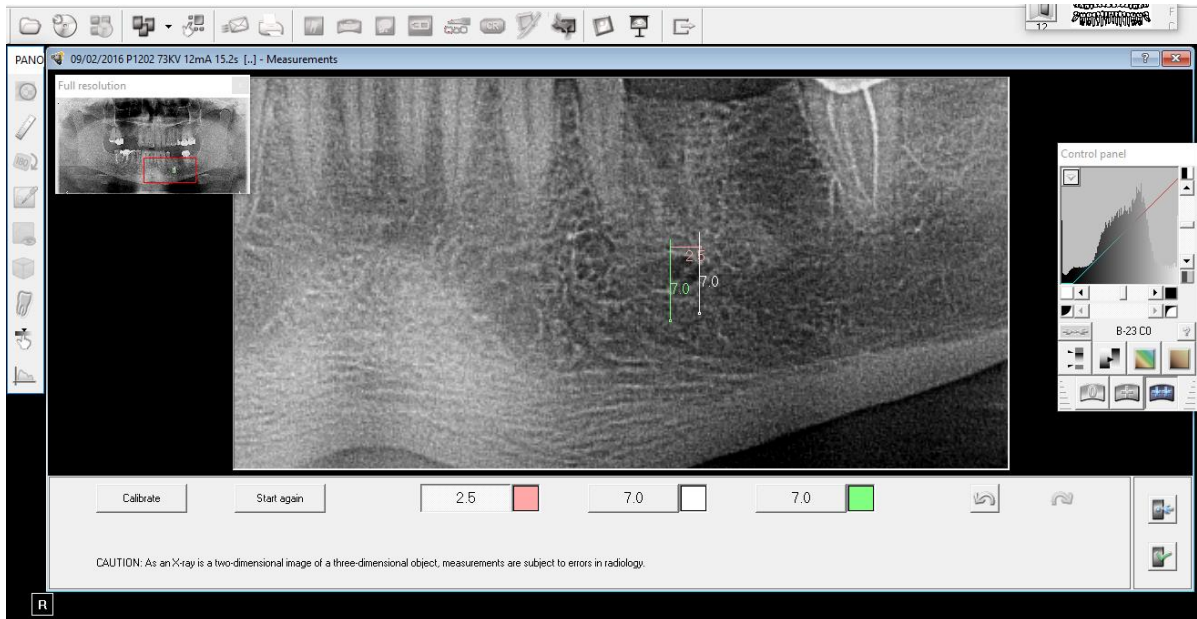


Figure 4.5. Digital panoramic view (DP), shows the measurement of MW (2.5mm)

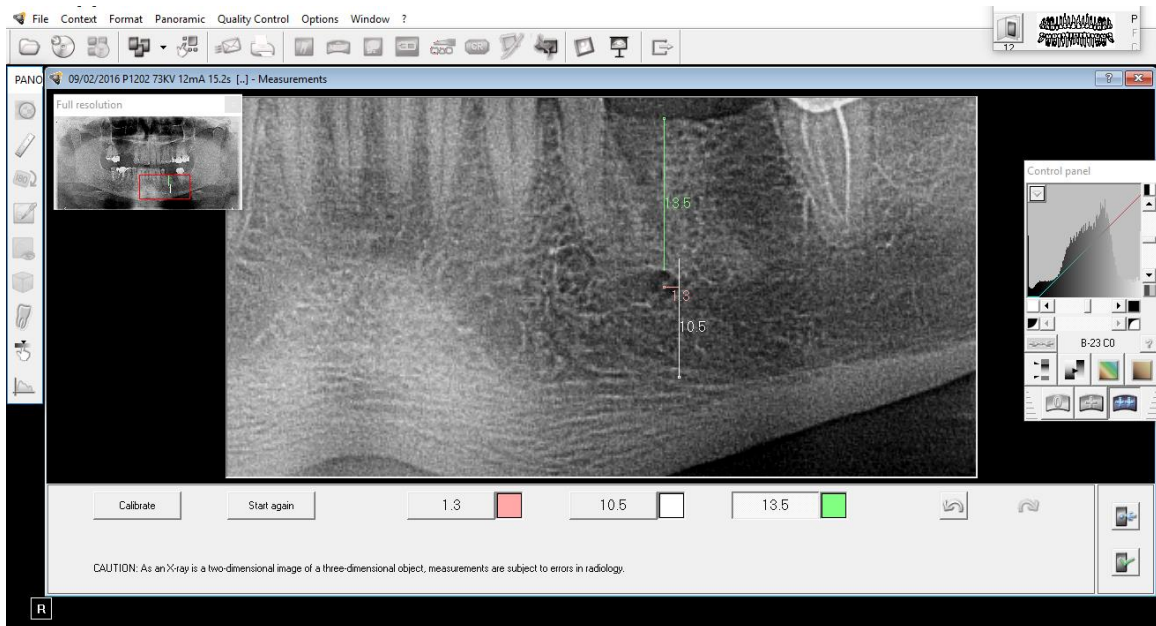


Figure 4.6. Digital panoramic view (DP), shows the measurement of Y1 (13.5mm)

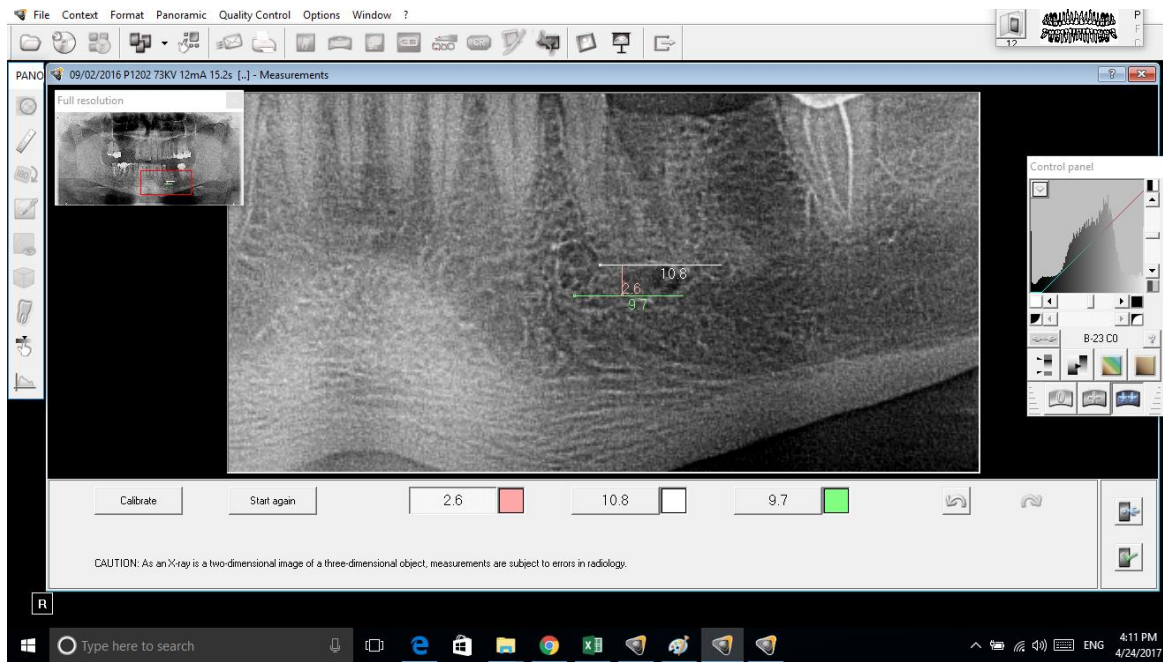


Figure 4.7. Digital panoramic view (DP), shows the measurement of MH (2.6 mm)

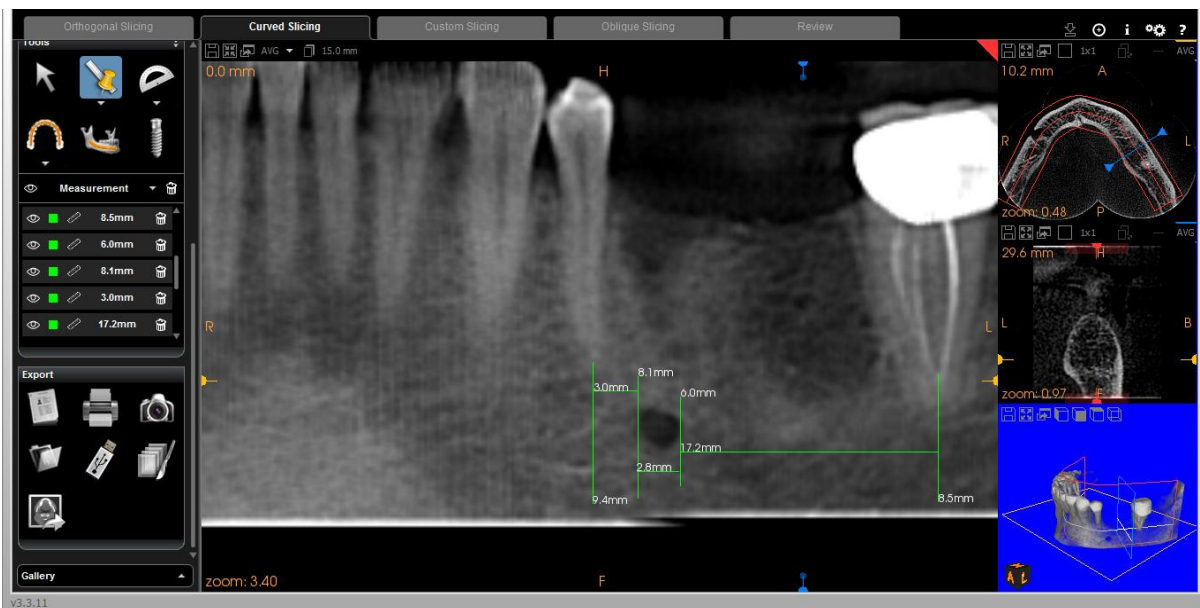


Figure 4.8. CBCT reformatted panorama (CRP), shows the measurements of X1, X2, MW (17.2mm, 3.0mm, 2.8mm, respectively)



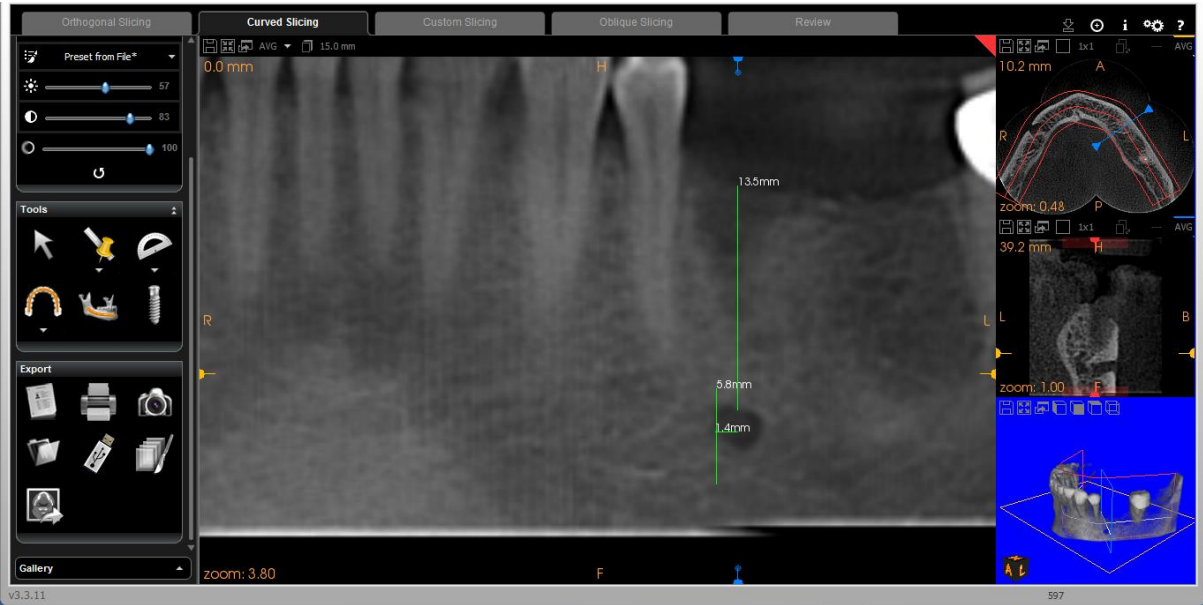


Figure 4.9. CBCT reformatted Panorama (CRP), shows the measurement of Y1 (13.5mm)

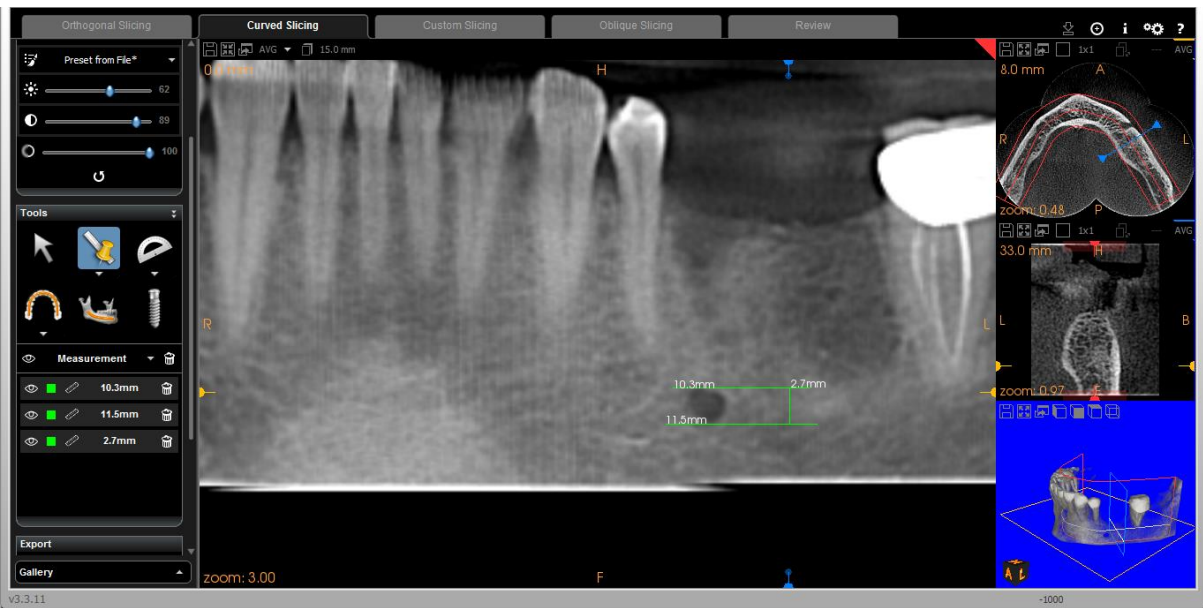


Figure 4.10. CBCT reformatted panorama (CRP), shows the measurements of MH (2.7mm)

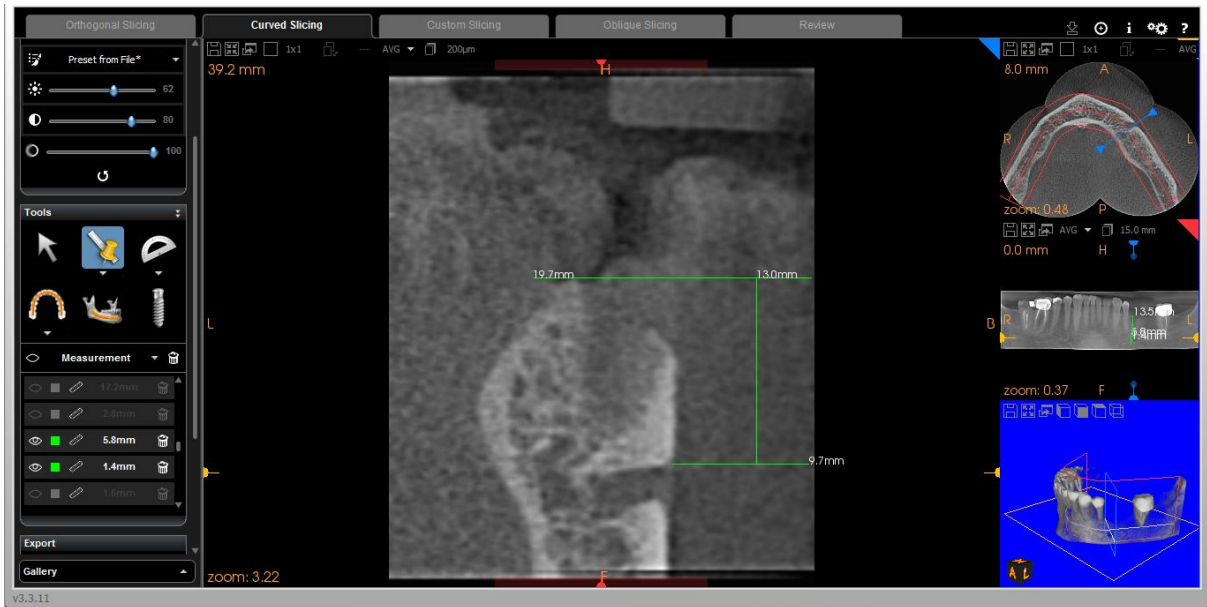

Figure 4.11.CBCT coronal view (CORO), shows the measurements of Y1 (13.0mm)

## Chapter 5 : RESULTS

### 5.1 Results Overview:

A total of 589 patients' files were examined, of which only 31 patients were selected as those patients complied with the inclusion criteria.

Statistical analysis was carried out, and showed that all the tested variables (X1, X2, MH, MW) displayed a statistical significance ( $p = 0.0412$ ,  $p = 0.0023$ ,  $p = 0.0018$ ,  $p = 0.0456$ , respectively). The detailed statistical analysis is illustrated in section 5.2. The statistical analysis of the vertical distance Y1 obtained from the three views (DP, CRP, and CORO) showed that the differences elicited statistically significant differences in the mean distance over the three different techniques,  $F(2, 54) = 34.97$ ,  $MSE = p < 0.000$ . The post hoc tests revealed that the mean difference between CBCT oblique coronal view (CORO) and digital panorama (DP) was the greatest, mean difference = 1.59mm,  $p < 0.05$ . The mean difference between CBCT reformed panorama (CRP) and CBCT oblique coronal view (CORO) views demonstrated a mean difference of 1.06mm,  $p < 0.05$  and the smallest mean difference in calculating Y1 was demonstrated between digital panorama (DP), and CBCT reformed panorama (CRP), mean diff. = 0.54mm,  $p < 0.05$ . The detailed statistical analysis is illustrated in section 5.2.6.

The X1 (CRP) mean distance was shown to be larger than the X1 (DP) of the same distance by 0.34mm. The X2 (CRP) mean distance was shown to be smaller than the X2 (DP) of the same distance by 0.52mm. The MH (CRP) was shown to be larger than the MH (DP) of the same distance by 0.39mm. The MW (CRP) was shown to be larger than the MW (DP) of the same distance by 0.16mm.

The maximum and minimum differences obtained from measurements (X1, X2, Y1, MH, MW, and Y1) have been calculated. These values are demonstrated in detail in Table 5.9 and illustrated by chart 5.2. The Y1 (DP-CORO) showed the highest maximum difference value (5.3 mm) Followed by Y1 (CRP-CORO), X1 (DP-CRP), Y1 (DP-CRP), X2 (DP-CRP), MH (DP-CRP), and MW (DP-CRP), respectively.

Table 5.10 and Chart 5.3 demonstrates the ranges of differences revealed by each distance studied along with the number of the patients showed these ranges.

The inter-examiner and intra-examiner agreements were analysed using Intra-class correlation coefficient (ICC). Inter-examiner analysis indicated “excellent” agreement in all the variable studied. The intra-examiner analysis indicated "excellent" agreement in all variable studied except in four of them which indicated "good" reliability. Sections 5.4, 5.5 contain further details.

## **5.2 Statistical analysis of the results:**

Three observations have been deleted due to outliers obtained (Table 5.1 & Chart 5.1). A total of 28 observations were analysed (Table 5.2). Paired t-test was conducted for the assessment of differences in means between variables (distances). ANOVA test was conducted for the assessment of the vertical distance Y1 studied on three radiographic views (**DP, CRP, and CORO**). All the tested variable are illustrated independently in sections 5.2.2 – 5.2.6.

Table 5.3 summarizes the resultant statistical analysis of the differences between the variables (distances) measured on digital panoramic radiographs and CBCT views (CRP, CORO). All results are deemed statistically significant if  $p < 0.05$ .



### 5.2.1 Observations deleted due to outliers

The patients number 2, 7, and 10 were outliers and were deleted in order to achieve normal distribution. Table 5.1 and Chart 5.1 illustrates the outliers found and deleted.

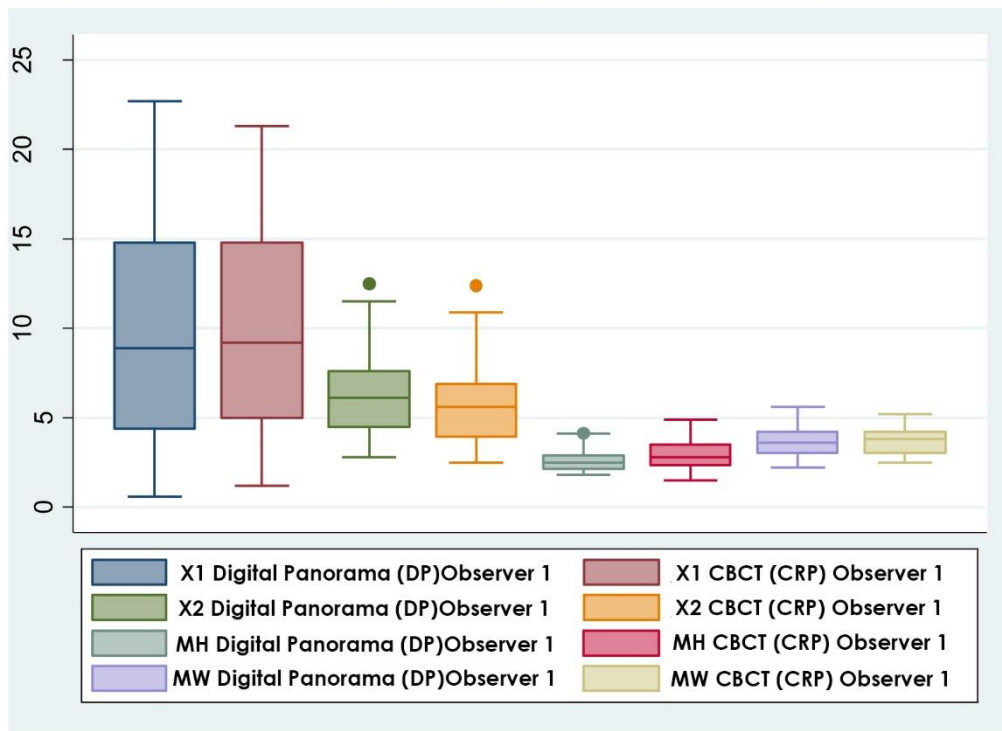


Chart 5.1. Box plot showing the outliers observations

<i>ID</i>	Technique	Site	Distance
<b>2</b>	DP	X2	12.5
<b>7</b>	CRP	X2	10.9
<b>10</b>	DP	MW	5.6

Table 5.1. Deleted observations

Site	N	Technique	Mean	Mean (SD)	Std. Err.	95% Confidence Interval
<b>X1</b>	28	DP	9.428	5.993	1.132	7.104-11.752
	28	CRP	9.767	5.906	1.116	7.477-12.058
<b>X2</b>	28	DP	5.957	1.887	0.356	5.225-6.688
	28	CRP	5.439	1.996	0.377	4.665 – 6.213
<b>MH</b>	28	DP	2.560	0.539	0.101	2.351 – 2.769
	28	CRP	2.95	0.719	0.135	2.671 – 3.228
<b>MW</b>	28	DP	3.496	0.659	0.124	3.240 – 3.752
	28	CRP	3.653	0.656	0.124	3.398 – 3.908
<b>Y1</b>	28	DP	15.4	2.86		14.25 – 16.47
	28	CRP	14.8	2.92		13.69 – 15.95
	28	CORO	13.8	3.01		12.59 – 14.93

\*Please note that the above mentioned table shows the statistical analysis of the obtained measurement values and not difference values.

Table 5.2. Summary statistics of X1, X2, Mental Height, Mental Width, and Y1 values

Site	N	Technique	Mean	Mean (SD)	CI	p-value
<b>X1</b>	28	DP	-0.34	0.83	[-0.66: -0.15]	0.0412 <sup>a</sup>
	28	CRP				
<b>X2</b>	28	DP	0.52	0.81	[0.2: 0.83]	0.0023 <sup>a</sup>
	28	CRP				
<b>Mental Height (MH)</b>	28	DP	-0.39	0.59	[-0.62: -0.15]	0.0018 <sup>a</sup>
	28	CRP				
<b>Mental Width (MW)</b>	28	DP	-0.16	0.39	[-0.31: -0.003]	0.0456 <sup>a</sup>
	28	CRP				
<b>Y1</b>	28	DP				<0.000 <sup>b</sup>
	28	CRP				
	28	CORO				

a- paired t-test  
b- ANOVA

Table 5.3. Summary statistics X1, X2, Mental Height, Mental Width, and Y1 difference values

### 5.2.2 Statistical analysis of variable X1:

The mean values and mean difference between the values (measurements) of X2 obtained from the digital panorama (**DP**) and CBCT reformed panorama (**CRP**) were statistically analysed. The following table 5.4 contains the revealed results of X1 analysis.

Variable	OBS	MEAN	Std. Err.	Std. Dev.	95% Confidence Interval	
<b>X1DP1</b>	28	9.428571	1.132701	5.993692	7.10446	-- 11.75268
<b>X1CRP1</b>	28	9.767857	1.116235	5.90656	7.477532	-- 12.05818
<b>DIFF.</b>	28	-0.339257	0.1582259	0.8372527	-0.6639384	-- -0.14633
Mean(Diff.) = Mean (X1DP1 – X1CRP1)					t = -2.1443	
Ho: Mean(Diff.) = 0					Degree of freedom = 27	
Ha : Mean(Diff.) < 0			Ha : mean(Diff.) != 0		Ha : Mean(Diff.) > 0	
Pr(T < t) = 0.0206			Pr( T  >  t ) = 0.0412		Pr(T > t) = 0.9794	

Table 5.4. Paired T-test results for the difference in means of X1DP1 and X1CRP1

The distance X1 (distance between the distal tangent (DT) of the mental foramen to the distal reference line (L1)) using CBCT reformatted panoramic view (**CRP**) was shown to be larger than the digital panorama (**DP**) of the same distance by 0.34mm, CI [-0.66: -0.15] (SD = 0.83). We can conclude that the difference between X1DP1 and X1CRP1 was statistically significant,  $p = 0.0412$ .

### 5.2.3 Statistical analysis of variable X2:

The mean values and mean difference between the values (measurements) of X2 obtained from the digital panorama (**DP**) and CBCT reformed panorama (**CRP**) were statistically analysed. The following table 5.5 contains the revealed results of the analysis.

Variable	OBS	MEAN	Std. Err.	Std. Dev.	95% Confidence Interval	
<b>X2DP1</b>	28	5.957143	0.356624	1.887077	5.225411	-- 6.688875
<b>X2CRP1</b>	28	5.439286	0.3772758	1.996356	4.66518	-- 6.213392
<b>DIFF.</b>	28	0.5178571	0.1538787	0.8142497	0.2021241	-- 0.8335902
Mean(Diff.) = Mean (X2DP1 – X2CRP1)					t = 3.3654	

Ho: Mean(Diff.) = 0		Degree of freedom = 27
Ha : Mean(Diff.) < 0	Ha : mean(Diff.) != 0	Ha : Mean(Diff.) > 0
Pr(T < t) = 0.9988	Pr( T  >  t ) = 0.0023	Pr(T > t) = 0.0012

Table 5.5. Paired T-test results for the difference in means of X2DP1 and X2CRP1

The distance X2 (distance between the mesial tangent (MT) of the mental foramen to the mesial reference line (L2)) using CBCT reformatted panoramic view (**CRP**) was shown to be smaller than the digital panorama (**DP**) of the same distance by 0.52mm, CI [ 0.2: 0.83] (SD = 0.81). We can conclude that the differences between X2DP1 and X2CBCT1 were statistically significant,  $p = 0.0023$ .

#### 5.2.4 Statistical analysis of variable MH:

The mean values and mean difference between the values (measurements) of the mental height obtained from the digital panorama (**DP**) and CBCT reformatted panorama (**CRP**) were statistically analysed. The following table 5.6 contains the revealed results of the analysis.

Variable	OBS	MEAN	Std. Err.	Std. Dev.	95% Confidence Interval
<b>MHDP1</b>	28	2.560714	0.1018791	0.5390934	2.351676 -- 2.769753
<b>MHCRP1</b>	28	2.95	0.1359369	0.7193104	2.671081 -- 3.228919
<b>DIFF.</b>	28	-0.3892857	0.1123745	0.5946298	-0.6198591 -- -0.1587123

Mean(Diff.) = Mean (MHDP1 – MHCRP1)		t = -3.4642
Ho: Mean(Diff.) = 0		Degree of freedom = 27
Ha : Mean(Diff.) < 0	Ha : mean(Diff.) != 0	Ha : Mean(Diff.) > 0
Pr(T < t) = 0.0009	Pr( T  >  t ) = 0.0018	Pr(T > t) = 0.9991

Table 5.6. Paired T-test results for the difference in means of MHDP1 and MHCRP1

The mean height of the mental foramen (MH) using CBCT reformatted panoramic view (**CRP**) was shown to be larger than the digital panorama (**DP**) of the same distance by 0.39mm, CI [-0.62 : -0.15], (SD = 0.59). We can conclude that the differences between Mental Height using **CRP** and **DP** were statistically different,  $p = 0.0018$ .

### 5.2.5 Statistical analysis of variable MW:

The mean values and mean difference between the values (measurements) of the mental width obtained from the digital panorama (**DP**) and CBCT reformed panorama (**CRP**) were statistically analysed. The following table 5.7 contains the revealed results of the analysis.

Variable	OBS	MEAN	Std. Err.	Std. Dev.	95% Confidence Interval	
<b>MWDP1</b>	28	3.496429	0.124667	0.6596756	3.240633	-- 3.752224
<b>MWCRP1</b>	28	3.653571	0.1241353	0.6568624	3.398867	-- 3.908276
<b>DIFF.</b>	28	-0.1571429	0.0749653	0.3966793	-0.310959	-- -0.0033267

Mean(Diff.) = Mean (MWDP1 – MWCRP1)	t = -2.0962
Ho: Mean(Diff.) = 0	Degree of freedom = 27
Ha : Mean(Diff.) < 0	Ha : mean(Diff.) != 0
Pr(T < t) = 0.0228	Pr(T > t) = 0.9772
	Pr( T  >  t ) = 0.0456

Table 5.7. Paired T-test results for the difference in means of MWP1 and MWCBCT1

The mean width of the mental foramen using CBCT reformed panorama (**CRP**) was shown to be larger than the digital panorama (**DP**) of the same distance by 0.16mm, CI[-0.31: -.003], (SD = 0.39). We can conclude that the differences between Mental Width using **CRP** and **DP** were statistically significant,  $p = 0.0456$ .

### 5.2.6 Statistical analysis of the vertical distance Y1

The mean, Mean (SD), Std. Err. , and 95% Confidence Interval of the vertical measurement Y1 obtained from the digital panorama (**DP**), CBCT reformed panorama (**CRP**), and CBCT coronal view (**CORO**) are illustrated in Table 5.8. ANOVA test was run and is illustrated in Figures 5.1.

Site	N	Technique	Mean	Mean (SD)	Std. Err.	95% Confidence Interval
<b>Y1</b>	<b>28</b>	<b>DP (Y1P1)</b>	15.36071	2.855319	0.5396045	14.25354 -- 16.46789
	<b>28</b>	<b>CRP (Y1CRP)</b>	14.825	2.925194	0.5528097	13.69073 -- 15.95927
	<b>28</b>	<b>CORO (Y1CORO1)</b>	13.76429	3.011855	0.5691871	12.59641 -- 14.93216

Table 5.8. Summary statistics of Y1 values obtained from DP, CRP, and CORO views

. anova y time id, repeated(time)

Number of obs = 84 R-squared = 0.9611  
 Root MSE = .726996 Adj R-squared = 0.9402

Source	Partial SS	df	MS	F	Prob > F
Model	704.509762	29	24.2934401	45.96	0.0000
time	36.9664286	2	18.4832143	34.97	0.0000
id	667.543333	27	24.7238272	46.78	0.0000
Residual	28.5402381	54	.528522928		
Total	733.05	83	8.83192771		

Between-subjects error term: id  
 Levels: 28 (27 df)  
 Lowest b.s.e. variable: id

Repeated variable: time

Huynh-Feldt epsilon = 0.7342  
 Greenhouse-Geisser epsilon = 0.7066  
 Box's conservative epsilon = 0.5000

Source	df	F	Prob > F			
			Regular	H-F	G-G	Box
time	2	34.97	0.0000	0.0000	0.0000	0.0000
Residual	54					

. wsanova y time, id(id) epsilon

Number of obs = 84 R-squared = 0.9611  
 Root MSE = .726996 Adj R-squared = 0.9402

Source	Partial SS	df	MS	F	Prob > F
id	667.543333	27	24.7238272		
time	36.9664286	2	18.4832143	34.97	0.0000
Residual	28.5402381	54	.528522928		
Total	733.05	83	8.83192771		

Note: Within subjects F-test(s) above assume sphericity of residuals;  
 p-values corrected for lack of sphericity appear below.

Greenhouse-Geisser (G-G) epsilon: 0.7066  
 Huynh-Feldt (H-F) epsilon: 0.7342

Source	df	F	Sphericity		
			Prob > F	G-G Prob > F	H-F Prob > F
time	2	34.97	0.0000	0.0000	0.0000

Figure 5.1. Part of the ANOVA tests carried out for the analysis of Y1 of three different radiographic views.

A one-way repeated measures ANOVA was run on a sample of individuals to determine if there was a difference in the distance between the vertical distances from the outer uppermost mental foramen border (ST) to the crest of the ridge of the jaw using 3 different techniques: digital panorama (**DP**), CBCT reformed panorama (**CRP**), and CBCT coronal view (**CORO**). The results showed that the differences elicited statistically significant differences in the mean distance over the three different techniques,  $F(2,54) = 34.97$ ,  $MSE = p < 0.000$ . This test was repeated assuming sphericity and the result was the same. Thus, the assumptions for repeated measures ANOVA was met.

\* Where time 1 is digital panorama (**DP**), time 2 is CBCT reformed panorama (**CRP**) and time 3 is CBCT coronal view (**coro**).

```
. tukeyhsd time
```

```
Tukey HSD pairwise comparisons for variable time
studentized range critical value(.05, 3, 54) = 3.4083643
uses harmonic mean sample size = 28.000
```

grp vs grp	group means		mean dif	HSD-test
1 vs 2	15.3607	14.8250	0.5357	3.8992*
1 vs 3	15.3607	13.7643	1.5964	11.6197*
2 vs 3	14.8250	13.7643	1.0607	7.7205*

The post hoc tests revealed that the mean difference between CBCT coronal view (**CORO**) and digital panorama (**DP**) was the greatest, mean difference = 1.59mm,  $p < 0.05$ . The mean difference between CBCT reformed panorama (**CRP**) and CBCT coronal view (**CORO**) views demonstrated a mean difference of 1.06mm,  $p < 0.05$  and the smallest mean difference in calculating Y1 was demonstrated between digital panorama (**DP**), and CBCT reformed panorama (**CRP**),  $\text{diff} = 0.54\text{mm}$ ,  $p < 0.05$ .

### 5.3 General interpretation of the values:

The differences between all the measurements obtained have been calculated and tabulated. Maximum, minimum, and ranges of these values were obtained and a general comparison between the values obtained from different radiographic views studied was also done.

#### 5.3.1 Maximum and Minimum values:

The highest maximum difference value between all the variables (distances) studied was obtained from Y1 (DP- CORO) with a maximum difference value of 5.3 mm. The minimum difference value between all the variables (distances) studied was 0 mm (no difference). Table 5.9 illustrates the maximum and minimum of variables (measurements) difference values (Demonstrated also in Chart 5.2).

	DP-CRP X1	DP-CRP X2	DP-CRP MH	DP-CRP MW	DP-CRP Y1	DP- CORO Y1	CRP-CORO Y1
<b>Maximum</b>	2.9	2	2	1	2.6	5.3	5
<b>Min.</b>	0	0	0	0	0	0	0

\*Note: **DP-CRP** is the difference between values of the digital panorama to values of CBCT reformatted panorama. **DP-CORO** is the difference between values of the digital panorama to values of CBCT coronal view. **CRP-CORO** is the difference between values of CBCT reformatted panorama to values of CBCT coronal view.

Table 5.9. Maximum and Minimum of variables (measurements) difference values

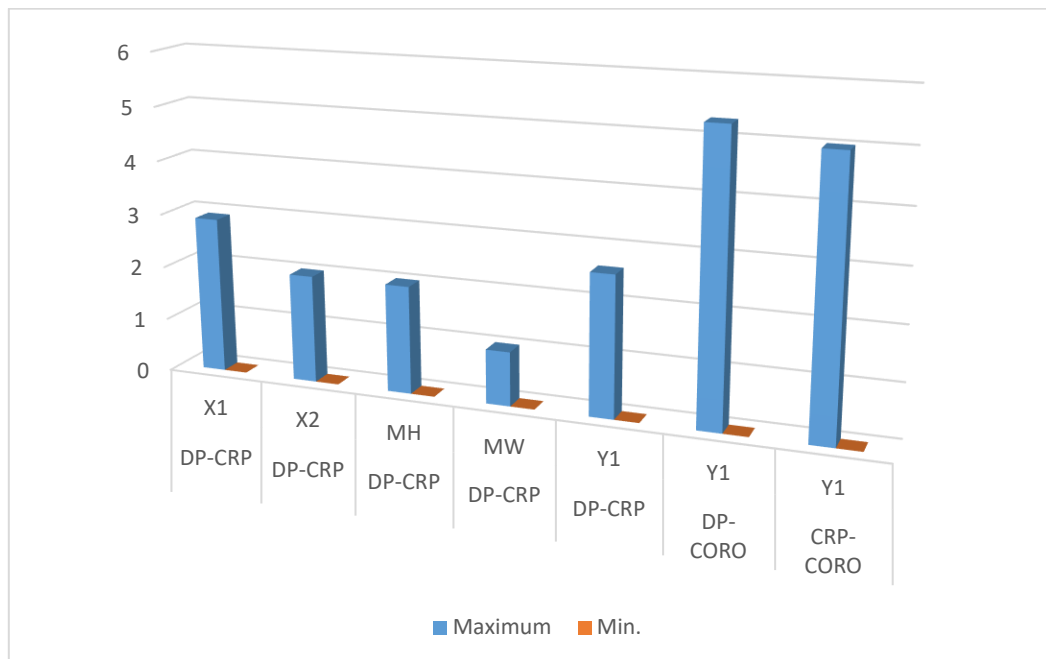


Chart 5.2. Maximum and minimum of variables (measurements) difference values



### 5.3.2 Ranges of differences calculated:

The ranges of differences (in millimetres) for each variable compared along with the number of patients showed these ranges are demonstrated in Table 5.10. The largest percentages of patients were in the  $[>0\text{ mm} - 0.5\text{ mm}]$  difference range in regard to X1, X2, MH, MW, Y1 (DP-CRP) variables, while Y1 (CRP-CORO) and Y1 (DP-CORO) variables showed the largest percentages in the  $[>1\text{ mm}]$  difference range. Chart 5.3 demonstrates these ranges.

Difference range	DP-CRP	DP-CRP	DP-CRP	DP-CRP	DP-CRP	DP-CORO	CRP-CORO
	X1	X2	MH	MW	Y1	Y1	Y1
0 mm	2 (7%)	1 (4%)	2 (7%)	1 (4%)	3 (11%)	2 (7%)	1 (4%)
>0 mm - 0.5mm	13 (46%)	12 (43%)	17 (61%)	21 (75%)	16 (57%)	5 (18%)	10 (36%)
0.6-1 mm	10 (36%)	5 (18%)	4 (14%)	6 (21%)	4 (14%)	2 (7%)	4 (14%)
>1 mm	3 (11%)	10 (36%)	5 (18%)	0 (0%)	5 (18%)	19 (68%)	13 (46%)
<b>Total</b>	<b>28</b>	<b>28</b>	<b>28</b>	<b>28</b>	<b>28</b>	<b>28</b>	<b>28</b>

\* The numerical value represents the number of patients showed the difference range in regard to the studied variable (also shown here with the percentage to the whole studied sample size).

\*Note: **DP-CRP** is the difference between values of the digital panorama to values of CBCT reformatted panorama. **DP-CORO** is the difference between values of the digital panorama to values of CBCT coronal view. **CRP-CORO** is the difference between values of CBCT reformatted panorama to values of CBCT coronal view.

Table 5.10. Ranges of variables (distances) difference

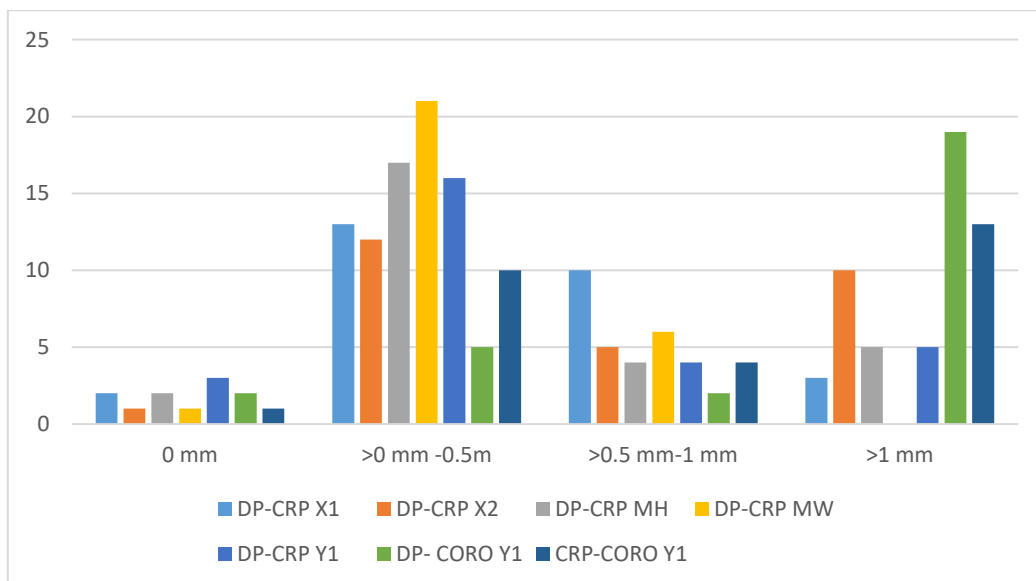


Chart 5.3. Ranges of differences for each variable studied

### 5.3.3 Comparison between the variables difference values:

As shown in Table 5.11 and Chart 5.4, the X1 (DP) values were less than the X1 (CRP) values in 19 patients, while the X1 (CRP) values were more in 7 patients and there was no difference in 2 patients. The variable X2 (CRP) values were larger than DP values in 20 patients. MH (DP) and MW (DP) values were less than those MH (CRP) and MW (CRP) in 21 and 17 patients, respectively. Values of Y1 were larger in the DP view compared with the CRP and CORO views for the same variable. In addition, the Y1 studied on CRP views were larger than those studied on CBCT coronal views.

Values	DP-CRP	DP-CRP	DP-CRP	DP-CRP	DP-CRP	DP- CORO	CRP-CORO
	X1	X2	MH	MW	Y1	Y1	Y1
DP < CRP or CORO OR CRP<CORO	19	7	21	17	3	0	5
DP > CRP Or CORO OR CRP>CORO	7	20	5	10	22	26	22
No difference	2	1	2	1	3	2	1
Total	28	28	28	28	28	28	28

\*Note: **DP-CRP** is the difference between values of the digital panorama to values of CBCT reformatted panorama. **DP-CORO** is the difference between values of the digital panorama to values of CBCT coronal view. **CRP-CORO** is the difference between values of CBCT reformatted panorama to values of CBCT coronal view.

\*the numerical value represents the number of patients showed the designated condition.

Table 5.11. Numbers of patients showed (more or less) values compared between DP, CRP, and CORO views

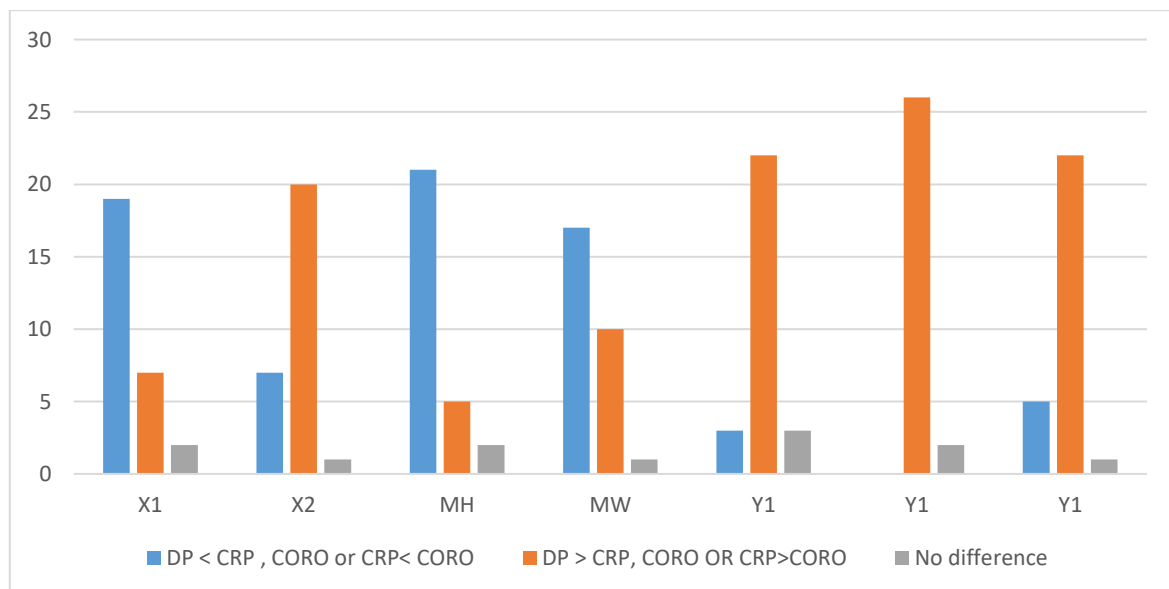


Chart 5.4. Numbers of patients showed (more or less) values compared between DP, CRP, CORO views

#### 5.4 Inter-observer agreement analysis

Intra-class correlation coefficient (ICC) was used to analyse the level of agreement between the two observers in this study. The re-analysis of five patients (randomly selected and excluding the outliers) was carried out blindly by another oral and maxillofacial radiologist and according to the designated methodology. The “2-way mixed-effects model” ICC’s form was chosen as the previously mentioned observers are the only observers of interest.

Table 5.12 summarizes the ICC, confidence interval and level of agreement.

<b>Measurement</b>	<b>ICC</b>	<b>CI (95% confidence interval)</b>	<b>Agreement</b>
<b>X1DP</b>	0.997	0.975 and 0.999	Excellent
<b>X2DP</b>	0.981	0.830 and 0.997	Excellent
<b>Y1DP</b>	0.985	0.863 and 0.998	Excellent
<b>MHDP</b>	0.938	0.593 and 0.993	Excellent
<b>MWDP</b>	0.997	0.974 and 0.999	Excellent
<b>X1CRP</b>	0.999	0.999 and 0.999	Excellent
<b>X2CRP</b>	0.988	0.893 and 0.999	Excellent
<b>Y1CRP</b>	0.997	0.972 and 0.999	Excellent
<b>MHCRP</b>	0.938	0.535 and 0.993	Excellent
<b>MWCRP</b>	0.956	0.645 and 0.995	Excellent
<b>Y1CORO</b>	0.994	0.941 and 0.999	Excellent

*\*Values less than 0.5 are indicative of poor reliability, values between 0.5 and 0.75 indicate moderate reliability, values between 0.75 and 0.9 indicate good reliability, and values greater than 0.90 indicate excellent reliability.*

Table 5.12. Intra-class correlation coefficient and level of agreement for inter-observers

All the studied variables (distances) indicated “excellent” agreement between the two observers with ICC ranging from [0.938 -0.999]. The confidence interval was narrow in most studied variables except in MHDP, MHCRP, and MWCRP. Chart 5.5 shows the dot plot of inter-observer agreement using digital panorama and CBCT.

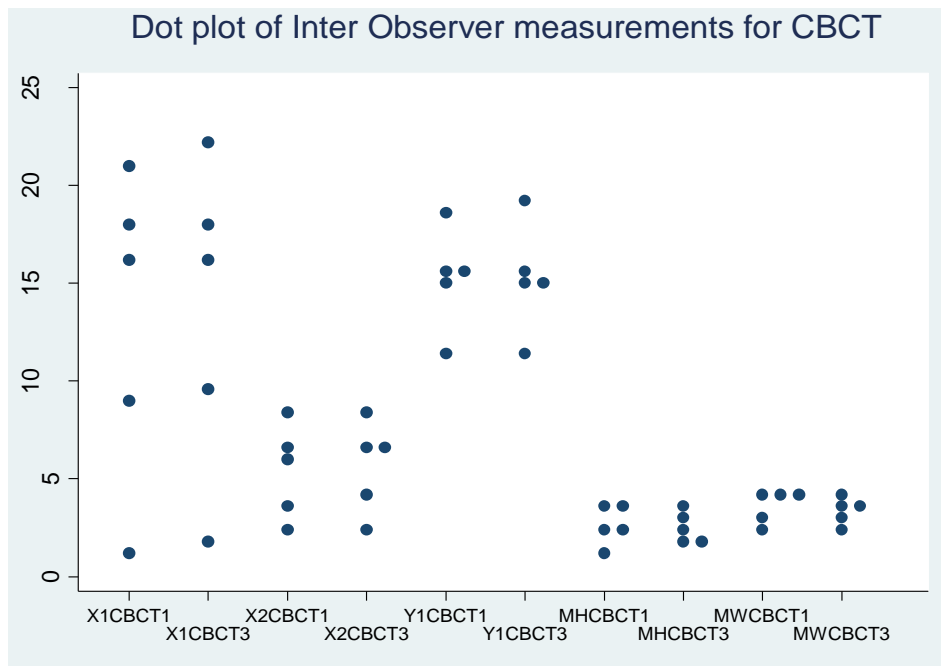
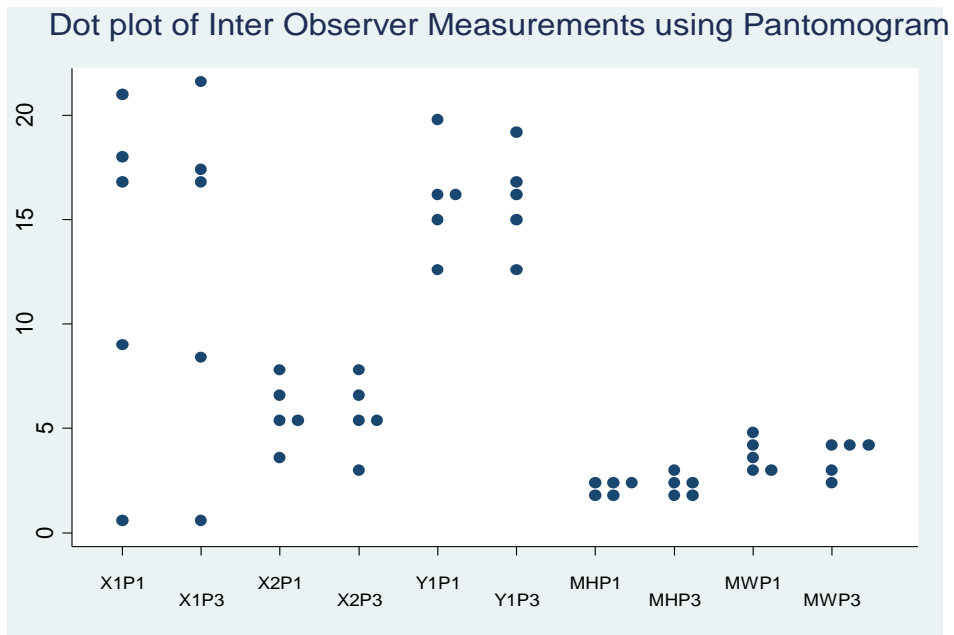


Chart 5.5. Dot plot of inter-observer measurements using digital panorama (DP) and CBCT

### 5.5 Intra-observer agreement analysis

Intra-class correlation coefficient (ICC) was used to analyse the level of agreement between the results obtained from the primary observer himself. The re-analysis of ten patients (randomly selected and excluding the outliers) was carried out blindly. The “2-way mixed-effects model” ICC’s form was chosen as the previously mentioned observers are the only observers of interest.

Table 5.13 summarizes the ICC, confidence interval and level of agreement.

<b>Measurement</b>	<b>ICC</b>	<b>CI (95% confidence interval)</b>	<b>Agreement</b>
<b>X1DP</b>	0.99	[0.997: 0.999]	Excellent
<b>X2DP</b>	0.975	[0.901: 0.993]	Excellent
<b>Y1DP</b>	0.997	[0.909: 0.994]	Excellent
<b>MHDP</b>	0.921	[0.716: 0.834]	Excellent
<b>MWDP</b>	0.89	[0.609:0.970]	Good
<b>X1CRP</b>	0.99	[0.977: 0.998]	Excellent
<b>X2CRP</b>	0.90	[0.657: 0.974]	Good
<b>Y1CRP</b>	0.90	[0.652: 0.974]	Good
<b>MHCRP</b>	0.903	[0.661: 0.975]	Excellent
<b>MWCRP</b>	0.864	[0.546: 0.964]	Good
<b>Y1CORO</b>	0.995	[0.982: 0.999]	Excellent

\*Values less than 0.5 are indicative of poor reliability, values between 0.5 and 0.75 indicate moderate reliability, values between 0.75 and 0.9 indicate good reliability, and values greater than 0.90 indicate excellent reliability.

Table 5.13. Intra-class correlation coefficient and level of agreement for intra-observers

The studied variables (distances) indicated “excellent” intra-observer agreement with ICC ranging from [0.864-0.997] except in MWDP, X2CRP, Y1CRP, and MWCRP, which indicated “good” reliability. The confidence interval was wide in X2CRP, Y1CRP, MHCRP, MWDP, and MWCRP variables, never the less, their ICC values were high. Chart 5.6 shows the dot plot of inter-observer agreement using digital panorama and CBCT, respectively.

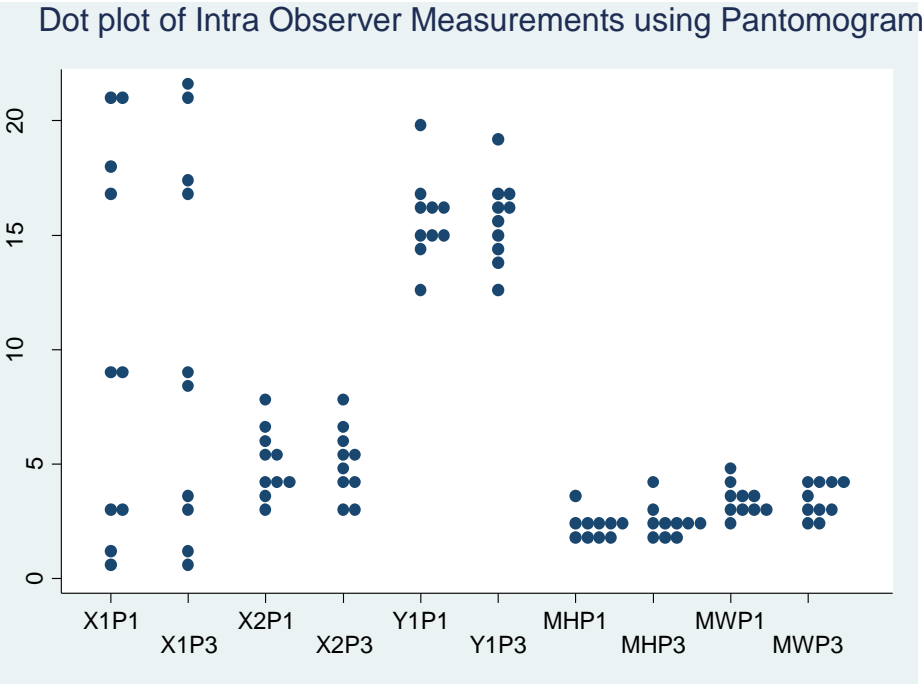
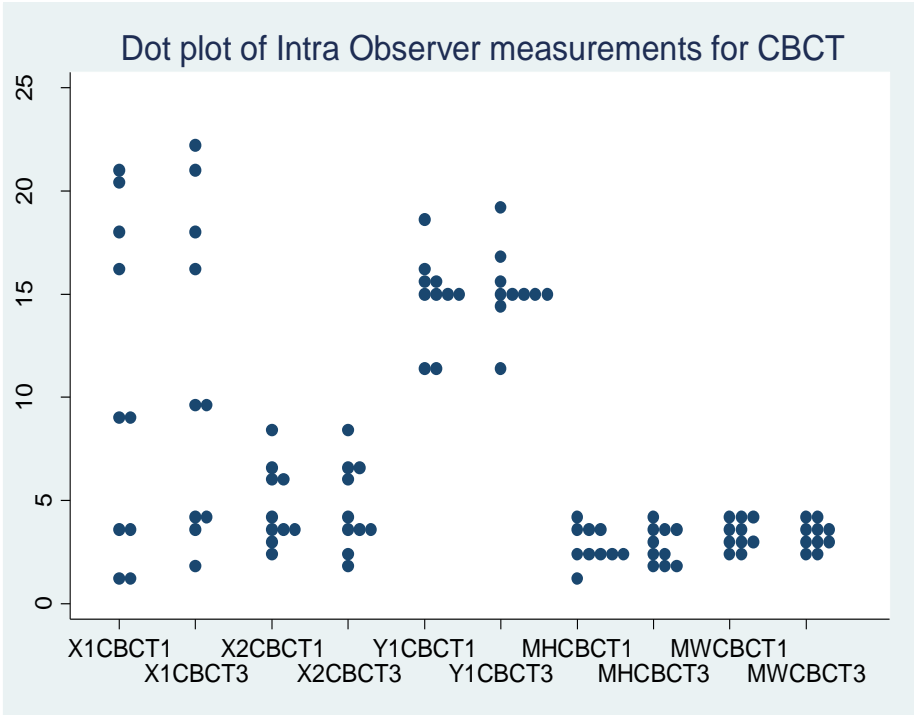


Chart 5.6. Dot plot of inter-observer measurements using digital panorama (DP) and CBCT

## Chapter 6 : DISCUSSION

### 6.1 Results discussion:

The results from this study showed that all the p-values for the studied variables (distances) indicated statistical significance ( $p$ -value  $< 0.05$ ). This provides convincing evidence to reject the null hypothesis (Mean difference = 0). This study showed that there was a difference in measurements between CRP and DP views of the tested variables (X1, X2, MH, MW, and Y1). However, the ranges of error were inconstant concerning the tested variables.

The study was not carried out to investigate the clinical accuracy of any radiographic modality tested, but rather to ascertain if there is a discrepancy in the measurements of MF obtained from the DP and CRP views. To the best of the author's knowledge, the studies conducted to investigate the CBCT reformatted panoramic views are scant in the literature and a comparison between the CRP view and DP view for the mental foramen position and measurements was not performed before.

Different studies mentioned as a requirement that the clinically acceptable error obtained from different radiographic modalities to be less than 1mm for the purposes of implant placement (Ganguly *et al.*, 2011; Nikneshan *et al.*, 2014). However, the clinically acceptable radiographic error may be based on the clinical experience, the sensitivity of the procedure intended, and on the vicinity of vital structures. This study adopted the same proposal by Ganguly *et al.*, (2011) and Nikneshan *et al.*, (2014), that any difference range less than 1mm in all directions is still clinically accepted, taking in consideration any human error that might have occurred during the analysis.

#### 6.1.1 Distance X1

The mean distance of X1 (CBCT reconstructed panorama (CRP)) is shown to be larger than the mean distance of X1 (Digital panorama (DP)) by 0.34mm ( $P=0.0412$ ). The X1 value was larger in CRP than calculated on DP in 19 patients (although this calculation includes small negligible differences, i.e. 0.1mm values into account). Only 7% of the sample showed no measurement difference, 46% of the X1 differences were in the range of [ $>0-0.5$ mm], 36% were in [0.6-1mm] range, and 11% were more 1 mm. This indicates that in this study, the X1 variable error between CRP and DP is still clinically acceptable as the mean measurements difference between the two studied modalities was 0.34mm and was less than 1mm. It is also noticed that the majority of measurements studied in patients have differences less than 1 mm and only 11% (3/28 patients) showed a difference more than 1mm.

The statistical significance of research results may not always coincide with the clinical significance of the results and vice versa. Thus, the statistical significance of a research does not indeed emphasize a clinical importance, but rather emphasizes the reliability of the obtained results from the designated analysis (Ranganathan *et al.*, 2015).

The possible measurement discrepancy due to inevitable human error might also contribute to some of the minor error ranges obtained. However, in some cases, the ranges obtained over 1mm were repeated separately and indicated a horizontal discrepancy that could be due to the radiographic inherited distortion in any of the studied views. Such panoramic radiograph distortions were mentioned in the academic literature (Monsour & Dudhia (2008); Dhillon *et al.*, 2012). The faulty head positions were mentioned to contribute to the dimensional discrepancy found in some panoramic radiographs, especially in the anterior jaw segments (Stramotas *et al.*, 2002; Zarch *et al.*, 2011). Furthermore, the CRP showed to have various discrepancy in measurements when generated at different horizontal planes (Alkhader *et al.*, 2016).

### **6.1.2 Distance X2**

The mean distance of X2 (CBCT reconstructed panorama (**CRP**)) is shown to be smaller than the mean distance of X2 (Digital panorama (**DP**)) by 0.52mm ( $P=0.0023$ ). The X2 value was larger in DP than calculated on CRP in 20 patients (although this calculation includes the small negligible differences values i.e. 0.1mm into account). Only 4% of the sample showed no difference, 43% of the X2 difference was in the range of [ $>0-0.5$ mm], 18% [0.6-1mm] and 36% were more 1 mm. The percentage of patients that showed errors of more than 1mm is 36%, which is considered to be high compared with the other percentages of the same variable. Even though the mean difference of X2 was larger than the mean difference of X1 in tested radiographic modalities, the X2 distance mean difference was still less than 1 mm (0.52mm) and thus still clinically accepted.

### **6.1.3 Distance MH**

The mean distance of MH (CBCT reconstructed panorama (**CRP**)) is shown to be larger than the mean distance of MH (Digital panorama (**DP**)) by 0.39mm ( $P=0.0018$ ). The MH value was larger in CRP than calculated on DP in 21 patients (although this calculation includes the small negligible differences values i.e. 0.1mm into account). Only 7% showed no difference, 61% of the MH difference was in the range of [ $>0- 0.5$ mm], 14% [0.6-1mm] and 18% were more 1 mm. This indicates that the MH variable error between CRP and DP is still clinically



acceptable as the mean measurements difference between the two studied modalities was less than 1mm (0.34mm). Most studied patients (82%) had differences of less than 1 mm and only 18% showed higher ranges; this percentage is postulated to be due to a possible vertical magnification discrepancy in one of the views, as well as different radiographic presentations of certain MF structures as observed and shown in section 6.5.

#### **6.1.4 Distance MW**

The mean distance of MW (CBCT reconstructed panorama (**CRP**)) is shown to be larger than the mean distance of MW (Digital panorama (**DP**)) by 0.16mm ( $P=0.0456$ ). The MH value was larger in CRP than calculated on DP in 17 patients (although this calculation includes the small negligible differences values i.e. 0.1mm into account). 4% of the sample showed no difference, 75% of the MW differences were in the range of  $[> 0 - 0.5\text{mm}]$ , 21%  $[0.6-1\text{mm}]$  and 0% were more 1 mm. These percentages revealed that the entire studies sample displayed differences of less than 1 mm. The mean of MW (DP-CRP) difference was 0.16mm and thus it is still clinically acceptable ( $<1\text{mm}$ ).

Von Arx *et al.*, (2013) conducted a retrospective analysis on CBCT volumes to study the mental foramen anatomy and dimensions. The authors found that the MF height ranged from 1.8 to 5.1mm and the length from 1.8 to 5.5mm. In this study, the height ranged between  $[1.5 - 4.9\text{mm}]$  on the CRP views and between  $[1.8 - 4.1\text{mm}]$  on the DP views. The mental width was between  $[2.5-5.2\text{mm}]$  on the CRP views and between  $[2.2-5.6\text{mm}]$  on the DP views. Von Arx *et al.*, (2013) also studied the position of the MF on CBCT (sagittal view) with respect to the closest root, the mean distance was of 5.0 mm [range, 0.3–9.8 mm]. In the current study however, the methodology and aims of measurements were different and thus these horizontal distances cannot be compared due to different measurement methodologies and references taken.

#### **6.1.5 Distance Y1**

The analysis of the vertical distance (Y1) difference revealed from the three radiographic views (**DP**, **CRP**, and **CORO**) showed a statistical significance ( $p<0.000$ ). Also, the statistical analysis of the difference between Y1 (DP-CRP), Y1 (DP-CORO), and Y1 (CRP-CORO) was carried out individually and showed that the mean difference between CBCT coronal view (**CORO**) and digital panorama (**DP**) was the greatest (mean difference = 1.59mm,  $p<0.05$ ). The mean difference between CBCT reformed panorama (**CRP**) and CBCT coronal view (**CORO**) views demonstrated a mean difference of 1.06mm ( $p<0.05$ ) and the smallest mean

difference was demonstrated between digital panorama (**DP**) and CBCT reformed panorama (**CRP**), mean difference = 0.54mm ( $p < 0.05$ ). From the above-mentioned mean differences, it can be concluded that the radiographic measurement errors of the vertical position of the mental foramen Y1 between DP-CORO and CRP-CORO are clinically unacceptable as the mean differences are more than 1 mm (mean difference = 1.59mm, 1.06mm, respectively). It was noticed that the Y1 (DP-CRP) differences were not significant as the mean distance difference was 0.54 mm (still clinically acceptable), moreover only 18% of patients showed differences of more than 1mm. By contrast, the Y1 (DP-CORO) and Y1 (CRP-CORO) showed higher percentages of patients with differences of more than 1 mm (68%, 46%, respectively).

This study shows that the vertical dimension Y1 was noticeably inconsistent between the panoramic views (CRP, DP) compared to the coronal view (CORO). Although the possible panoramic inherent image distortion might play a role in the Y1 value differences in certain cases, these differences may be attributed to the identification of the MFs' actual superior borders in the coronal view at a higher level of what was identified on the panoramic views (CRP, DP). The actual MF's superior and inferior borders (borders seen from the coronal view) are precisely demarcated on that view compared with the other views. As noticed, such a different marginal presentation between the modalities led to most of the large differences in the Y1 values.

It was also noticed that the degree of angulation of the mental canal emerging to the outer cortex noticeably affected the range of measurement differences obtained from panoramic and coronal views. Additionally, it was found that the cases in which mental canals emerged in a 90 degrees emergence profile (did not adopt a sloped direction to the lateral surface of the mandible), the differences between Y1 (DP, CRP, and CORO) values were markedly decreased.

## **6.2 Effects of anatomical variations of the mental foramen on the linear measurements**

It is fundamental for the safety of the vital structures to approach the mental foramen as a canal and not as a radiographic point. The mental foramen as an aperture is the lateral end of the mental canal that opens on the lateral surface of the mandible (Al-Mahalawy *et al.*, 2017; Phillips *et al.*, 1990).

According to observations, the MF did not adopt a regularly rounded structure in all the cases studied on DP and CRP views. It is essential to respect the variation of the MF's structure in terms of anatomical shape, emergence pattern and direction, and the variation of the bone's

density overlying the mental neurovascular bundle. The emergence pattern of the mental canal could adopt several directions including superior, Posterosuperiorly, labial, anterior, and posterior emergence from the mandibular cortex (Fabian 2007).

All these factors may alter the radiographic presentation of the MF on the radiographs. Any irregularities that may be found on the borders and surfaces of the mental canal might result in the superimposition of these structures on the 2-dimensional radiographic foramen's architecture. This may lead in some cases to false positive identification of one of the MF's borders.

As noticed, these factors might not be studied efficiently in a 2-dimensional view as the MF is a multidimensional structure. These limitations should be respected during the radiographic analysis of the MF.

Since the precise identification of the mental foramen borders forms the foundation of subsequent measurements, the precise location and visualization of these margins on the selected image become vital. However, the ability to accurately define the MF's border on different radiographic views (DP,CRP) was not consistent in this study. Such a variation could lead to a false identification of the exact limits of MF's structure and as a consequence may lead to over or underestimation of measurements calculated based upon these borders. Furthermore, even if the MF's borders are clearly demarcated in one panoramic view, this may not represent the actual borders seen on another perpendicular view.

The following cases showed different types of variations that led to the false identification of the MF.

### Case 6.1

---

The MF was identified inferior to the tooth #45 on the CRP view. The CBCT views (reformatted panoramic, axial, and oblique coronal) was noticed to show a decorrelated presentation of the MF's borders in these different planes (navigation in different planes via the crosshair provided in the software).

The oblique coronal view CORO (Figure 6.1, A) presented the opening of the mental canal clearly, with the horizontal plane's crosshair (yellow line) was set at the top of the mental canal's lower border. Surprisingly, the corresponding horizontal crosshair in the CRP view was automatically pointed at the level of the upper border of MF (Figure 6.1, B). The actual MF opened at a point higher than the MF visible on the CBCT panoramic view (Figures 6.1, A and B).

It was noticed that the actual foramen has smaller dimensions and was not recognizable on the panoramic views (was only recognizable on the coronal view). The assumed reason behind the presence of such false foramen inferiorly to and mimicking the actual MF may be due to the lower density of bone encountered in the area just inferior to the actual foramen. This low bone density was due to the occupation of the inferior dental canal as noticed on the axial views (Figure 6.2, B), which occupies the buccal side to give off the mental neurovascular bundle which exits from that foramen (Mraiwa *et al.*, 2003). On the other hand, the actual MF was not apparent on the CRP view; This is most probably due to the specific anatomical characteristics in that case, in which the density of bone (that the x-ray beam has to pass through) just above the level of the lower border of the actual mental canal was adequate for the penetrating X-rays to be highly attenuated and superimposing the actual opening (Figure 6.1, A).

Concerning the axial view assessment, the vertical crosshair (blue line) was set at the mesial border of the mental foramen and the horizontal hair cross (yellow horizontal line) was set in the middle of the MF seen on the CRP view (Figure 6.2, A). The corresponding axial view (Figure 6.2, B), clearly shows that at that vertical level, there was no evidence of any opening on the outer cortex as it is clearly visible on the CRP view for the same selected levels (Figure 6.2, A). At a higher axial level, an accessory foramen (AMF) that was not evident on DP or CRP views was found at a further distance distally from the distal border of the main MF seen on the CRP view (marked by the blue line on the axial view) (Figure 6.3). Further higher vertical navigation in the axial view revealed an inclusion of bone (concavity in the bone), which represents the main foramen opening that is clearly recognizable on the coronal view but not on the corresponding CRP view at the same vertical level (Figure 6.4).

The difference between Y1(DP) and Y1(CRP) was negligible (0.3mm), while the differences between Y1 (DP) and Y1 (CORO) =1.2mm and Y1 (CRP) and Y1 (CORO) = 0.9mm. These measurements indicate that the DP and CRP presented similar anatomical pictures.

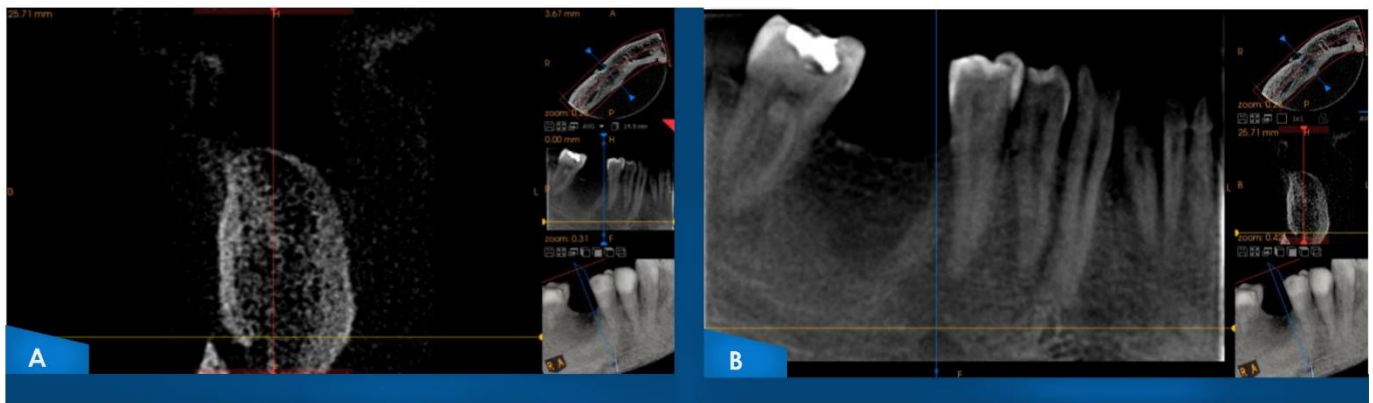

Figure 6.1. (A), an oblique coronal view (CORO), the horizontal plane crosshair (yellow line) was set at the lower border of the mental canal opening, the correspondent CRP view (Figure B) in contrast was pointed at the upper border of the identified MF in the same view.

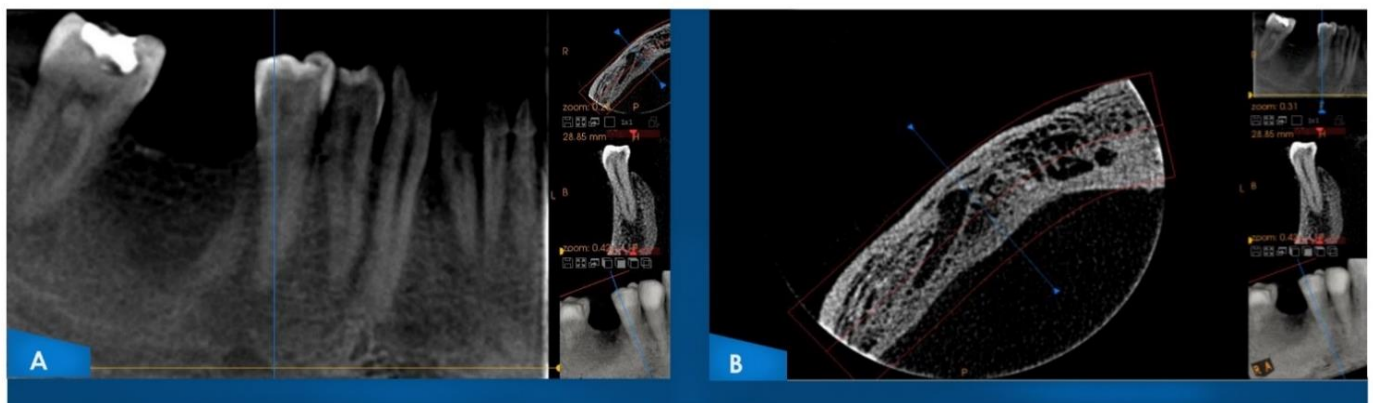


Figure 6.2. (A), CRP view; the coronal plane crosshair (Blue vertical line) was set at the mesial border of the mental foramen; the axial crosshair (Yellow horizontal line) was roughly set at the middle of MF. (B), the corresponding CBCT axial view; as seen at this axial slice, there was no evidence of any opening on the outer mandibular cortex compared with the CRP view at the same horizontal level.

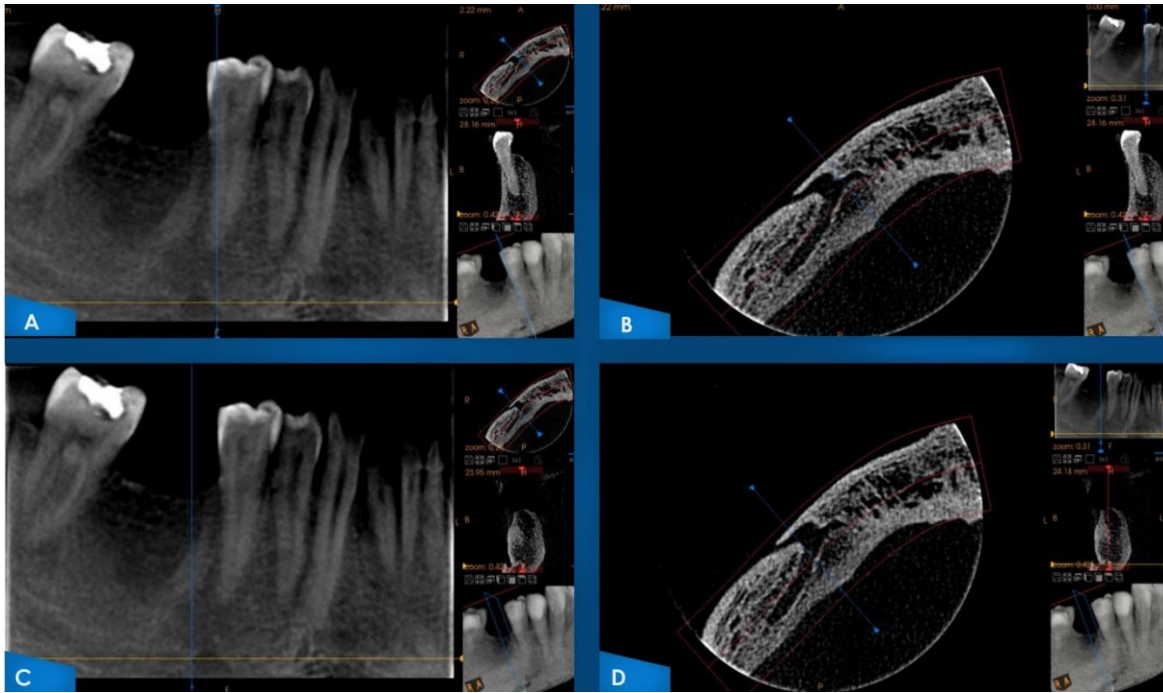


Figure 6.3. (A) CRP view; the vertical crosshair (blue line) was set at the mesial border of the MF. (B) The correspondent axial view, as shown there was no evidence of any opening on the outer mandibular cortex at these vertical and horizontal levels. (C) CRP view, the vertical crosshair (blue line) was set at the distal border of the MF; the correspondent axial view (D) also did not show any evidence of any opening on the outer mandibular cortex.

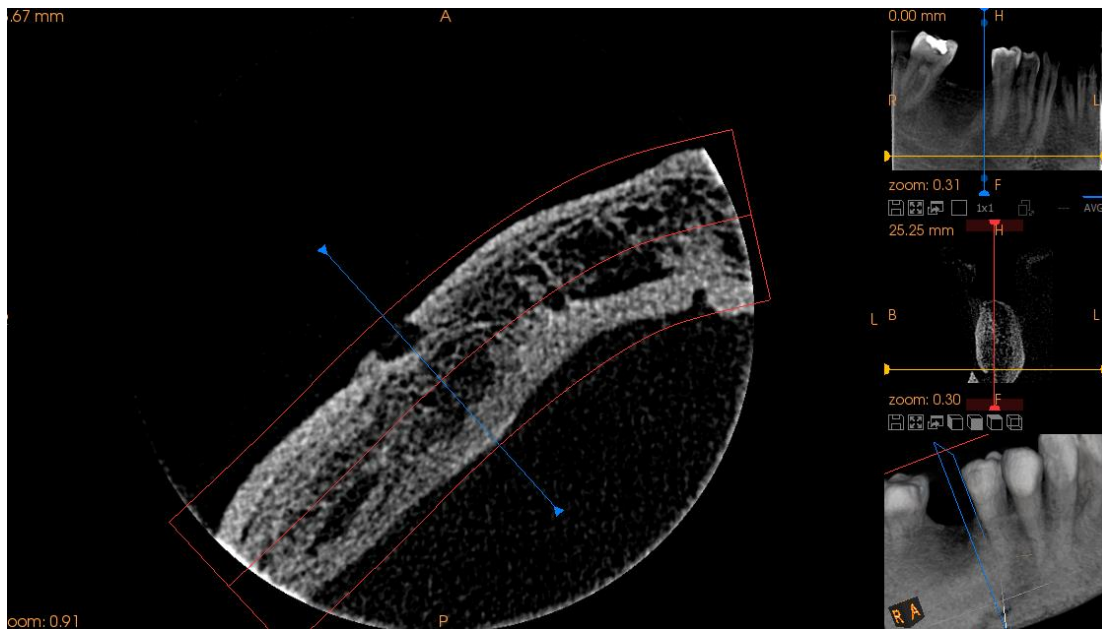


Figure 6.4. CBCT axial view (The horizontal axial level was selected at a point higher than the MF's upper border seen on CRP view). This bony inclusion seen in the axial view represented the actual opening of the MF (please note the corresponding coronal view in the same figure).

## Case 6.2

---

MF was identified in CRP and DP views (Figure 6.5, A and B). It was noticed that the discrepancy between the resultant difference values of Y1 (DP-CORO) and Y1 (CRP-CORO) was the highest of all the tested variables (5mm, 5.3mm, respectively) (Figure 6.7, A-C). Navigation through the other CBCT views was done afterward and showed that the identified MF on CRP, DP views (even though it was well-corticated and clearly apparent) was not the actual opening of the canal. The actual opening of the mental canal was situated at a point higher than the previously identified one (Figures 6.6, A and B). The small and more hypo-dense area visible just above the identified MF seen on CRP and DP represented the actual opening. This hypo-density was more prominent and suspicious on the CRP view. At the time of the analysis, it was recognized as a bone marrow variation; especially that MF was well-demarcated, well-defined and clearly traceable on both views. One of the postulated reasons beyond this variation is due to the regular loss of bone density in that area due to the occupation part of ID canal. Such a loss of bone density was adequate to regularly attenuate the x-ray beam and mimicking an MF architecture. It was assumed from the observations in the current study, that the sloped emergence patterns of the mental canal might readily affect the resultant radiographic presentation and could superimpose the site of actual opening (see section 6.3 for further details).

This type of variations in the presentation of MF on the radiographs constitutes a real hazard on the safety of the mental nerve and the associated vital structures. The mental canal was ascending about 3 mm from the root tip of 45#, this track was not readily visible in either CRP or DP views and was only recognized in the coronal view for the same sections examined. Any surgical procedures that would take place in this anatomical region may result in a severe damage, as the dimensions calculated on CRP and DP were overestimated.

An accessory foramen (AMF) was also noted only on the axial view. The AMF opened at a farther distance distally to the MF seen on the CRP view (Figure 6.8). Such a finding was not noticed on the CRP nor DP views. The bone thickness over the peripheries of the accessory canal's path might be thick enough to superimpose and hide the accessory canal on both panoramic views.



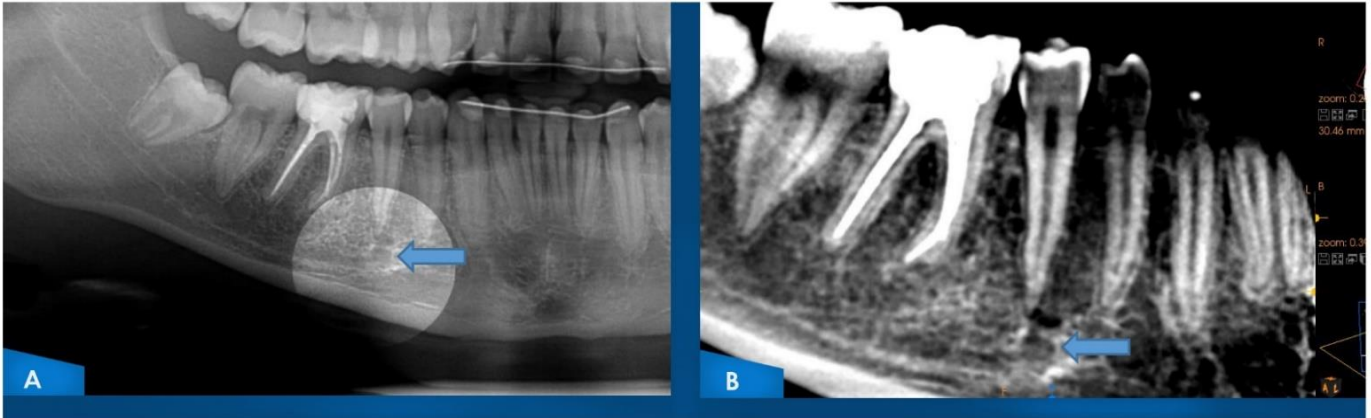


Figure 6.5. (A) DP view, (B) CRP view. Both views demonstrate the identified mental foramen (blue solid arrow); the MF is clearly visible and well-demarcated.

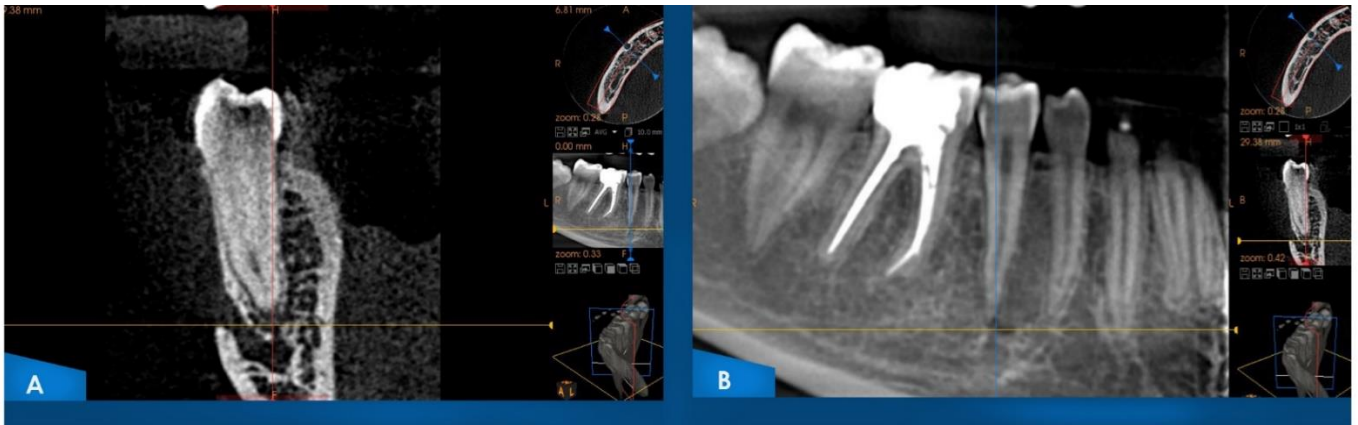


Figure 6.6. (A) An oblique coronal view; the horizontal crosshair (Yellow line) was set at the lower edge of the mental canal opening. (B) The corresponding CRP view shows the horizontal crosshair situated at a higher level from the upper margin of the MF visible on the same view.



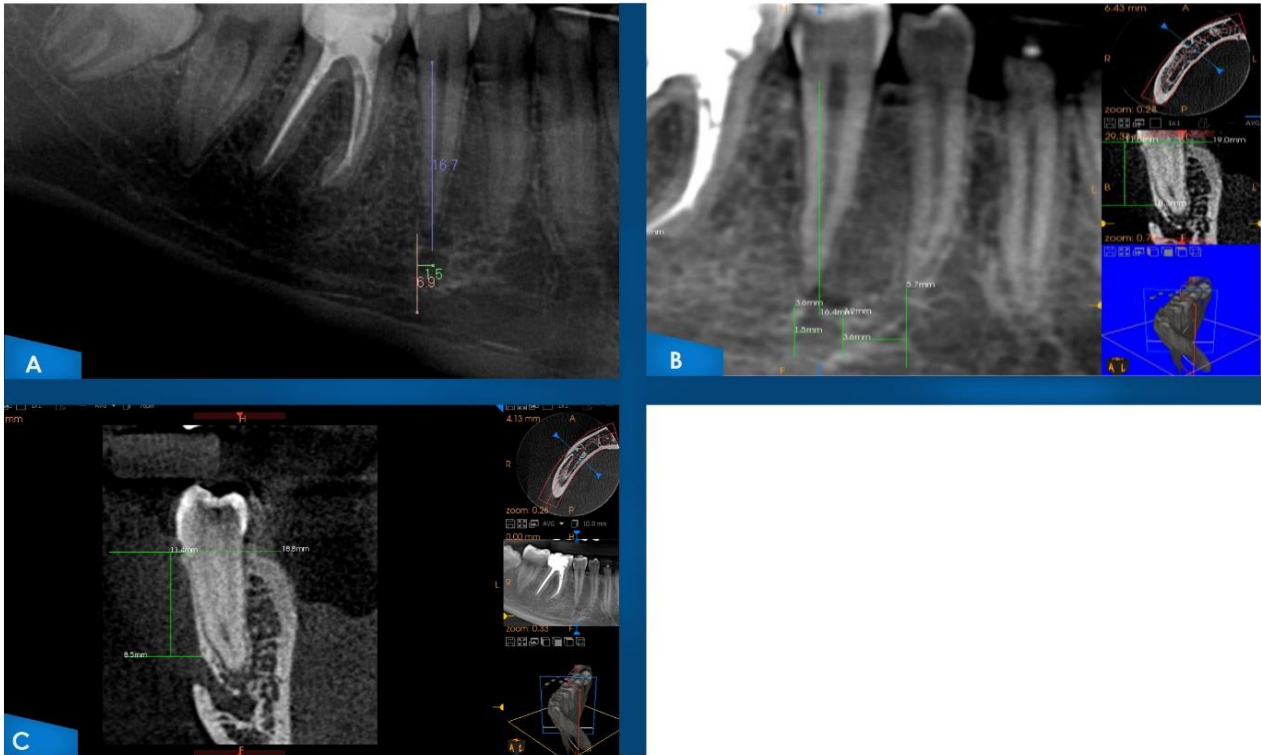


Figure 6.7. Y1 measurements were carried out in DP view (A), CRP view (B), and CORO view (C). Y1DP1=16.7 mm, Y1CRP1=16.4mm, Y1CORO1=11.4mm.

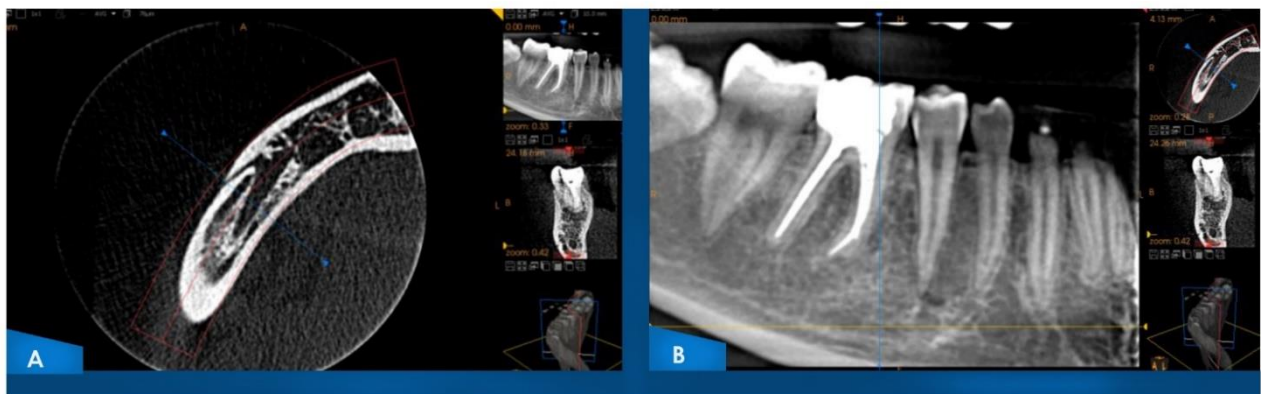

Figure 6.8. (A) Axial view; AMF was visible and opens far distally from the main MF. (B) The corresponding CRP view shows the crosshair pointed far distally to the main MF seen on the same view.

### **6.3 The effect of the vertical slope of mental canal on the MF's radiographic presentation**

One of the central facets of this study was the vertical dimension of the MF measured on two panoramic views compared with the coronal view. It was noticed that assessing the vertical position of the MF on panoramic views (DP or CRP) has its own risks and limitations. This was due to the fact that the mental foramen is a three-dimensional structure that should be examined and handled on at least two perpendicular views. Any missed information could lead to serious consequences. The injuries of the mental neurovascular structure can lead to various types of neural tissue dysfunction ranging from paresthesia, hypoesthesia until complete loss of sensation (anesthesia) of the tissues supplied by this neural bundle (Greenstein and Tarnow, 2006; Al-Mahalawy et al., 2017).

The mental canal anatomy could have variable presentations and may emerge in different directions. From what was noticed, these variations may not be detected on only one view especially the lateral view of the mandible as in CRP and DP views. In the cases which the mental canal adopted an ascending pathway to the outer cortex, it was found that the Y1 values showed a significant difference between panoramic views compared with the coronal views. Although the differences found in Y1 (DP-CRP) were not significant, the differences in Y1 (CRP-CORO) and Y1 (DP-CORO) were remarkably noticed. The coronal views for those cases showed much less Y1 value (the value of Y1 was over estimated on CRP, DP views).

One of the reasons postulated is that the bone density that the x-ray beam has to pass through will gradually decrease as you move from coronal to apical direction. However, this gradual density was thick enough to attenuate the x-ray beams crossing the structure at these points.

In addition to the above mentioned case 6.2 (Section 6.2), cases 6.3, 6.4, and 6.5 illustrate the effects of canal emergence directions on the measurements.

### Case 6.3

The vertical distance Y1 showed a value of 19.6 mm measured on the DP view, 18.5 mm on the CRP view, and 16.9 mm on the CORO view (Figure 6.9).

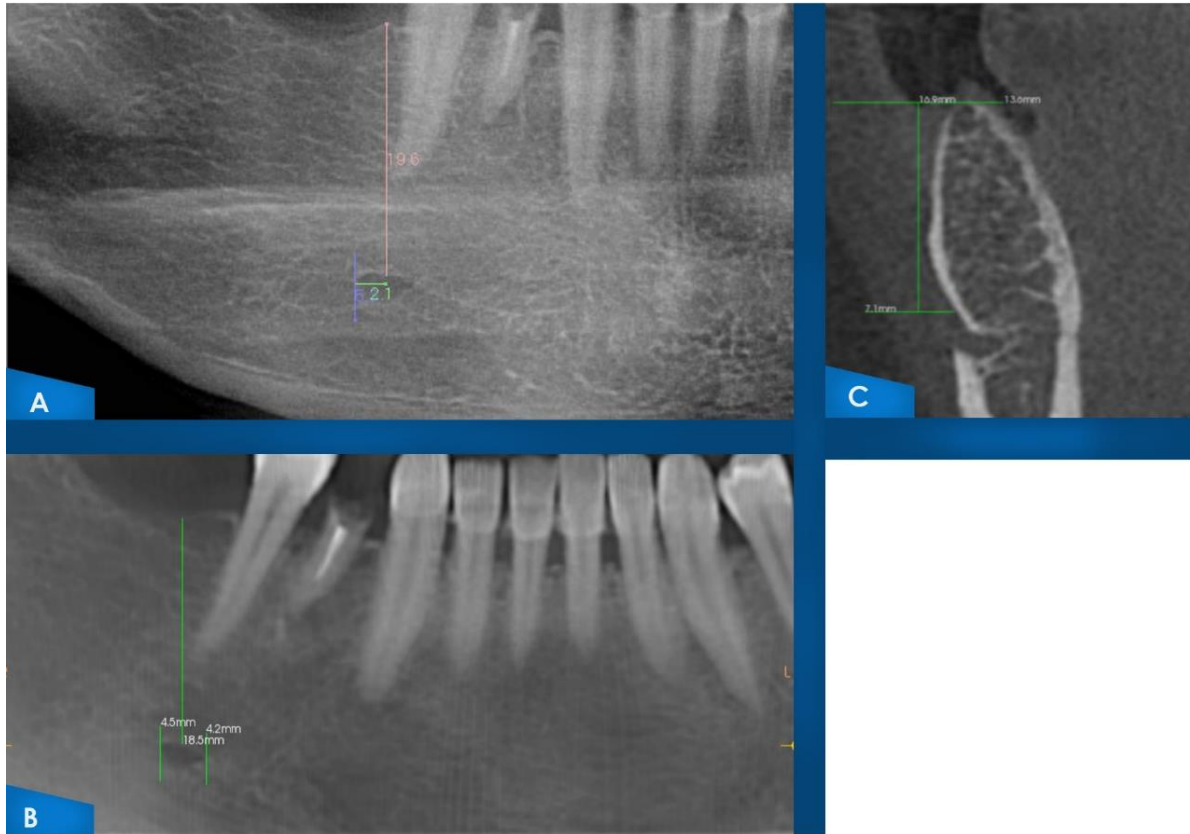


Figure 6.9. (A) A DP view shows measurements of Y1. (B) A CRP view shows the calculation of Y1 value. (C) The correspondent oblique coronal view for the same Y1 slice level measured on CRP view.

## Case 6.4

The vertical distance Y1 showed a value of 12.7 mm measured on the DP view, 11.6 mm on the CRP view, and 8.6 mm on the CORO view (Figure 6.10).

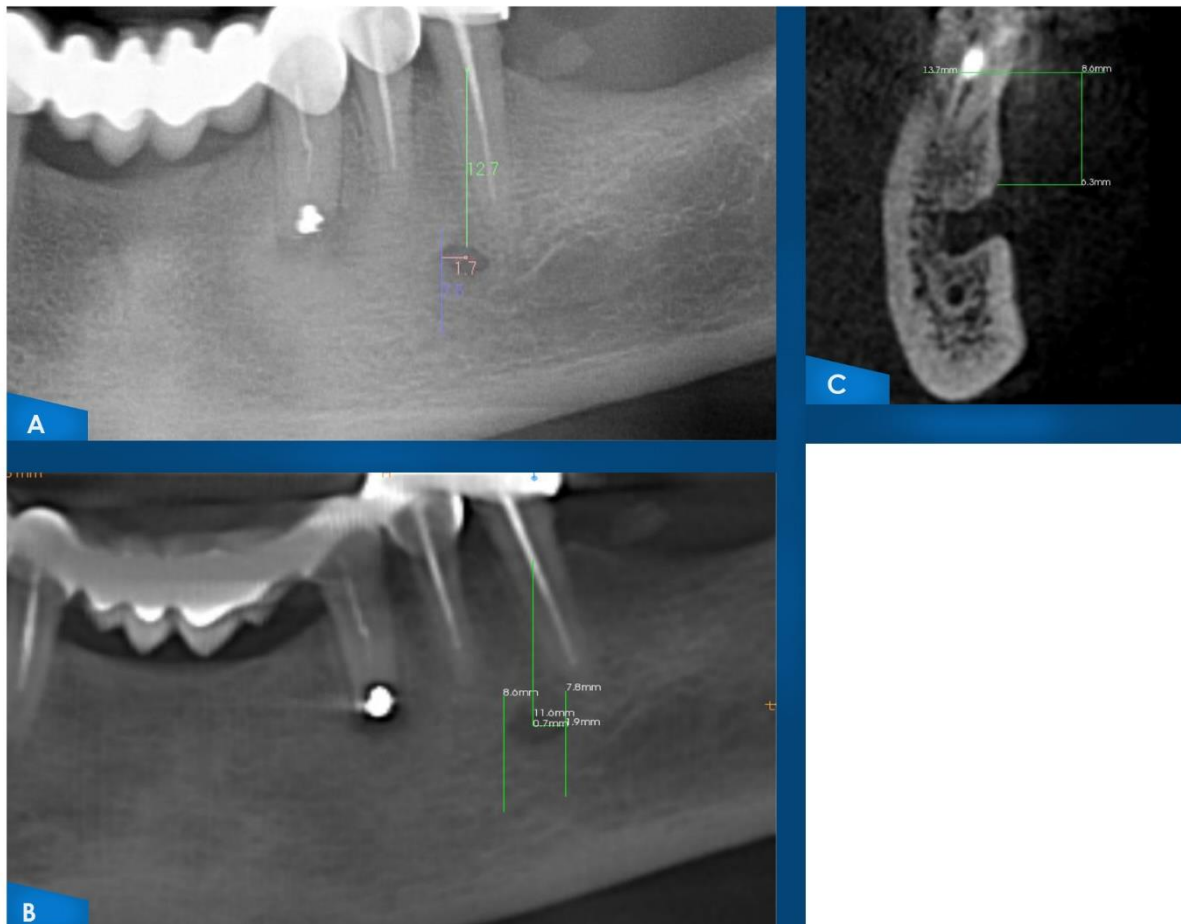


Figure 6.10. (A) A DP view shows measurements of Y1. (B) A CRP view shows the calculation of Y1 value. (C) The correspondent oblique coronal view for the same Y1 slice level measured on CRP view.

## Case 6.5

The vertical distance Y1 showed a value of 14.4 mm measured on the DP view, 14.4 mm on the CRP view, and 12.3 mm on the CORO view (Figure 6.11).

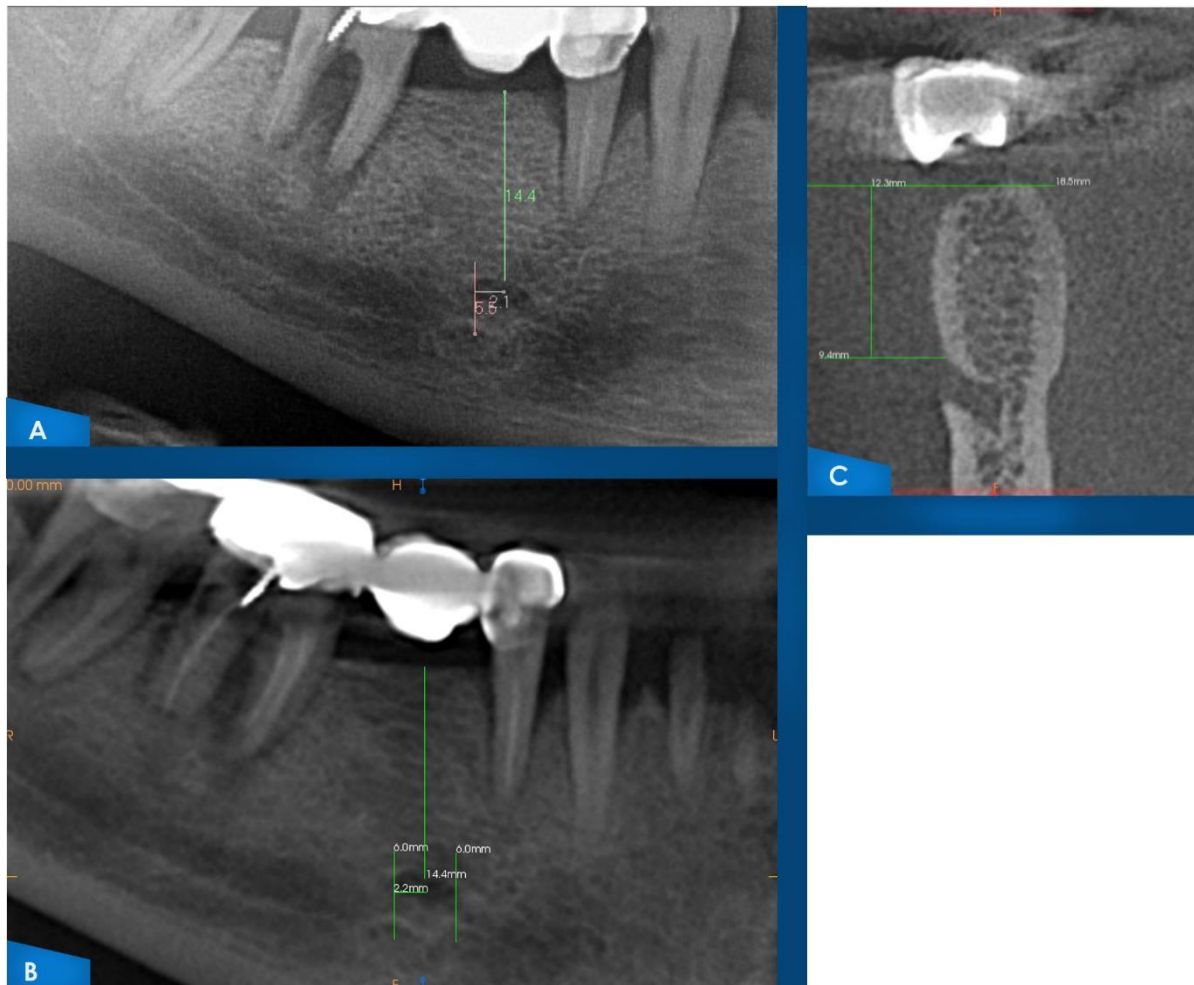


Figure 6.11. (A) A DP view shows measurements of Y1. (B) A CRP view shows the calculation of Y1 value. (C) The correspondent oblique coronal view for the same Y1 slice level measured on CRP view.

## 6.4 The effects of the horizontal mental canal directions on the MF's radiographic presentation

### Case 6.6

The mental canal was running in a distal direction horizontally as the navigation through the axial view revealed. On the same axial view, the coronal crosshair (in blue) was set at the distal border of the foramen, however, the corresponding CRP view's crosshairs were pointed at a farther distance distal to the MF (Figure 6.12, A & B). This finding was detected only in the axial view and was unrecognizable on DP or CRP views. That may be due to the presence of a high bone density superimposing the horizontal sloping path of the canal. Such a finding is essential to be detected prior to any surgical procedure intended in that anatomical area to preserve the neurovascular bundles that may run distally. However, that finding did not seem to alter the value of X1 between the two panoramic views as noticed (X1DP1= 8.9mm, X1CRP1 = 9.2mm).

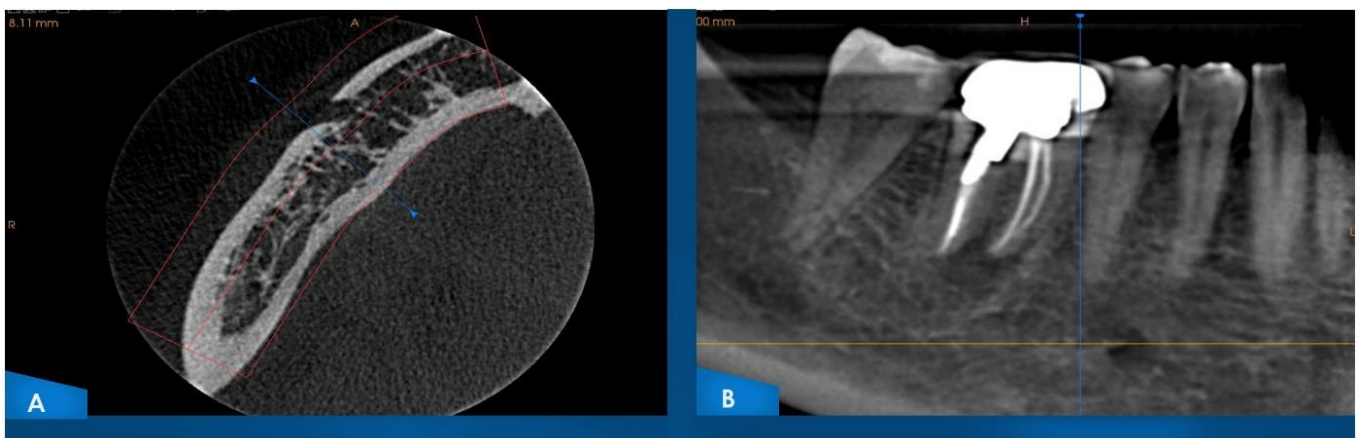


Figure 6.12. (A) A CBCT axial view; the crosshair was set at the distal end of MF in the horizontal plane (Blue line). (B) The correspondent CRP view shows the crosshair situated at a farther distance distally from the MF identified on the same view.



## **6.5 The effects of the bone marrow variability on the identification of MF on panoramic radiographs**

As noticed, that MF identification on the digital panoramic radiographs may be affected by the surrounding bone marrow pattern. This bone marrow can be regularly organized in a manner mimicking or superimposing part of the margins of MF (in certain cases). Such a variation was detected on the CRP view that the MF was presented with a better marginal definition (case 6.7).

The faint appearance of the mental loop, combined with the bone marrow architecture in the bony area squeezed by the loop may be regular and organized enough to appear as a defined and corticated false mental foramen on the DP view as illustrated in case 6.8. Such a finding was only detected on the CRP view as the path of the ID canal with its loop was clear and traceable.

### **Case 6.7**

---

The MF's margins were traced on the DP view (Figure 6.13, A). A small hypo-density was noticed directly superior to the upper MF's margin. That observed hypodensity was not suspicious and was considered to be a bone marrow variation in that area, especially that the MF's cortical margins were continuous and sharply traceable on the DP view. On the CRP view (reconstructed at 15mm thickness) the upper MF's margin was identified at a higher point compared with the DP view (Figure 6.13, B). One of the postulated causes of such an error was the variation in presentation of the bony structure overlying and surrounding the MF between the two views; such a variation could be due to the difference in the trough layer thickness and location between DP and CRP. Moreover, a possible inherent distortion in one of the views cannot be excluded. As a consequence, the upper tangent of the MF was identified at a lower level on the DP view, and contributed to the difference of MH (DP-CRP) value which was 1.5mm (Figure 6.13, C and D).

In addition, an AMF directly located distally to the main MF was found during navigating through the axial view (Figure 6.13, E). On the DP view, it was not apparent while on CRP view it was merely noticeable as a small radiolucency distal to the main foramen (easily could be misinterpreted as bone marrow).

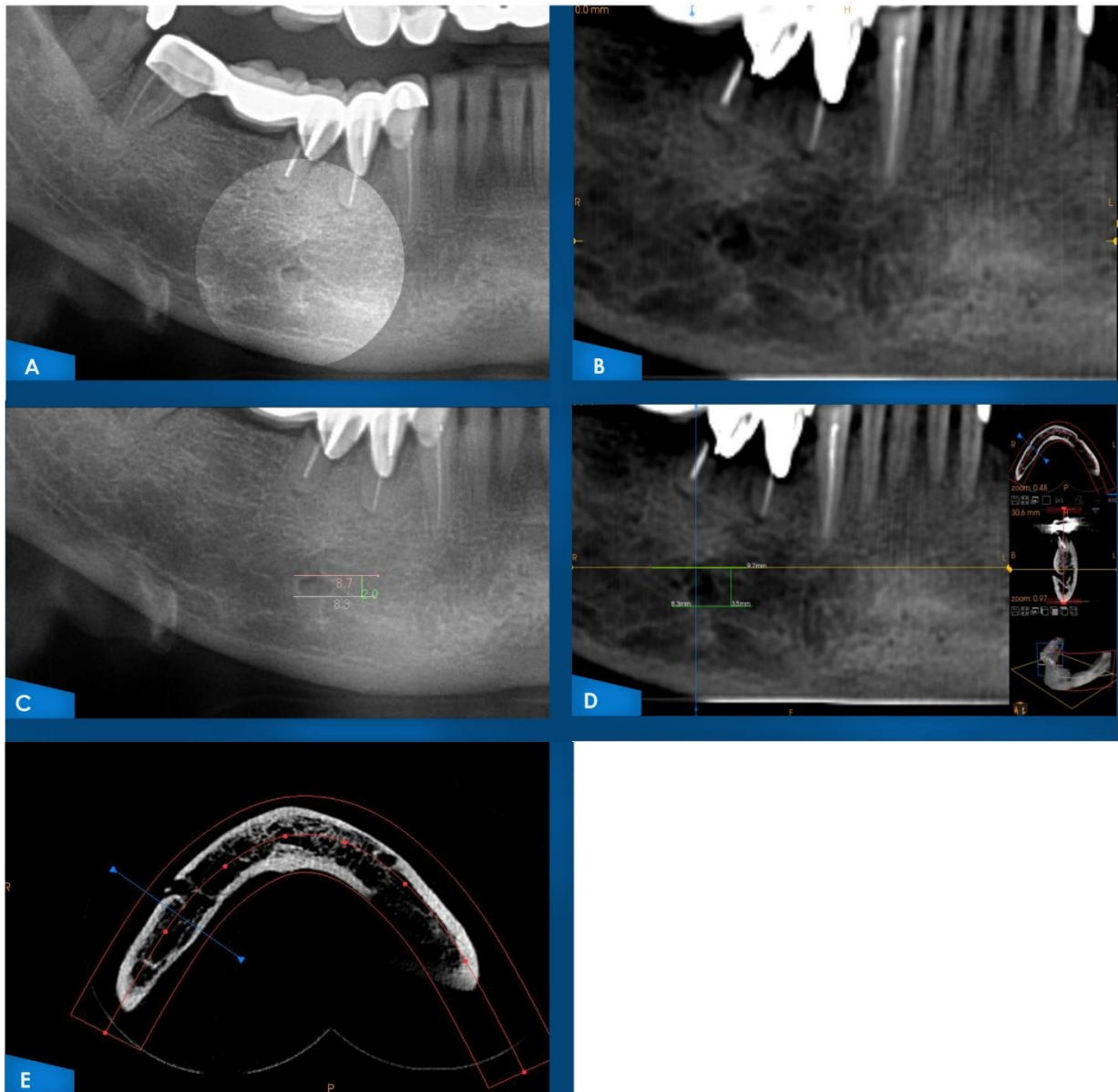


Figure 6.13. (A) DP view shows the mental foramen with well corticated and defined margins and with no evidence of AMF. (B) CRP view represents the MF with an extended mental foramen upper margin compared to that seen on DP view; also shows a small radiolucency distal to the main MF (AMF). (C & D), ML calculations on DP, CRP views (2mm, 3.5mm, respectively). (E) An axial slice shows clearly the AMF distal to the main foramen.



## Case 6.8

The MF's borders were corticated and defined on the DP view (Figure 6.14, A). The CRP view showed the shadow of the mental loop more clearly and there was no evidence that the previously identified MF on the DP view exists on that view (as shown in Figure 6.14, B). The axial view (the slice selected in the middle of the foramen on CRP view) shows that mental canal was ascending and overlying the root tip (about 4mm) of the tooth #35 (Figure 6.14, C). Such a finding could be due to the hypo-dense bone marrow presentation in that designated area that was regular enough in the DP view along with the curve of the loop to form a radiolucency resampling the MF. It was noticed that the CRP view had clearer, sharper and superior presentation of the inferior dental canal structure. A thorough reassessment of the mental region was conducted on the DP view in an attempt to retrace the vital structures. Eventually, the shadow of the loop was barely traceable with a very faint track that was not recognized during the initial evaluation. Missing such a finding could lead to a severe injury of the MF contents, particularly that the MF was overlying the root tip of the tooth.

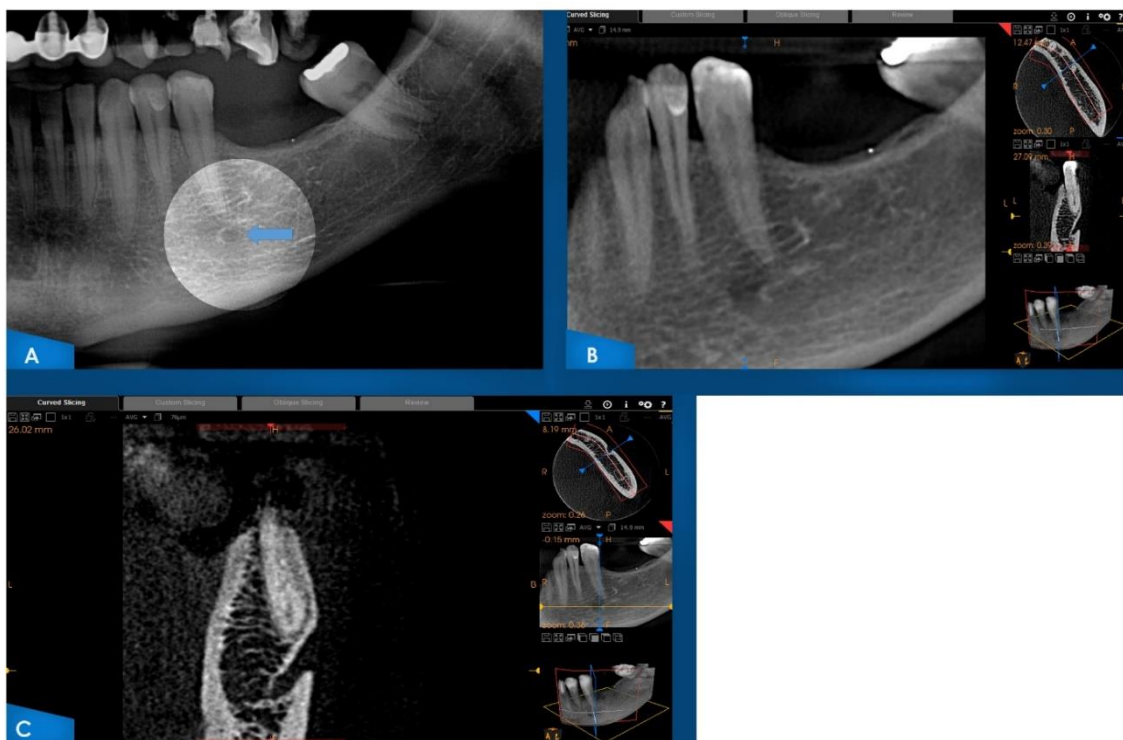


Figure 6.14. (A) DP view, shows the mental foramen with well-defined margins. (B) CRP view shows the shadow of the mental loop much clearly; there was no evidence that the previously identified MF on the DP view was evident on this view. (C) An oblique coronal view (the slice was selected in the middle of the foramen on identified on the CRP); this view shows that mental canal was ascending and overlying the tooth's #35 root tip (about 4mm).

## **6.6 Limitations**

- The sample size was relatively small due to the lack of records compliant to the established inclusion and exclusion criteria within this study.
- The vertical plane of measurements of the mental foramen was studied on three different views; The coronal view served as both a visual control for the detection of the mental foramen as well as provided a vertical measurement compared against those of the panoramic views. The same control could not be established for the horizontal assessment of the mental foramen. Even though the axial view was utilized for visual navigation, horizontal measurements and reference points could not be standardised due to certain anatomical and radiographic planes limitations and thus could not act as a control for the horizontal plane of measurements.
- The absence of a gold standard (e.g. human mandibles) to assess the clinical accuracy.

## Chapter 7 : CONCLUSION AND RECOMMENDATIONS

### 7.1 Conclusion

Despite the limitations of this study, the following conclusions may be drawn: Although there were differences between the digital and CBCT reformatted panoramic views in terms of horizontal and vertical linear measurements, the mean of these differences may still be clinically acceptable. With regards to the vertical positions of the mental foramen, a clinically significant measurement discrepancy found between the panoramic views (DP, CRP) when compared to a coronal view. Clinical application of the coronal view measurements may therefore reduce the risk of neurovascular injury of the mental foramen.

The CBCT reformatted panoramic view was superior to the digital panoramic radiographs in terms of clarity of presentation of the mental foramen borders and the path of the mental loop. However, both panoramic views (DP, CRP) showed an ambiguous presentation of the accessory mental foramen (AMF).

The assessment of the mental structure should be carried out in at least two perpendicular views in order to assess the third dimension. Relying on a view on its own ,even CBCT panoramic view, carries possible risks.

### 7.2 Recommendations

- To assess the vertical position the mental foramen, one should at least take two different views. One of these views must be the coronal view; as this view is capable of demonstrating clearly the vertical path of the mental canal in the mandible.
- To assess the horizontal position the mental foramen, one should at least take two different views. One of these views must be the axial view; as this view is capable of demonstrating clearly the horizontal path of the mental canal, detect any variation in the presentation of MF on panoramic views, and for the detection of possible lateral canals that may not be detected on the other views.
- Further studies to be carried out to investigate the clinical accuracy of the CBCT reformatted panoramic view especially when generated at different levels.

## REFERENCES

- AFKHAMI, F., HARAJI, A. and BOOSTANI, H.R., 2013. Radiographic Localization of the Mental Foramen and Mandibular Canal. *Journal of Dentistry of Tehran University of Medical Sciences*, **10**(5), pp. 436-442.
- ALKHADER, M. and HUDIEB, M., 2014. Comparison of mesiodistal space measurements of single-implant sites on panoramic and oblique images generated by cone-beam CT. *Surgical and Radiologic Anatomy*, **36**(3), pp. 255-258.
- ALKHADER, M., HUDIEB, M. and KHADER, Y., 2016. Comparison of mesiodistal measurements of single implant sites on panoramic images generated at different horizontal levels: A cone beam CT study. *Journal of Oral and Maxillofacial Radiology*, **4**(1), pp. 5.
- AL-MAHALAWY, H., AL-AITHAN, H., AL-KARI, B., AL-JANDAN, B. and SHUJAAT, S., 2017. Determination of the position of mental foramen and frequency of anterior loop in Saudi population. A retrospective CBCT study. *The Saudi Dental Journal*, **29**(1), pp. 29-35.
- AMINOSHARIAE, A., SU, A. and KULILD, J.C., 2014. Determination of the Location of the Mental Foramen: A Critical Review. *Journal of Endodontics*, **40**(4), pp. 471-475.
- ANGELOPOULOS, C., THOMAS, S.L., HECHLER, S., PARISSIS, N. and HLAVACEK, M., 2008. Comparison between digital panoramic radiography and cone-beam computed tomography for the identification of the mandibular canal as part of presurgical dental implant assessment. *Journal of oral and maxillofacial surgery: official journal of the American Association of Oral and Maxillofacial Surgeons*, **66**(10), pp. 2130-2135.
- ASSAF, M. and ABU GHARBYAH, A., 2014. Accuracy of Computerized Vertical Measurements on Digital Orthopantomographs: Posterior Mandibular Region. *Journal of Clinical Imaging Science*, **4**(2), pp. 7.
- BAHLIS, A., MEZZOMO, L.A., BOECKEL, D., COSTA, N.P.D. and TEIXEIRA, E.R., 2010. Accuracy of periapical radiography, panoramic radiography and computed tomography for examining the mental foramen region. *Revista Odonto Ci ncia*, **25**, pp. 282-287.
- BAUMGAERTEL, S., PALOMO, J.M., PALOMO, L. and HANS, M.G., 2009. Reliability and accuracy of cone-beam computed tomography dental measurements. *American Journal of Orthodontics & Dentofacial Orthopedics*, **136**(1), pp. 19-25.
- BHARATHI, U., PRATHIBHA RANI, R.M., BASAPPA, S., KANWAR, S. and KHANUM, N., 2016. Position of the Mental Foramen in Indian and Iranian Subjects: A Radiographic Study. *Journal of International Oral Health*, **8**(1), pp. 41-43.
- BOU SERHAL, C., JACOBS, R., FLYGARE, L., QUIRYNEN, M. and VAN STEENBERGHE, D., 2002. Perioperative validation of localisation of the mental foramen. *Dentomaxillofacial Radiology*, **31**(1), pp. 39-43.
- BUDHIRAJA, V., RASTOGI, R., LALWANI, R., GOEL, P. and BOSE, S.C., 2013. Study of Position, Shape, and Size of Mental Foramen Utilizing Various Parameters in Dry Adult Human Mandibles from North India. *ISRN Anatomy*, **2013**(3), pp. 1-5.
- CARRUTH, P., JIANING, H., BENSON, B. and SCHNEIDERMAN, E., 2015. Analysis of the Size and Position of the Mental Foramen Using the CS 9000 Cone-beam Computed Tomographic Unit. *JOEN Journal of Endodontics*, **41**(7), pp. 1032-1036.

- CORREA, L.R., SPIN-NETO, R., STAVROPOULOS, A., SCHROPP, L., DA SILVEIRA, HELOÍSA EMÍLIA DIAS and WENZEL, A., 2014. Planning of dental implant size with digital panoramic radiographs, CBCT-generated panoramic images, and CBCT cross-sectional images. *Clinical Oral Implants Research*, **25**(6), pp. 690-695.
- D'DHARAN, S.R. and MAHESWARI, T.N.U., 2015. Evaluation of Position of Mental Foramen using Cbct among Chennai Population: a Retrospective Study. *International Journal of Clinical Dentistry*, **8**(4), pp. 295-300.
- DEVLIN, H. and YUAN, J., 2013. Object position and image magnification in dental panoramic radiography: a theoretical analysis. *Dentomaxillofacial Radiology*, **42**(1).
- DHILLON, M., RAJU, S.M., VERMA, S., TOMAR, D., MOHAN, R.S., LAKHANPAL, M. and KRISHNAMOORTHY, B., 2012. Positioning errors and quality assessment in panoramic radiography. *Imaging Science in Dentistry*, **42**(4), pp. 207-212.
- DOBREA, V.C., POPESCU, A.A., DOBREA, M. and BURLIBAŞA, M., 2015. Morphometric study and anatomical position of the mental foramen ("Foramen mentale"). *Journal of Biotechnology*, **208**, Supplement, pp. S23.
- FABIAN, F.M., 2007. Position, shape and direction of opening of the mental foramen in dry mandibles of Tanzanian adult black males. *Italian Journal of Anatomy and Embryology = Archivio italiano di anatomia ed embriologia*, **112**(3), pp. 169-177.
- GANGULY, R., RUPRECHT, A., VINCENT, S., HELLSTEIN, J., TIMMONS, S. and QIAN, F., 2011. Accuracy of linear measurement in the Galileos cone beam computed tomography under simulated clinical conditions. *Dentomaxillofacial Radiology*, **40**(5), pp. 299-305.
- GREENSTEIN, G. and TARNOW, D., 2006. The mental foramen and nerve: clinical and anatomical factors related to dental implant placement: a literature review. *Journal of Periodontology*, **77**(12), pp. 1933-1943.
- GUPTA, V., PITTI, P. and SHOLAPURKAR, A., 2015. Panoramic radiographic study of mental foramen in selected dravidians of south Indian population: A hospital based study. *Journal of Clinical and Experimental Dentistry*, **7**(4), pp. 451.
- JUODZBALYS, G., WANG, H.L. and SABALYS, G., 2010. Anatomy of Mandibular Vital Structures. Part I: Mandibular Canal and Inferior Alveolar Neurovascular Bundle in Relation with Dental Implantology. *Journal of Oral & Maxillofacial Research*, **1**(1). doi:10.5037/jomr.2010.1102.
- KAYAL, R.A., 2016. Distortion of digital panoramic radiographs used for implant site assessment. *Journal of Orthodontic Science*, **5**(4), pp. 117-120.
- KIM, Y.K., PARK, J.Y., KIM, S.G., KIM, J.S. and KIM, J.D., 2011. Magnification rate of digital panoramic radiographs and its effectiveness for pre-operative assessment of dental implants. *Dentomaxillofacial Radiology*, **40**(2), pp. 76-83.
- LUANGCHANA, P., SUCHAYA PORNPRASERTSUK-DAMRONGSRI, KIATTAVORNCHAROEN, S. and JIRAJARIYAVEJ, B., 2015. Accuracy of Linear Measurements Using Cone Beam Computed Tomography and Panoramic Radiography in Dental Implant Treatment Planning. *International Journal of Oral & Maxillofacial Implants*, **30**(6), pp. 1287-1294.

- MBAJIORGU, E.F., MAWERA, G., ASALA, S.A. and ZIVANOVIC, S., 1998. Position of the mental foramen in adult black Zimbabwean mandibles: a clinical anatomical study. *The Central African Journal of Medicine*, **44**(2), pp. 24-30.
- MEHRA, A. and PAI, K.M., 2012. Evaluation of Dimensional Accuracy of Panoramic Cross-Sectional Tomography, Its Ability to Identify the Inferior Alveolar Canal, and Its Impact on Estimation of Appropriate Implant Dimensions in the Mandibular Posterior Region. *Clinical Implant Dentistry & Related Research*, **14**(1), pp. 100-111.
- MOHAMMAD, Z.K., SHADID, R., KAADNA, M., QABAHA, A. and MUHAMAD, A.H., 2016. Position of the Mental Foramen in a Northern Regional Palestinian Population. *Int J Oral Craniofac Sci*, **2**(1), pp. 57.
- MONSOUR, P. and DUDHIA, R., 2008. Implant radiography and radiology. *Australian Dental Journal*, **53**, pp. 11-25.
- MOSHFEGHI, M., TAVAKOLI, M.A., HOSSEINI, E.T., HOSSEINI, A.T. and HOSSEINI, I.T., 2012. Analysis of linear measurement accuracy obtained by cone beam computed tomography (CBCT-NewTom VG). *Dental Research Journal*, **9**(Suppl 1), pp. 57.
- MRAIWA, N., JACOBS, R., MOERMAN, P., LAMBRICHTS, I., VAN STEENBERGHE, D. and QUIRYNEN, M., 2003. Presence and course of the incisive canal in the human mandibular interforaminal region: two-dimensional imaging versus anatomical observations. *Surgical and Radiologic Anatomy: SRA*, **25**(5-6), pp. 416-423.
- NAGALAXMI, V., SWETHA, P., SRIKANTH, K. and LALITHA C., 2015. Implant Imaging: A Review of Literature. *IJSS Case Reports & Reviews*, **2**(5).
- NAGARAJAN, A., PERUMALSAMY, R., THYAGARAJAN, R. and NAMASIVAYAM, A., 2014. Diagnostic imaging for dental implant therapy. *Journal of Clinical Imaging Science*, **4**.
- NEIVA, R.F., GAPSKI, R. and WANG, H., 2004. Morphometric Analysis of Implant-Related Anatomy in Caucasian Skulls. *Journal of Periodontology*, **75**(8), pp. 1061-1067.
- NEVES, F., NASCIMENTO, M., OLIVEIRA, M., ALMEIDA, S. and BÓSCOLO, F., 2014. Comparative analysis of mandibular anatomical variations between panoramic radiography and cone beam computed tomography. *Oral & Maxillofacial Surgery*, **18**(4), pp. 419-424.
- NIKNEZHAN, S., AVAL, SH., BAKHSHALIAN, N., SHAHAB, S., MOHAMMADPOUR, M. and SARIKHANI, S., 2014. Accuracy of linear measurement using cone-beam computed tomography at different reconstruction angles. *Imaging Science in Dentistry*, **44**(4), pp. 257-62.
- PARNAMI, P., GUPTA, D., ARORA, V., BHALLA, S., KUMAR, A. and MALIK, R., 2015. Assessment of the horizontal and vertical position of mental foramen in Indian population in terms of age and sex in dentate subjects by panoramic radiographs: A retrospective study with review of literature. *Open Dentistry Journal*, **9**, pp. 297-302.
- PERTL, L., GASHI-CENKOGLU, B., REICHMANN, J., JAKSE, N. and PERTL, C., 2013. Preoperative assessment of the mandibular canal in implant surgery: comparison of rotational panoramic radiography (OPG), computed tomography (CT) and cone beam computed tomography (CBCT) for preoperative assessment in implant surgery. *European Journal of Oral Implantology*, **6**(1), pp. 73-80.

- PHILLIPS, J. L., WELLER, R. N. and KULILD, J.C., 1992. The mental foramen: Part III. Size and position on panoramic radiographs. *Journal of Endodontics*, **18**(8), pp. 383-386.
- PHILLIPS, J.L., WELLER, R.N. and KULILD, J.C., 1990. The mental foramen: Part I. Size, orientation, and positional relationship to the mandibular second premolar. *JOEN Journal of Endodontics*, **16**(5), pp. 221-223.
- RANGANATHAN, P., PRAMESH, C. and BUYSE, M., 2015. Common pitfalls in statistical analysis: Clinical versus statistical significance. *Perspect Clin Res*, (3), pp. 169.
- RONDON, R., PEREIRA, Y. and NASCIMENTO, G., 2014. Common positioning errors in panoramic radiography: A review. *Imaging Science in Dentistry*, **44**(1), pp. 1-6.
- RUSHTON, V.E. and HORNER, K., 1996. The use of panoramic radiology in dental practice. *Journal of Dentistry*, **24**(3), pp. 185-201.
- SHAH, N., BANSAL, N. and LOGANI, A., 2014. Recent advances in imaging technologies in dentistry. *World Journal of Radiology*, **6**(10), pp. 794-807.
- SINGH, R. and SRIVASTAV, A.K., 2010. Study of Position, Shape, Size and Incidence of Mental Foramen and Accessory Mental Foramen in Indian Adult Human Skulls. *International Journal of Morphology*, **28**(4), pp. 1141-1146.
- STRAMOTAS, S., GEENTY, J.P., PETOCZ, P. and DARENDELILER, M.A., 2002. Accuracy of linear and angular measurements on panoramic radiographs taken at various positions in vitro. *European Journal of Orthodontics*, **24**(1), pp. 43-52.
- STRATEMANN, S.A., HUANG, J.C., MAKI, K., MILLER, A.J. and HATCHER, D.C., 2008. Comparison of cone beam computed tomography imaging with physical measures. *Dentomaxillofacial Radiology*, **37**(2), pp. 80-93.
- SUOMALAINEN, A., PAKBAZNEJAD ESMAEILI, E. and ROBINSON, S., 2015. Dentomaxillofacial imaging with panoramic views and cone beam CT. *Insights into Imaging*, **6**, 1-16.
- TANG, Z., CHEN, K. and LIU, X., 2017. Comparison of digital panoramic radiography versus cone beam computerized tomography for measuring alveolar bone. *Head & Face Medicine*, **13**(1), pp. 1-7.
- VAZQUEZ, L., NIZAM AL DIN, Y., CHRISTOPH BELSER, U., COMBESURE, C. and BERNARD, J.P., 2011. Reliability of the vertical magnification factor on panoramic radiographs: clinical implications for posterior mandibular implants. *CLR Clinical Oral Implants Research*, **22**(12), pp. 1420-1425.
- VAZQUEZ, L., SAULACIC, N., BELSER, U. and BERNARD, J., 2008. Efficacy of panoramic radiographs in the preoperative planning of posterior mandibular implants: a prospective clinical study of 1527 consecutively treated patients. *Clinical Oral Implants Research*, **19**, 1, pp. 81-85.
- VERMA, P., BANSAL, N., KHOSA, R., VERMA, K.G., SACHDEV, S.K., PATWARDHAN, N. and GARG, S., 2015. Correlation of Radiographic Mental Foramen Position and Occlusion in Three Different Indian Populations. *The West Indian medical journal*, **64**(3), pp. 269-74.

- VON ARX, T., FRIEDLI, M., SENDI, P., LOZANOFF, S. and BORNSTEIN, M.M., 2013. Location and Dimensions of the Mental Foramen: A Radiographic Analysis by Using Cone-beam Computed Tomography. *JOEN Journal of Endodontics*, **39**(12), pp. 1522-1528.
- VUJANOVIC-ESKENAZI, A., VALERO-JAMES, J., SÁNCHEZ-GARCÉS, M. and GAY-ESCODA, C., 2015. A retrospective radiographic evaluation of the anterior loop of the mental nerve: Comparison between panoramic radiography and cone beam computerized tomography. *Medicina Oral, Patología Oral y Cirugía Bucal*, **20**(2), pp. e245.
- WADU, S.G., PENHALL, B. and TOWNSEND, G.C., 1997. Morphological variability of the human inferior alveolar nerve. *Clinical Anatomy (New York, N.Y.)*, **10**(2), pp. 82-87.
- WALKER, C., THOMSON, D. and MCKENNA, G., 2009. Case study: limitations of panoramic radiography in the anterior mandible. *Dental Update*, **36**(10), pp. 620-623.
- WIKNER, J., FRIEDRICH, R.E., RASHAD, A., SCHULZE, D., HANKEN, H., HEILAND, M., GRÖBE, A. and RIECKE, B., 2016. Obstacles in spatial evaluation of CBCT-reformatted panoramic imaging. *Dentomaxillofacial Radiology*, **45**(4).
- YOSUE, T. and BROOKS, S.L., 1989. The appearance of mental foramina on panoramic radiographs. I. Evaluation of patients. *Oral Surgery, Oral Medicine, and Oral Pathology*, **68**(3), pp. 360-364.
- ZARCH, S., BAGHERPOUR, A., LANGAROODI, A., YAZDI, A. and SAFAEI, A., 2011. Evaluation of the Accuracy of Panoramic Radiography in Linear Measurements of the Jaws. *Iranian Journal of Radiology*, **8**(2), pp. 97-102.



# APPENDICES

## APPENDIX 01: DATA COLLECTION SHEET

1				Digital panorama (DP)				Cbct reformatted panoramic view (CRP)					CBCT coronal view (CORO)	
2	ID #	Gender	Age	X1DP1	X2DP1	Y1DP1	MHDP1	MWDP1	X1CRP1	X2CRP1	Y1CRP1	MHCRP1	MWCRP1	Y1CORO1
3														
4														
5														
6														
7														
8														
9														
10														
11														
12														
13														
14														
15														
16														
17														
18														
19														
20														
21														

**Appendix 02: LETTER OF REQUEST FOR ACCESS TO THE PATIENTS FILES**

**LETTER OF REQUEST FOR ACCESS TO THE PATIENTS FILES**

**To Dr. Emad Qirresh**

**Manager of QIRRESH RADIOLOGY CENTER - Ramallah, Palestine.**

Dear Sir,

I am currently doing an MSc Dent at the UWC in oral and maxillofacial radiology. The title of the mini-thesis that I plan to do is **“The accuracy of the mental foramen position on panoramic radiographs and CBCT”**

The planned research is a retrospective, record-based study. I have applied for the approval and registration of the protocol by the research committee of UWC.

I therefore kindly request your permission to access patient records at your private center. The patient’s names will not be noted in the study. All clinical data will be used with discretion and confidentiality. No clinical files will leave the center.

Thanks for your attention in the matter.

Yours sincerely

.....

Khaled Beshtawi

Date: 20/8/2016

**Appendix 03: AUTHORIZATION LETTER THE RADIOLOGY CENTER TO ACCESS THEIR DATABASE**



مركز قرش لأشعة الاسنان

Qirresh oral radiology center

رام الله - عمارة برج الساعة - ط5 - تلفاكس: 009722967603

Ramallah City - Burjsaa Bldg. - 5<sup>th</sup> floor - Telefax:009722967603

Dear Dr. khaledBeshtawi  
MSc. student in oral and maxillofacial radiology  
University of Western Cape, South Africa

I acknowledge receipt of your request to access patient's files in my Dental Radiology Center to conduct a research titled: "The accuracy of the mental foramen position on panoramic radiographs and CBCT"

I accept you request and advise the following provisos:

- 1- The patient's names will not be noted in the study and all effort for anonymity will be maintained by substituting names for case numbers.
- 2- All clinical data will be used with discretion and confidentiality.

Looking forward to this collaboration.

Kindest regards

مركز قرش لأشعة الأسنان

Date: 23/8/2016

Dr.EmadQirresh, B.D.S, O.M.R

Manager of Qirresh dental radiology center



## Appendix 04: ETHICAL APPROVAL AND PROJECT REGISTRATION LETTER



**Office of the Deputy Dean**  
**Postgraduate Studies and Research**  
Faculty of Dentistry & WHO Collaborating Centre for Oral Health



---

UNIVERSITY OF THE WESTERN CAPE  
Private Bag X1, Tygerberg 7505  
Cape Town  
SOUTH AFRICA

Date: 07<sup>th</sup> December 2016

**For Attention:** Dr. K. Beshtawi

Dear Dr Beshtawi

**STUDY PROJECT:** The accuracy of the mental foramen position on panoramic radiographs and CBCT

**PROJECT REGISTRATION NUMBER:** BM/16/5/1

**ETHICS:** Approved

At a meeting of the Senate Research Committee held on Thursday 24<sup>th</sup> November 2016 the above project was approved. This project is therefore now registered and you can proceed with the study. Please quote the above-mentioned project title and registration number in all further correspondence. Please carefully read the Standards and Guidance for Researchers below before carrying out your study.

Patients participating in a research project at the Tygerberg and Mitchells Plain Oral Health Centres will not be treated free of charge as the Provincial Administration of the Western Cape does not support research financially.

Due to the heavy workload auxiliary staff of the Oral Health Centres cannot offer assistance with research projects.

Yours sincerely

Professor Lawrence Stephen