

# **Interceptive orthodontic treatment need among children attending dental clinics in the Tygerberg sub-district.**



**A mini-thesis submitted in partial fulfilment of the  
requirements for the degree of MSc in Paediatric Dentistry,**

**University of the Western-Cape**

**Amanda Karien Marais (BChD)**

Student nr: 2382354

October 2013

**Research was funded by the MRC**

Supervisor: Dr. A. Hudson

Co-supervisor: Dr. N. Mohamed

Interceptive orthodontic treatment need among children attending dental clinics in the Tygerberg sub-district.



## Keywords

Children

Habits

Thumbsucking

Functional interferences

Mechanical interferences

Dental development

Dental age

Early loss of primary teeth

Malocclusion

Interceptive orthodontic treatment need



## **Abstract**

### **Background**

In the Western-Cape province, orthodontic treatment provided to government patients is limited to tertiary hospitals such as the Tygerberg Oral Health Centre (TOHC). This results in growing waiting lists which place a huge strain on resources of the facility.

### **Objectives**

To determine:

1. The prevalence of malocclusion among 7-to-10-year-old children examined at dental clinics within the Tygerberg sub-district.
2. The types of malocclusion they present with.
3. Which of these malocclusions can be treated with interceptive orthodontic treatment.

### **Methods**

An analytical, descriptive, cross-sectional study was carried out and quantitative methods were used to achieve the aim and objectives. The study sample consisted of 100 children, 46 male and 54 female, from Bellville and Bishop Lavis dental clinics. Dental examinations were done by one examiner on children between the ages of 7 and 10 years. Dental problems were identified which, if left untreated, could result in the need for more complex orthodontic treatment at a later stage. All the necessary ethical clearance was obtained.

### **Results**

The results showed that there is a very large interceptive orthodontic treatment need (79%) at these clinics. A large proportion (70%) presented with detrimental habits. Thumbsucking was more prevalent among girls than boys. Other problems like mouthbreathing, lip wedging, deep bite, asymmetrical mobility of primary teeth, rotated lateral incisors and crossbites were found. The biggest concern was that 71% of the children had early loss of primary teeth and only 5% of children received restorations, resulting in a high prevalence of unfavourable molar relationships. All of these should be addressed early, thereby preventing the development of complex orthodontic problems or skeletal discrepancies.

## **Conclusion**

Interceptive and preventive orthodontic treatment should be regarded as a primary health centre service, as it may reduce the need for costly fixed orthodontic treatment. The study showed that urgent intervention is necessary from the Department of Health to address this issue.



## Declaration

I hereby declare that “Interceptive orthodontic treatment need among children attending dental clinics in the Tygerberg sub-district” is my own work, that it has not been submitted before for any degree or examination at any university, and that all the sources I have used or quoted have been indicated and acknowledged by complete references.

Amanda Karien Marais

January 2014

Signed:.....



## **Acknowledgements**

I would like to thank God for helping me and providing me with the opportunity to be able to do post-graduate studies and learn from the experience. Secondly, I wish to thank my husband, Izak and the rest of my family and friends for supporting and loving me.

My sincere gratitude goes to both my supervisors, Dr Hudson and Dr Mohamed, for putting in so much effort and time, in helping and guiding me to produce this thesis. I also wish to thank Prof Maritz and everyone involved in helping me with the statistics.

I am very thankful to the Medical Research Council (MRC) for providing me with the scholarship to conduct the research.



## Table of Contents

Title page.....	i
Keywords .....	ii
Abstract .....	iii
Declaration .....	v
Acknowledgements .....	vi
List of tables .....	x
List of figures .....	xi
List of abbreviations.....	xii
List of addenda.....	xiii
CHAPTER 1: .....	1
INTRODUCTION .....	1
LITERATURE REVIEW.....	2
1.1    Definitions .....	2
1.2    Orthodontic treatment need: studies within South Africa .....	2
1.3    Normal dental development .....	4
1.4    Molar relationship .....	6
1.5    Dental manifestations that can be addressed with interceptive orthodontic treatment.....	7
1.5.1    Habits .....	7
1.5.2    Interferences .....	9
1.5.3    Problems hampering normal dental development.....	12
1.5.4    Skeletal discrepancies .....	14
CHAPTER 2: MATERIALS AND METHODS .....	16
2.1    Aims .....	16
2.2    Objectives .....	16



2.3	Ethics .....	16
2.4	Study sample. ....	16
2.5	Research design .....	16
2.6	Inclusion and exclusion criteria.....	17
2.7	Data collection, instruments and materials.....	17
2.7.1	Habits .....	18
2.7.2	Functional interferences .....	18
2.7.3	Mechanical interferences .....	18
2.7.4	Dental development .....	18
2.7.5	Maxillary permanent central incisors.....	19
2.7.6	Maxillary lateral incisors.....	20
2.7.7	Mandibular incisors.....	20
2.7.8	Canines.....	20
2.7.9	Posterior teeth.....	21
2.7.10	Restorations and untreated gross interproximal caries.....	21
2.7.11	Need for interceptive orthodontic treatment .....	21
2.8	Data Processing and Analysis .....	21
CHAPTER 3: RESULTS .....		23
3.1	Demographics .....	23
3.2	Habits .....	24
3.3	Interferences.....	25
3.4	Dental development .....	26
3.5	Interceptive orthodontic treatment need.....	33
CHAPTER 4: DISCUSSION.....		34
4.1	Demographics.....	34
4.2	Habits.....	34

4.3 Interferences .....	35
4.4 Dental development .....	36
4.5 Interceptive orthodontic treatment need.....	40
4.6 Limitations of the study .....	40
CHAPTER 5: CONCLUSION AND RECOMMENDATIONS .....	42
REFERENCES.....	43



## List of tables

Table 3.2.1	Habits present	24
Table 3.4.1	Gender distribution versus premature canines	27
Table 3.4.2	Eruption pattern of incisors	28
Table 3.4.3	Alignment of anterior teeth	29
Table 3.4.4	Dental crossbites	30



## **List of figures**

Figure 3.1.1	Children examined at dental clinics	23
Figure 3.1.2	Gender distribution at both clinics	23
Figure 3.1.3	Age distribution at clinics	24
Figure 3.3.1	Functional interferences	25
Figure 3.3.2	Mechanical interferences	25
Figure 3.4.1	Dental versus chronological age	26
Figure 3.4.2	Gender distribution versus accelerated growth	26
Figure 3.4.3	Early loss of primary canines	27
Figure 3.4.4	Mobility of primary teeth	28
Figure 3.4.5	Presence of midline diastemas	29
Figure 3.4.6	Age distribution versus absent midline diastema	30
Figure 3.4.7	Untreated gross interproximal caries	31
Figure 3.4.8	Early loss of posterior teeth	31
Figure 3.4.9	Early loss of primary canines versus early loss of posterior teeth	32
Figure 3.4.10	Distribution of molar relationships	32
Figure 3.5.1	Interceptive orthodontic treatment need	33

## **List of abbreviations**

DAI:	Dental Aesthetic Index
DOH:	Department of Health
TMJ:	Temporo-mandibular joint
TOHC:	Tygerberg Oral Health Centre



## **List of addenda**

Appendix A:	Written informed consent	50
Appendix B:	Data capture sheet	53



## **CHAPTER 1:**

### **INTRODUCTION**

The majority of dentists only assess patients for orthodontic treatment when the patient presents with all their permanent teeth. Most of the government dental facilities are not able to provide interceptive orthodontic treatment and referrals are made to tertiary dental hospitals. As a result the waiting list for fixed orthodontic treatment at the Tygerberg Oral Health Centre (TOHC) is extremely long and increasing yearly.

In 2007, the waiting list consisted of 24 patients, but by the end of 2011 it had reached a total of 1610. This is indicative of the urgent need for complex orthodontic treatment which is too extensive for the facility to cope with and a large financial burden is placed on the government to treat these patients.

Interceptive and preventive orthodontic treatment should be regarded as a primary health care service, as it is less expensive than fixed orthodontic treatment. The goal of early interceptive orthodontics should be to help prevent the progression of permanent soft tissue or bony changes (Joondeph, 1993). It also promotes better oral health care and decreases the risk of dental caries as a result of malocclusion (Kerosuo, 2002).

Previous studies done to determine the orthodontic treatment need mainly focused on children 12 years of age and older (Van Wyk and Drummond, 2005; Hlongwa and du Plessis, 2005). However, this age is beyond the realm of preventive and interceptive orthodontics (Kerosuo, 2002; King and Brudvik, 2010). During the mixed dentition stage, earlier intervention is possible, resulting in reduced costs for the patient and the health system (King and Brudvik, 2010). The psychological influence that malocclusion could have on the patient would also be addressed at an earlier stage (Kerosuo, 2002; King and Brudvik, 2010).

This study seeks to determine the need for interceptive orthodontic treatment among 7-to-10 year old children at two clinics in the Tygerberg sub-district.

# **LITERATURE REVIEW**

## **1.1 Definitions**

Preventative orthodontics refers to those measures taken to maintain the integrity of the normal developing dentition. These measures taken may include dietary counselling, dental prophylactic and conservative treatment and monitoring of the developing dentition (Hudson, personal communication, 2012).

Interceptive orthodontics refers to simple orthodontic measures taken in order to correct developing problems so that, once corrected, normal development and growth can continue (Hudson, personal communication, 2012).

Many of the procedures are common in preventive and interceptive orthodontics, but the timings are different (Hudson, personal communication, 2012).

## **1.2 Orthodontic treatment need: studies within South Africa**

Van Wyk and Drummond (2005) determined the prevalence of malocclusion and the relationship between certain socio-demographic elements among 12-year-old South African school children using the Dental Aesthetic Index (DAI).

The study demonstrated that there is a high prevalence of malocclusion among 12-year-old children in South Africa. These include:

- 47.7% with minor malocclusion
- 52.3% with identifiable malocclusion
  - 21.2% of them presented with clear-cut malocclusion
  - 14.1% with severe malocclusion and
  - 16.9 % with extreme malocclusion.

Hlongwa and du Plessis (2005) demonstrated that the need for orthodontic treatment among 12-year-old South African children in Mankweng, Limpopo was high. The results indicated that:

- 47% of the sample needed orthodontic treatment. Of these:
  - 20% had a definitive malocclusion
  - 13% had a severe malocclusion and
  - 14% had a handicapping malocclusion.



de Mûelenaere (1997) conducted a study to investigate the possibilities for prevention of malocclusions in the mixed dentition stage of South African children. The first set of examinations was done on 951, 8-to-9-year-old children from 9 primary schools in Pretoria. Approximately 67% of them presented with Class I malocclusions. Anterior open bites with specific contributing factors occurred in 27.8%.

After 2 years, only 493 children were re-examined. It was found that:

- In 12.1% of the 493 children, an acceptable occlusion had developed between the 1<sup>st</sup> and 2<sup>nd</sup> visits.
- Malocclusion was noted in 97% of the sample.
- 32.4% of the children received orthodontic treatment between the two visits.
- 3.3% of these were treated at government facilities.
- In 64.6% of the subjects, the malocclusion was not identified or addressed.

The need for interceptive orthodontic treatment is controversial and two schools of thought exist: for and against early intervention (Mirabelli, 2005; Patti and D'Arc, 2005). Comprehensive treatment might still be needed after interceptive orthodontic treatment (Jolley, 2010). The opposing group feels that it is better to start treatment when the permanent second molars and premolars have fully erupted, so that the treatment does not exceed 2 to 3 years (Patti and D'Arc, 2005, Proffit, 2013).

Proffit (2006) stated that it is vital to consider two aspects when one wants to determine the optimal timing for orthodontic treatment. These include "effectiveness" and "efficiency". According to these principles, the gold standard for orthodontic timing is during the adolescent growth spurt, beginning in the late mixed or early permanent dentition (Proffit, 2006).

Interceptive orthodontic treatment has been shown to be beneficial in decreasing the severity of malocclusion, improving self-confidence, removing detrimental habits, facilitating normal tooth eruption and improving some skeletal growth problems (Kerosuo 2002; King and Brudvik, 2010). Therefore the primary goal is

to eradicate or minimize dentoalveolar and skeletal disorders which are obstructing growth, function, aesthetics and the psychological welfare of children (Patti and D’Arc, 2005; King and Brudvik, 2010).

If treatment is not carried out during the mixed dentition stage and it is postponed until all the permanent teeth have erupted, more problems can arise and fixed orthodontic treatment will most likely be needed. Problems may include failure to modify skeletal growth problems or break detrimental habits (Kerosuo 2002; Patti and D’Arc, 2005; Proffit, 2006; King and Brudvik, 2010). The ability to guide dento-alveolar development would also be lost (Kerosuo, 2002; Patti and D’Arc, 2005; Proffit, 2006; King and Brudvik, 2010). Treatment would then often entail dental extractions and the need for difficult and complex appliances that could be detrimental to the health of the teeth and adjacent tissues (Patti and D’Arc, 2005).

Interceptive orthodontic treatment is a simple, beneficial method that should not cause strain on the co-operation of young patients (Patti and D’Arc, 2005). It is important to establish what the cause of malocclusion is, before deciding on a treatment plan (Proffit, 2013). According to the literature, there are many classification systems available to determine the possible causes of malocclusion. These include classifications by White and Gardiners, Salzmann, Moyers and Graber (Singh, 2007).

Moyers’ classification includes the craniofacial skeleton, dentition, orofacial musculature and soft tissues of the masticatory system. According to him, there are many contributing factors (genetic and environmental) and these often appear in clusters (Singh, 2007).

### **1.3 Normal dental development**

The change from the primary to the permanent dentition starts at the dental age of 6 years and ends at a dental age of 12 years (Proffit, 2013). It consists of 3 stages which include the first transitional stage, inter-transitional stage and second transitional stage (Bhalajhi, 2004; Rao, 2008).

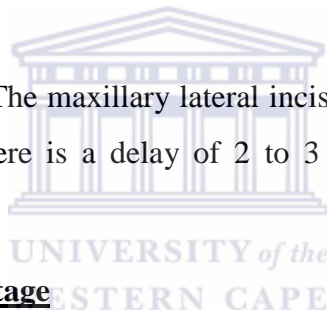
### **The first transitional stage**

This period is seen between dental ages of 6 and 8 years. It is characterized by the eruption of the first permanent molars and the exchange of the primary incisors with the permanent incisors (Rao, 2008; Proffit, 2013).

**Dental age of 6 years:** The flush terminal plane of the primary second molars will guide the permanent molars to erupt in an edge-to-edge relationship in almost 75% of all children (Patti and D’Arc, 2005; Proffit, 2013; Hudson, personal communication, 2012). Once the first permanent molars have erupted, the permanent mandibular incisors erupt (Proffit, 2013).

**Dental age of 7 years:** The maxillary central incisors and mandibular lateral incisors erupt one year after the mandibular central incisors have erupted (Proffit, 2013).

**Dental age of 8 years:** The maxillary lateral incisors erupt and all the permanent incisors are present. There is a delay of 2 to 3 years before any further teeth appear (Proffit, 2013).



### **The inter-transitional stage**

**Dental age of 9 years:** This mixed dentition phase is relatively stable with no active tooth eruption (Patti and D’Arc, 2005; Rao, 2008). It is also known as the “ugly duckling” stage with midline diastemas that develop (Patti and D’Arc, 2005; Rao, 2008) and both the upper and lower permanent canine bulges should be palpable (Hudson *et al.*, 2010; Hudson *et al.*, 2011).

**Dental age 10:** Here, it is important to monitor the amount of resorption of the primary canines and molars as well as the root development of their permanent successors (Proffit, 2013).

### **The second-transitional stage**

This stage is seen between the dental ages of 10-to-12 years and it is characterized by the replacement of the primary molars and canines with the premolars and

permanent canines (Rao, 2008). The permanent molars will drift mesially into a normal Class I relationship utilizing the leeway space (Patti and D'Arc, 2005).

**Dental age 11** is characterized by the eruption of the mandibular canines, mandibular first premolars and the maxillary first premolars, which erupt almost at the same time (Proffit, 2013).

**Dental age 12:** All the remaining succedaneous permanent teeth erupt (Proffit, 2013).

#### **1.4 Molar relationship**

Angle classifies the first permanent molar relationships as cited by Proffit (2013) into a Class I, Class II or Class III relationship.

**A Class I molar relationship** is seen as a favourable (normal) relationship in only a small (14%) percentage of children in the mixed dentition stage (Patti and D'Arc, 2005). It is present when the mesio-buccal cusp of the upper first permanent molar occludes in the buccal groove of the lower first permanent molar (Proffit, 2013).

**A Class II molar relationship** is seen as unfavourable and is present when the buccal cusp of the upper first permanent molar is positioned anteriorly (more than half a cusp size) with regards to the buccal groove of the lower first permanent molar (Proffit, 2013).

**A cusp-to-cusp Class II molar relationship** is considered normal during the mixed dentition stage of development. Almost three quarters of children present with this molar relationship in the mixed dentition (Patti and D'Arc, 2005). This is clinically identified when the buccal cusp tips of the first permanent molars coincide in the same vertical plane (Proffit, 2013).

**A class III molar relationship** is seen when the buccal cusp of the upper first permanent molar is posteriorly placed (more than half a cusp size) with regards to the buccal groove of the lower first permanent molar (Proffit, 2013).

## **1.5 Dental manifestations that can be addressed with interceptive orthodontic treatment**

### **1.5.1 Habits**

Genetic and environmental influences are the most important factors causing malocclusion (Yamaguchi and Sueishi, 2003). Abnormal oral functions which are also known as detrimental oral habits are defined as “behaviours that interfere with the child’s physical, emotional or social well-being” (Rao, 2008). Habits mostly include thumbsucking, tongue thrusting, nail and pencil biting (Proffit, 2013), tongue biting, mouthbreathing and chewing unilaterally (Yamaguchi and Sueishi, 2003).

With a digit sucking habit the position of the finger and tongue can also aggregate the problem (Flemming, 2008). During thumbsucking, the tongue is kept in a lower position away from the palate which can lead to narrowing of the maxilla (Flemming, 2008).

It is important to establish the age of the patient and if the habit might be considered “normal” for example thumbsucking at the age of 3 years (Proffit, 2013). The possible cause, frequency, intensity and duration of the habit are important factors that need to be determined (Rao, 2008; Proffit, 2013).

There are many possible causes related to abnormal habits, but some include psychological or genetic factors, nervousness, stress, lonesomeness, or idleness (Tanaka *et al.*, 2008). It is important to try conservative methods before resorting to orthodontic appliances for treatment of habits (Rao, 2008). Discussions should be held with the child and parents and habit reminders such as a bitter substance or nail polish applied to the thumb could be used (Rao, 2008).

If a malocclusion resulting from thumbsucking is present in the late mixed dentition or early permanent stage, it usually does not self-correct and interceptive orthodontic treatment is necessary (Stojanović, 2007). Even if thumbsucking during the mixed dentition stage has not resulted in the development of a malocclusion, if left to continue into the permanent dentition, chances that a malocclusion will develop are high (Singh *et al.*, 2008; Urzal *et al.*, 2013).

Since the 1960's, Moss (1968) has theorized and demonstrated that growth of the skeletal bones are also influenced by other mechanisms, known as the "functional matrix theory." For instance, the growth of the mandible does not primarily occur at the condyles, but is mainly due to normal function at the matrices of the developing teeth, muscles and soft tissues (Moss, 1997; Proffit, 2013).

The Moss theory therefore implies that if abnormal functions are present and interference takes place at the functional matrices, normal growth and development of the jaws would be detrimentally affected (Moss, 1997; Proffit, 2013). The result could be malocclusion and or skeletal problems (Moss, 1997; Proffit, 2013).

Malocclusions associated with digit sucking can include anterior open bites, proclined anterior teeth, increased overjet (Flemming, 2008; Mtaya *et al.*, 2009), retroclined mandibular teeth, a retruded mandible or narrow maxilla, TMJ (temporo-mandibular joint) problems, central diastemas, (Singh *et al.*, 2008) and posterior crossbites (Kennedy and Osepchook, 2005; Flemming, 2008; Proffit, 2013). Habits could cause a rippling effect in the further development of malocclusion, for example, the related anterior open bite could interfere and further affect the facial growth direction of the patient (Patti and D'Arc, 2005).

A simple anterior open bite is present from canine to canine and it is usually associated with a tongue thrust (Urzal *et al.* 2013), which maintains the anterior seal (Proffit, 2013). Possible aetiological factors for a simple anterior open bite include thumbsucking, lower lip biting and mouth breathing (Urzal *et al.*, 2013).

A simple tongue thrust is defined when the tongue makes contact with any teeth anterior to the molars during swallowing (Dixit and Shetty, 2013). Stojanović (2007) suggested that a tongue thrust either causes an anterior open bite, or it develops secondary to thumbsucking.

A strong association was found between speech problems among children with a tongue thrust and anterior open bite (Khinda and Grewal, 1999; Dixit and Shetty, 2013). Detrimental habits do not only affect the occlusion, but it also negatively impacts the oral health related quality of life which includes oral symptoms like

gag reflexes, difficulty in chewing, emotional and social well-being (Leme *et al.*, 2013).

### **1.5.2 Interferences**

The functional matrix theory also applies to interferences. As normal function leads to normal form, interferences can negatively affect the facial growth pattern (Moss 1997).

Interferences can be classified as functional or mechanical. Functional interferences include mouthbreathing, tongue thrust (complex open bite) and lip wedging. Mechanical interferences include a Pseudo Class III, functional crossbites and deep bites (Patti and D'Arc, 2005; Proffit, 2013).

#### **1.5.2.1 Functional interferences**

It is well documented that untreated mouthbreathing during childhood could have a negative impact on dental and facial development (Bresolin *et al.*, 1983; Principato, 1991; Faria *et al.*, 2002 and Harari *et al.*, 2010). This may include over-eruption of the molars, increased facial height, a higher palatal plane (Faria *et al.*, 2002), increased overjet (Harari *et al.*, 2010) and posterior crossbites (Kennedy and Osepchook, 2005). It may also result in the overdevelopment of the facial sinus with a disruption in air flow and an underdeveloped, narrow, V-shaped maxilla (Patti and D'Arc, 2005).

Mahony *et al* (2004) demonstrated in a longitudinal study that if the adenoids in children suffering from chronic mouthbreathing are timeously removed during childhood, it can significantly reduce the risk of developing dental and skeletal problems.

Another problem with mouthbreathing in children is the risk of the tongue obstructing the airway and causing sleep apnoea (Defabjanis, 2003). This may result in sleepless and restlessness nights and ultimately in increased morbidity (Defabjanis, 2003). It is therefore vital that mouthbreathing be identified and treated as early as possible to ensure that normal development can take place.

Lip wedging is noted when the lower lip is positioned palatally of the upper incisors. If present during swallowing, it may cause the maxillary incisors to protrude (Patti and D’Arc, 2005). Lip wedging can become a functional interference which may aggravate a Class II malocclusion that could have normalised during growth (Florman *et al.*, 2008). It is therefore important to treat it early, especially among children with an increased overjet.

### **1.5.2.2 Mechanical interferences**

A mechanical interference refers to any dental interference (premature contact) that causes the mandible to slide laterally or anteriorly (Patti and D’Arc, 2005). It is commonly found in the early mixed dentition and mostly involves the maxillary lateral or central incisors that are positioned in linguoversion (McIntyre, 2004). Any dental interference that causes the mandible to assume a position of convenience will have an effect on growth, if it is left untreated (Patti and D’Arc, 2005). A primary interference is seen as an interference caused by a primary tooth and a secondary interference is when the permanent tooth is causing the interference (Patti and D’Arc, 2005).

Midlines should be examined for any deviations, left or right, and one should also look for the presence of an anterior or posterior crossbite. These include looking at the maxillary midline in relation to the midsagittal plane (Proffit, 2013). The second step is to look at the mandibular midline in centric relation and then in centric occlusion, compared to the midsagittal plane (Proffit, 2013). If there is a mandibular shift in centric occlusion, left or right, and the midlines coincide with the midsagittal plane in centric relation, a mechanical interference is present (Patti and D’Arc, 2005).

If there is an anterior slide, a “Pseudo Class III” exists (Rabie and Gu, 2000a). In cases displaying a lateral slide with a unilateral crossbite, a “functional cross bite” is noted (Proffit, 2013). Pseudo Class III cases can have detrimental effects on the dental and skeletal growth of the patient (Patti and D’Arc, 2005; Proffit, 2013). The dental effects include retroclined upper incisors, proclined lower incisors, decreased mid-facial height and a retrusive upper lip (Rabie and Gu, 2000a). A



true skeletal Class III can develop as a result of compensatory growth in the condyles (Patti and D'Arc 2005).

Positive treatment outcomes have been shown when children with a Pseudo Class III are treated early in the mixed dentition phase (Rabie and Gu, 2000b). These include reduced mandibular displacement and creation of sufficient space for the other permanent teeth to erupt (Rabie and Gu, 2000b). It is therefore vitally important to treat a Pseudo Class III patient as early as possible, because if it is left untreated, it can lead to the development of a true skeletal Class III (Yelampalli, 2012).

A functional crossbite is often due to maxillary narrowing (Wong *et al.*, 2011). If left untreated, facial asymmetry (Pinto *et al.*, 2001) and TMJ problems (de Boer and Steenks, 1997) could develop. This could either be due to asymmetrical condylar growth or as a result of the patient sliding the jaw continually to one side (Pinto *et al.*, 2001). Thus early treatment is essential in order for normal function to occur (Cláudia *et al.*, 2011).

The patient should also be examined for the presence of soft tissue impingement and a deep bite (Proffit, 2013). In the mixed dentition stage, the overbite and overjet may increase as the permanent incisors erupt (Keski-Nisula *et al.*, 2003). It is therefore normal to have a slightly deeper bite at this stage (Patti and D'Arc, 2005).

However, a deep bite becomes significant when it is equal to or more than 3.5mm (Tausche *et al.*, 2004). A deep bite of 5mm or more is regarded as severe (Proffit, 2013). In these cases it is very likely that the deep bite will persist into the permanent dentition (Patti and D'Arc, 2005; Proffit 2013).

A deep bite can either be related to a skeletal or dental cause (Proffit 2013; Singla *et al.* 2013). Infra-occlusion, unerupted posterior teeth, early loss of teeth and over-eruption of the anterior teeth can also lead to the development of a deep bite (Proffit 2013; Singla *et al.* 2013).

Detrimental effects of a deep bite include TMJ problems (Darendeliler *et al.*, 2004), attrition of the anterior teeth, trauma and periodontal problems of the palatal gingiva of the upper incisors or the labial gingiva of the lower incisors (Singla *et al.*, 2013). A deep bite could also restrict the anterior development of the mandibular dento-alveolar process. This is difficult to treat later in life (Patti and D'Arc, 2005).

It is therefore vital that a deep bite related to dental causes be treated as soon as possible to prevent further problems. However, if it is the result of a skeletal problem, treatment becomes more complex and the condition is rarely treated within the mixed dentition stage (Proffit, 2013).

### **1.5.3 Problems hampering normal dental development**

#### **1.5.3.1. Poor oral hygiene**

Good oral hygiene is very important prior to the commencement of orthodontic treatment (Proffit, 2013). Signs of gingivitis and the presence of plaque on the teeth (Cameron and Widmer, 2008) should be noted.

#### **1.5.3.2. Dental caries and early loss of primary teeth**

All the teeth present should be examined for the presence of decalcifications, attrition, and dental caries (Cameron and Widmer, 2008). Severely carious teeth can affect the quality of life (Low *et al.*, 1999), by causing pain and abscess formation and loss of sleep and it may become life threatening if left untreated (Cameron and Widmer, 2008).

Any carious lesions should be treated before orthodontic treatment is started (Proffit, 2013). Untreated dental caries of primary teeth in the mixed dentition which affect the pulp can lead to dental extractions (Cameron and Widmer, 2008). This may result in shortening of the dental arch (Kerosuo, 2002) of up to 4mm (Hudson *et al.*, 2013).

If the mandibular primary canines are lost early, it can cause anterior collapse of the mandibular arch with subsequent collapse of the maxillary arch (Hudson *et al.*, 2011). This may cause crowding in the permanent dentition (Kerosuo, 2002;

Laing *et al.*, 2009), ectopic eruption (Flemming, 2008), impactions, crossbite formation and a midline shift (Laing *et al.*, 2009). Early loss of the second primary molar could result in a mesial drift of the permanent molar and it may either cause a Class II or III molar relationship (Rao, 2008).

#### **1.5.3.3 Dental and chronological age**

It is important to compare the dental and chronological age of a patient (Proffit, 2013). Small variations in the timing of eruption are considered normal (Proffit, 2013). However, changes in the sequence of eruption, delayed and asymmetrical eruption of teeth needs further examination (Patti and D'Arc, 2005; Proffit, 2013).

#### **1.5.3.4 Unfavourable sequence of eruption**

If one of the maxillary central incisors has been unerupted for 6 months or longer, but the contralateral tooth is fully erupted or if maxillary lateral incisors have erupted before the central incisors, it could be indicative of a dental problem (Patti and D'Arc, 2005; Proffit, 2013). These problems could have a negative impact on the normal development of occlusion (Patti and D'Arc, 2005; Proffit, 2013).

#### **1.5.3.5 Canine ectopia**

Buccal canine bulges should be palpated buccally with a finger to assess whether they are present or not (Proffit, 2013). The maxillary and mandibular canine bulges should be palpable at 9 years of age and its absence could indicate canine ectopia (Resh, 2005; Hudson *et al.*, 2010; Hudson *et al.*, 2011). It is therefore important that all children between the ages of 9 and 11 years be examined for canine bulges (Resh, 2005). Absence of these bulges warrants further investigation and radiographs should be taken (Shapira and Kufninec, 1998).

There are many possible co-inciding factors related to canine ectopia, including peg laterals, infra-occlusion of primary molars and rotated lateral incisors (Bacetti 1998). Other factors include retained primary teeth, enamel hypoplasia, ectopic eruption of the first permanent molars and dental malformations like taurodontism and dens invaginatis (Hudson *et al.*, 2010). If the maxillary primary canines are still present and immobile at the ages of 12 or 13 years, it could be a sign that the permanent successors are impacted (Hudson *et al.*, 2010).

#### **1.5.3.6. Asymmetrical mobility**

The presence of symmetrical mobility for the same contralateral primary tooth is very important for normal dental development. If both teeth are not mobile within 6 months of each other, asymmetrical mobility is present (Proffit, 2013). Asymmetrical mobility may lead to the loss of leeway space and drifting of the teeth with a resultant midline shift (Proffit, 2013).

#### **1.5.3.7. Bruxism**

Generalized attrition of the teeth could be a sign of bruxism at night (Cameron and Widmer, 2008). This should be discussed with the parent and a night guard could possibly be introduced to prevent further damage to the teeth (Proffit, 2013).

#### **1.5.3.8. Hyperactive frenum**

It is important that the frenulae of both the maxilla and the mandible be examined (Proffit, 2013). If blanching is noted in the attached gingiva between the central incisors, an active frenum is present (Proffit, 2013). A hyperactive frenum could result in a midline diastema and gingival recession (Delli *et al.*, 2013).

#### **1.5.3.9. Rotated lateral incisors**

The mandibular lateral incisor is found to be the most commonly rotated tooth in the mandible (Shapira and Kuflinec, 2002). Lateral incisors that are lingually displaced are not able to direct the permanent canines to erupt into the correct position (Hudson *et al.*, 2010). This leads to the mesial eruption of the permanent canines, overlapping of the lateral incisors, further loss of space and resultant crowding (Hudson *et al.*, 2010).

### **1.5.4 Skeletal discrepancies**

According to Proffit (2013), it is important to carefully examine the profile for facial and skeletal discrepancies that may be visible in an antero-posterior and vertical dimension. This is also regarded as the “poor man’s cephalometric analysis” as it may provide some information, though in less detail, when compared to the analysis of lateral cephalometric radiographs (Proffit, 2013).

Whenever a jaw irregularity is found, it is best to correct it by modifying the growth so that the skeletal problem may disappear as the child grows (Patti and D’Arc, 2005; Proffit, 2013).

The mixed dentition stage, just before puberty, is regarded as the time where most of the growth takes place and it is the ideal time to modify the growth (Patti and D’Arc, 2005; Proffit, 2013). It is therefore vital to ensure a correct diagnosis and treatment plan to allow normal growth to take place and minimize the need for complex dental and skeletal therapy.



## **CHAPTER 2: MATERIALS AND METHODS**

### **2.1 Aims**

The aim of the study is to investigate the need for interceptive orthodontic treatment among 7-to-10-year-old children attending dental clinics in the Tygerberg sub-district.

### **2.2 Objectives**

1. To determine the prevalence of malocclusion among 7-to-10-year-old children examined at the dental clinics within the Tygerberg sub-district.
2. To determine the types of malocclusion they present with.
3. To determine which of the malocclusions present in the sample of patients can be treated with interceptive orthodontic treatment.

### **2.3 Ethics**

Ethics approval, (reference number: 12/7/17), was obtained from the Research Committee of the Dentistry Faculty as well as the Senate Higher Degrees Committee of the University of the Western Cape.

### **2.4 Study sample.**

Permission was sought from the Department of Health (DOH) Western Cape in order to include five Government dental clinics within the Tygerberg sub-district in the study. These clinics included Bishop Lavis, Elsies River, Goodwood, Bellville and Delft. Unfortunately, clearance was only obtained for three clinics, namely, Bishop Lavis, Goodwood and Bellville. Goodwood was then excluded from the study sample as no children are treated at that dental clinic.

Children between the ages of 7 and 10 years were included in the study. Random dates were chosen and examinations took place on these days. Permission to visit each clinic was sought in advance. Each clinic was visited at least 5 times. As determined by a statistician, a hundred children were included in the study.

### **2.5 Research design**

An analytical, descriptive, cross-sectional study was carried out and quantitative methods were used to achieve the aim and objectives.

## **2.6 Inclusion and exclusion criteria**

All children between the ages of 7 and 10 years presenting at the clinics on the day of research visit were invited to participate in the study. Dental examinations were conducted on these children and their last birthday was taken as their existing age. Children younger than 7 years and above 10 years of age were excluded from the study, but no child was refused a consultation. Participation in the study was entirely voluntary and refusal to participate did in no way disadvantage the patients.

Written informed consent (Appendix A) was obtained from parents who attended the dental clinics with their children. In cases where the children were sent from a school, consent forms either signed by the parents or the principal of the school were brought by the children attending the dental clinic. All parents were advised as to the nature of the treatment their child needed and referred to the relevant facilities for treatment where necessary.

## **2.7 Data collection, instruments and materials**

Clinical data was collected using a prescribed form (Appendix B). The names and personal details of all the participants and their families were kept confidential at all times. All completed questionnaires and signed informed consent forms were placed into two separate boxes by the participants themselves and the names of the subjects were not mentioned on the data capture sheets. The boxes were sealed and only opened when all data had been collected. It was only handled by the examiner herself.

The informed consent forms, and data capture sheets will be kept in a locked cabinet (that only the examiner has access to) for a minimum period of three years.

Each intra-oral examination was done using gloves, a wooden tongue depressor and a disposable transparent ruler. The examination lasted approximately 10 minutes and was conducted prior to the children receiving dental treatment from the operating dentists.

### **2.7.1 Habits**

The parent and /or child was asked if the thumbsucking habit was present. The age until which this habit persisted was recorded where necessary. The child was considered to be a thumbsucker if he / she was still thumbsucking after the age of 4 years.

The presence of other habits like pencil biting, nail biting, dummy or biting the lower lip was also recorded.

A simple tongue thrust was associated with an anterior open bite from canine to canine which could be related to thumbsucking.

### **2.7.2 Functional interferences**

The mother and /or child was asked if he / she constantly breathed through the mouth during the day or night. If the habit was present, it was determined whether mouthbreathing was due to allergies (seasonal) or if it persisted for a long period of time (obstructive).

On examination, the extent of the open bite was assessed. Open bites extending beyond the canines, were associated with a complex tongue thrust.

Lip wedging was noted when the mentalis action was present in association with a large overjet.

### **2.7.3 Mechanical interferences**

Mechanical interferences (Pseudo Class III, functional crossbites and deep bites) were examined as defined in chapter 1. The overbite was measured by assessing the amount of overlap between the mandibular and maxillary central incisors. A deep bite was regarded as 3.5 mm or more and the reading in millimetres was recorded.

### **2.7.4 Dental development**

Please refer to the chapter 1 with regards to dental development and related dental age.



“Normal dental development” was noted when the dental age corresponded with the chronological age. “Accelerated dental development” was regarded when the dental age was ahead of the chronological age. If dental age was delayed when compared with chronological age, it was regarded as “delayed dental development”.

The mobility of the primary teeth was examined and teeth that were near exfoliation were noted. If equal mobility was noted in the contralateral tooth, it was regarded as being “symmetrically” mobile. If only one tooth was mobile or had recently exfoliated and the other tooth was not, “asymmetrical mobility” was noted.

Retained teeth were seen when the teeth were still present in the mouth, but according to the dental age, should have exfoliated. Only erupted supernumery teeth could be diagnosed as no radiographs were available.

#### **2.7.5 Maxillary permanent central incisors**

During examination, the presence of erupted maxillary central incisors was evaluated. Delayed eruption of one or both of the maxillary central incisors was noted when they were absent at the age of 7 years.

Midline diastemas and dental age are discussed in chapter 1. Diastemas larger than 2 mm were noted as “enlarged”. The absence of an expected midline diastema at 9 years of age was noted, as it can play a role in the canine development.

The presence of an active frenum was examined, by pulling the upper and lower lips away from the teeth. If blanching was noted in the attached gingiva between the central incisors, an “active frenum” was recorded. If blanching was absent, it was considered “normal”.

If one or both maxillary central incisors were lingually positioned with regards to the lower incisors, a crossbite was noted. The position of both the maxillary central incisors was viewed in relation to the other anterior teeth. A rotation was

present if one (or more) central incisors had distal or mesial aspects that were displaced relative to the shape of the dental arch.

### **2.7.6 Maxillary lateral incisors**

The different dental ages are discussed in chapter 1. When the maxillary lateral incisors were missing after the age of 8 years, the tooth was considered “absent”. It was difficult to know if they were delayed, congenitally missing or had possibly been extracted as no radiographs were available.

During examination, the size and shape of both the maxillary lateral incisors in relation to the maxillary central incisors were evaluated. In cases where the lateral incisors had an unusually small size and shape, it was considered to be a peg lateral; otherwise it was considered “normal”.

The position of both the maxillary lateral incisors in relation to the other anterior teeth was examined for rotations. In cases where one or both of the maxillary lateral incisors were lingually positioned with regards to the lower incisors, a crossbite was noted.

### **2.7.7 Mandibular incisors**

The alignment and crowding of the mandibular incisors were examined. If they were well-aligned, it was regarded as “normal”; otherwise it was recorded as “crowded”. The lateral incisors were examined in relation to the mandibular central incisors and were either categorised as “well-aligned, lingually placed or rotated”.

### **2.7.8 Canines**

The presence of canines related to dental age is discussed in chapter 1. When the primary canines had been lost before the expected normal exfoliation time, “early loss” was noted.

The presence of canine bulges in both arches was noted by palpating the areas where the canine bulges should be. All subjects were checked for buccal canine bulges. In cases where the buccal canine bulge was not palpable the canine was considered ectopic.

### **2.7.9 Posterior teeth**

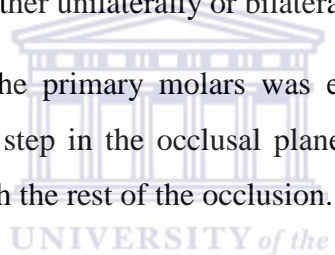
The first permanent molar relationship was examined and noted under different categories. Either “unable”, (when one or both of the molars was missing) “Class I, cusp-to-cusp (“end to end”), Class II, or Class III”.

In cases where the molar relationship was not a “cusp-to-cusp Class II”, it was considered to be an “unfavourable molar relationship”.

If one or more primary molars were missing before the normal expected exfoliation age, the patient was considered to have had “early loss of posterior teeth”.

When the buccal surface of the upper permanent posterior teeth occluded palatally in relation to the buccal surface of the lower permanent posterior teeth, a posterior crossbite was recorded either unilaterally or bilaterally.

The occlusal plane of the primary molars was examined. Infra-occlusion was noted when a definitive step in the occlusal plane was present and the primary molar was not in line with the rest of the occlusion.



### **2.7.10 Restorations and untreated gross interproximal caries**

All tooth surfaces were examined for the presence of restorations and untreated gross interproximal caries.

### **2.7.11 Need for interceptive orthodontic treatment**

At the end of each examination, all the above-mentioned facts were considered. If one or more of the factors were present, the patient was considered to need interceptive orthodontic treatment. Patients requiring treatment were provided with a letter informing the parent of the child’s treatment need, so that the patient could be assessed orthodontically.

## **2.8 Data Processing and Analysis**

Information recorded on the data capture sheets was transferred to an Excel spreadsheet which contains no personal details. All the information was kept on a password protected computer, to which only the examiner had access. Only the

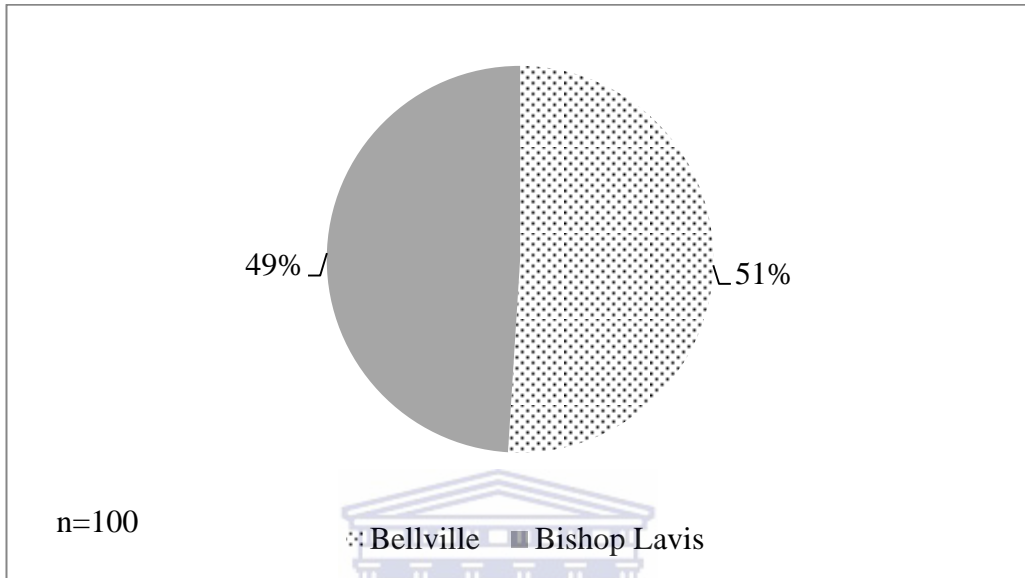
researcher and supervisors were eligible to view identifiable data. Anonymity was thus diligently preserved.

The analyses of the results were done by a statistician using a program cited as the “R Development Core Team (2012). R: A language and environment for statistical computing. R foundation for statistical Computing, Vienna, Austria. ISBN 3-900051-07-0.”

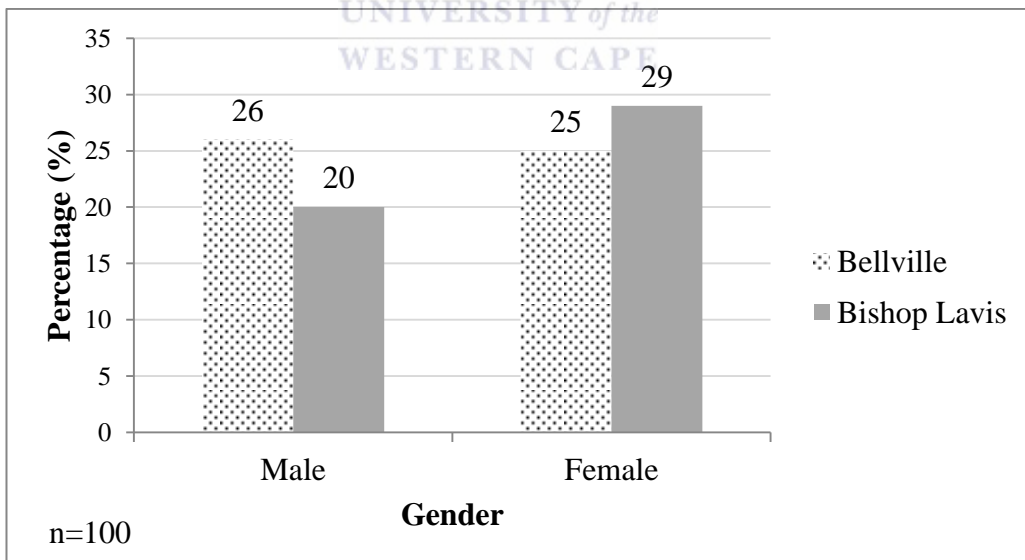


## **CHAPTER 3: RESULTS**

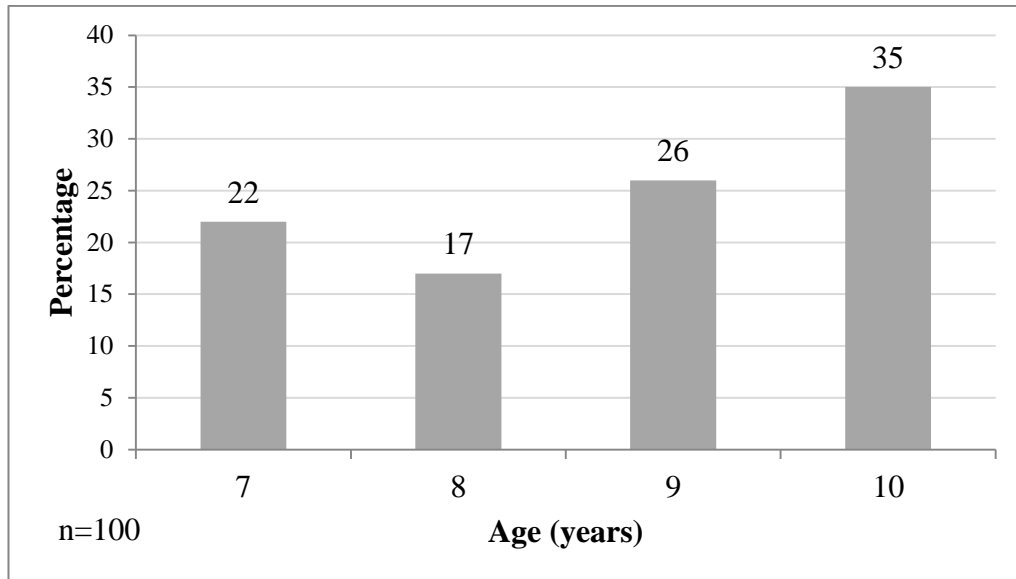
### **3.1 Demographics**



**Figure 3.1.1 Children examined at dental clinics**




**Figure 3.1.2 Gender distribution at both clinics**



**Figure 3.1.3 Age distribution at clinics**

### **3.2 Habits**



**Table 3.2.1 Habits present**

Habits	Girls	Boys	Total (%)
Thumbsucking	16%	5%	21%
Tongue thrust (simple open bite)	9%	5%	14%
Other habits:	19%	16%	35%
Lower lip biting	1%	0%	1%
Nail biting	12%	10%	22%
Pencil biting	5%	6%	11%
Pencil and nail biting	1%	0%	1%

A significant relationship was found between gender and habits (Chi-squared test,  $p=0.04$ ).

### 3.3 Interferences

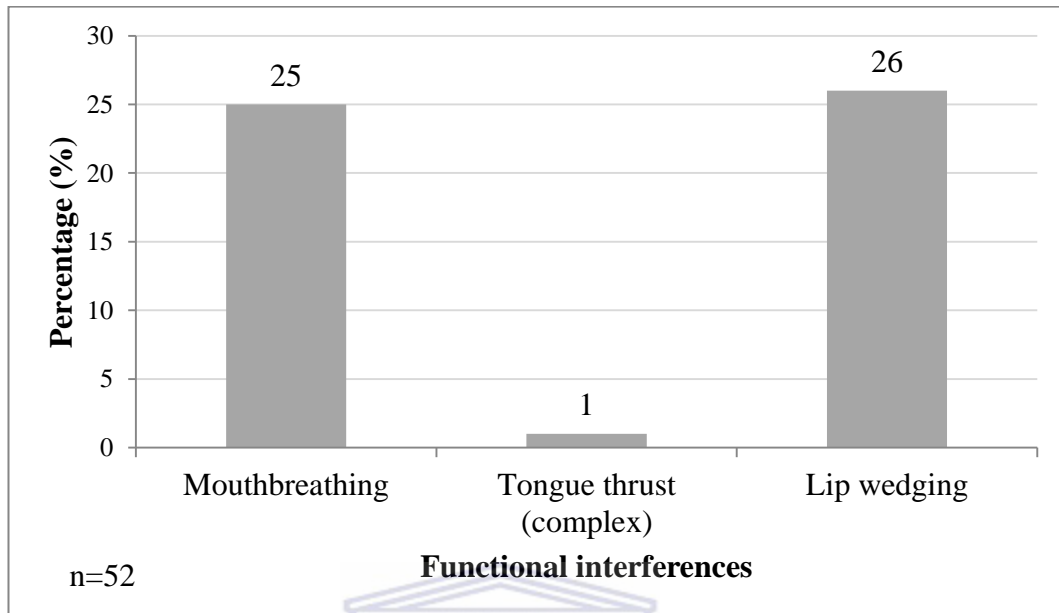


Figure 3.3.1 Functional interferences

Mouthbreathing was found to be 15% obstructive and 10% seasonal.

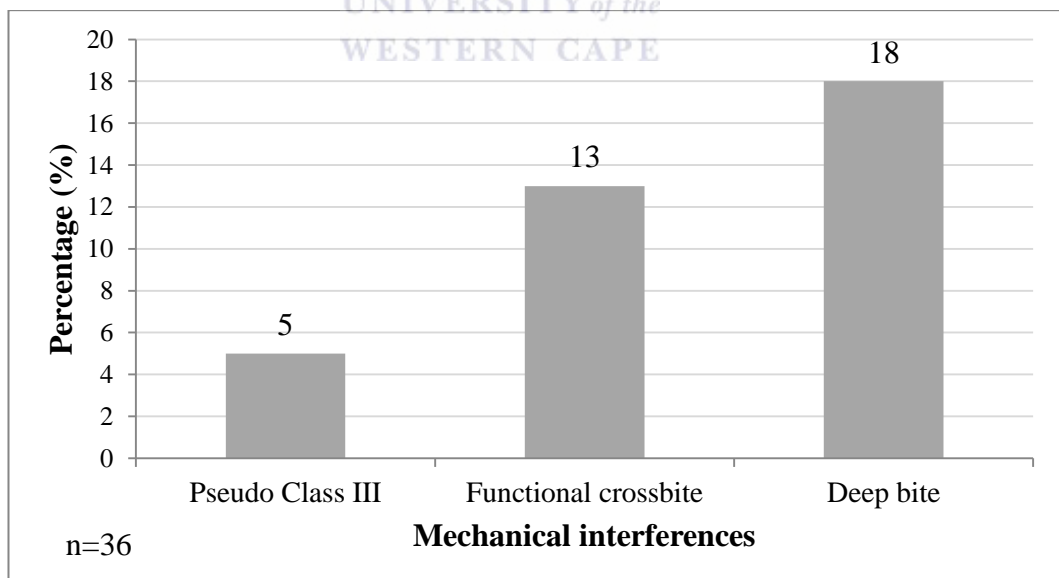
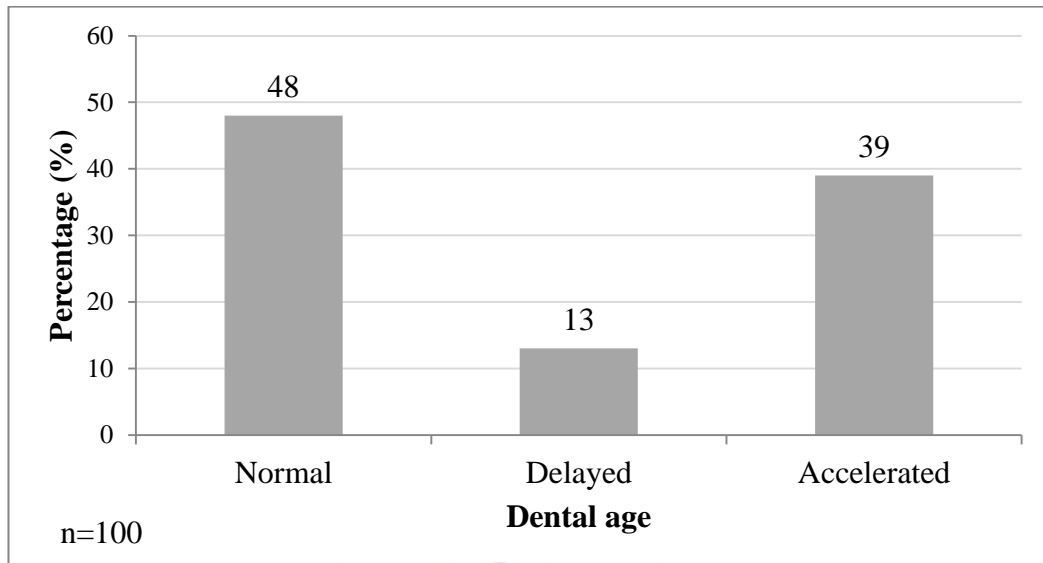


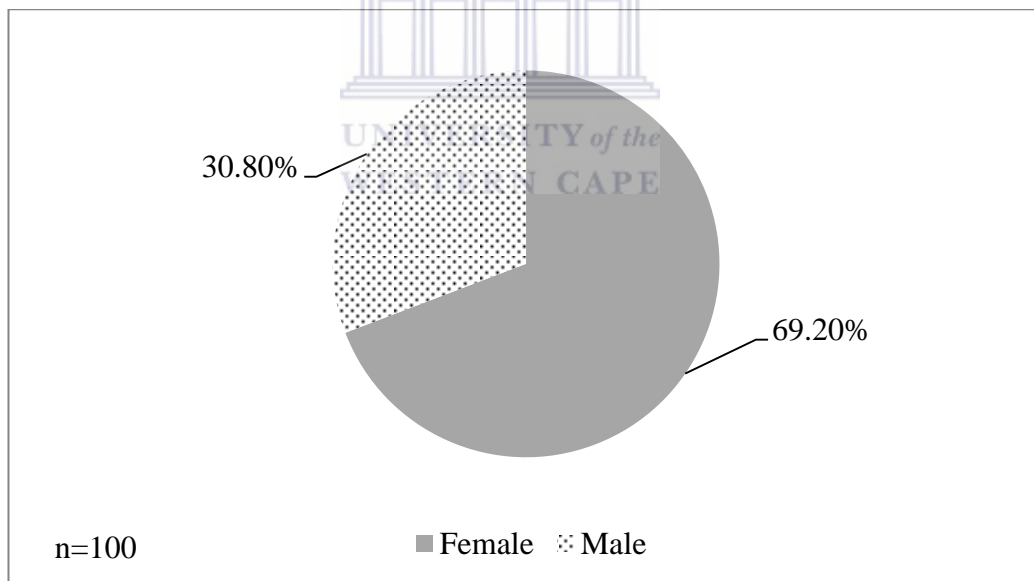
Figure 3.3.2 Mechanical interferences

A small percentage of (3%) of Pseudo Class III cases were due to primary interferences and 2% were due to secondary interferences.

### 3.4 Dental development



**Figure 3.4.1 Dental versus chronological age**



**Figure 3.4.2 Gender distribution versus accelerated growth**

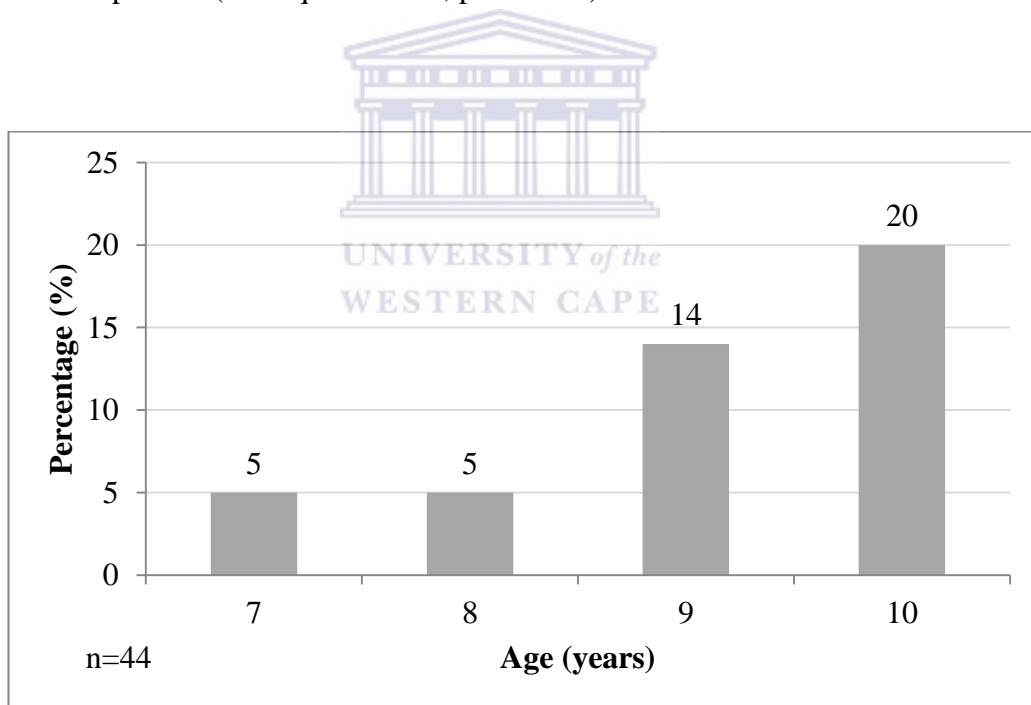
A statistically significant relationship (Chi-squared Test,  $p= 0.0145$ ), was found between gender and accelerated dental age.



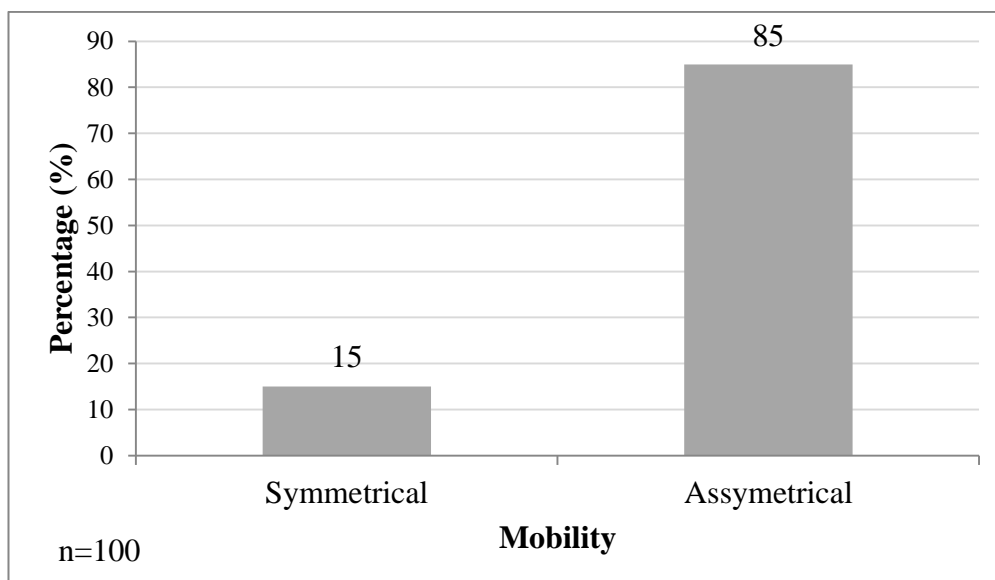
**Table 3.4.1 Gender distribution versus premature canines present**

Age (years)	Girls	Boys	Total (%)
7	0%	0%	0%
8	3%	0%	3%
9	10%	0%	10%
10	13%	8%	21%
<b>Total</b>	26%	8%	34%

A statistically significant relationship, was found between gender and premature canines present (Chi-squared Test,  $p= 0.0012$ ).



**Figure 3.4.3 Early loss of primary canines**



**Figure 3.4.4 Mobility of primary teeth**

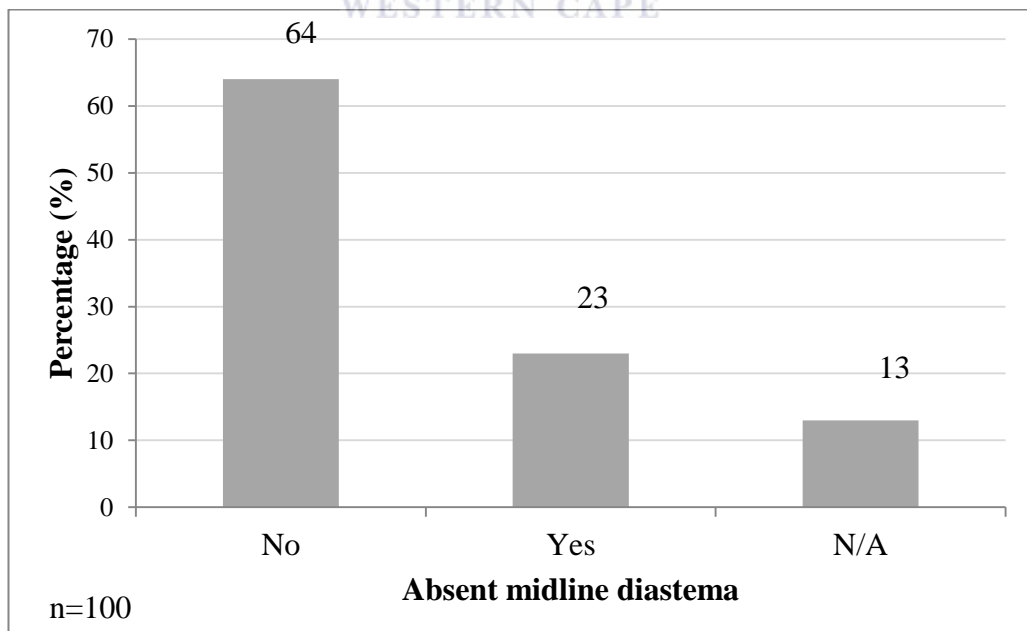
Retained primary teeth were present in 6% of cases and no infra-occlusion or supernumery permanent teeth or were noted.

**Table 3.4.2 Eruption pattern of incisors**

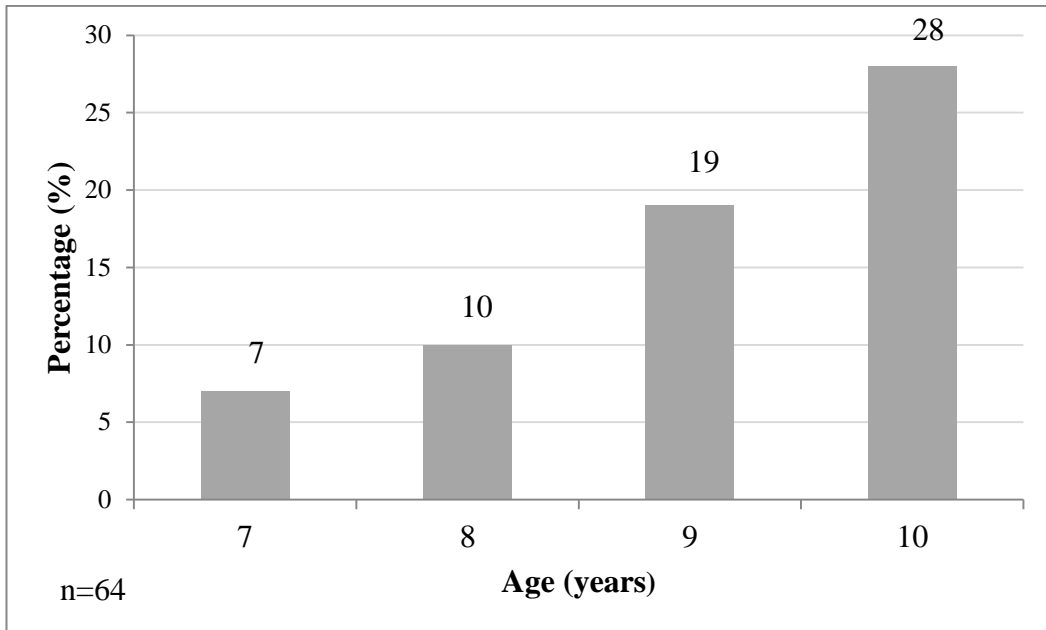
	Percentage
<b>Maxillary central incisors:</b>	
Normal	95.6%
Delayed	4.4%
<b>Maxillary lateral incisors:</b>	
Normal	72%
Unerupted (age 7)	19%
Unerupted (age 8)	6%
Congenitally missing (age 9 and 10)	3%

**Table 3.4.3 Alignment of anterior teeth**

<b>Rotations present:</b>	<b>Percentage</b>
<b>Maxillary central incisors</b>	
Normal	84.5%
Rotated	15.4%
<b>Maxillary lateral incisors</b>	
Normal	42.5%
Rotated	57.5%
<b>Mandibular anterior crowding</b>	38%
<b>Mandibular lateral incisors</b>	
Normal	74.7%
Lingually positioned	7.3%
Rotated	18%

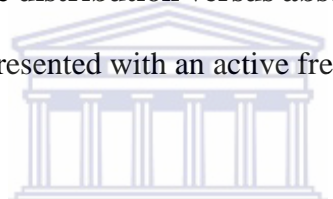


**Figure 3.4.5 Presence of midline diastemas**



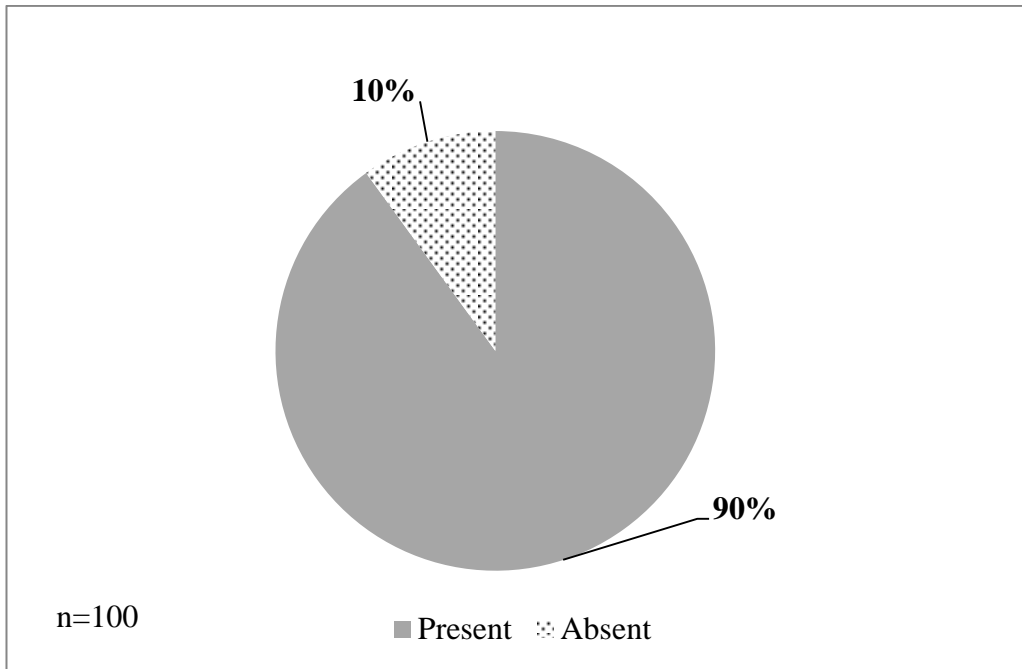
**Figure 3.4.6 Age distribution versus absent midline diastemas**

Only 1% of the sample presented with an active frenum.



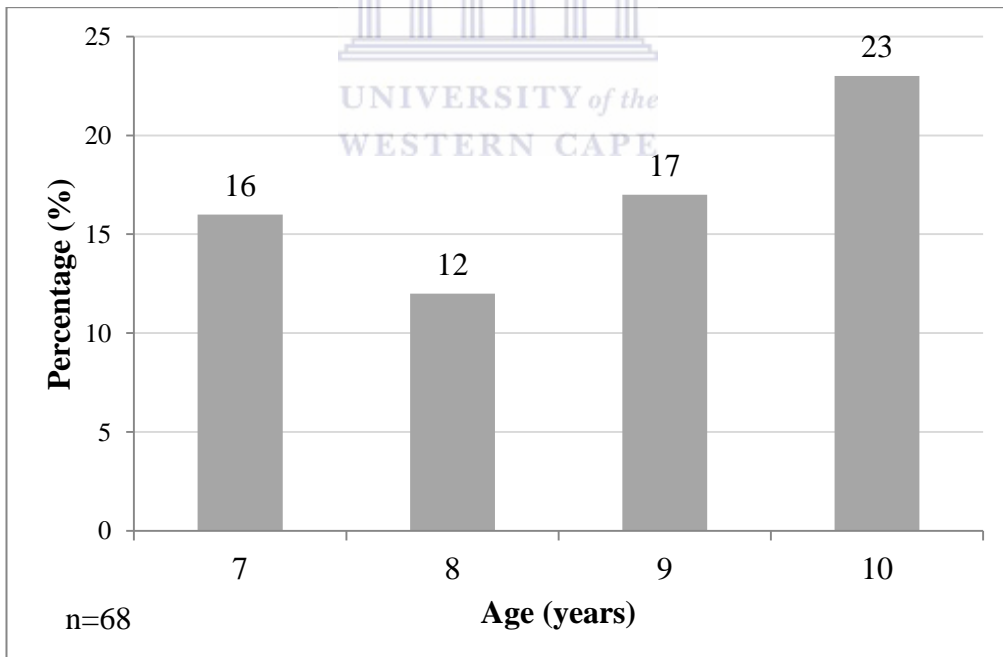
**Table 3.4.4 Dental crossbites**

	Percentage
<b>Total Anterior crossbites</b>	16%
Maxillary central incisors	4%
Maxillary lateral incisors	12%
<b>Posterior crossbites</b>	17%

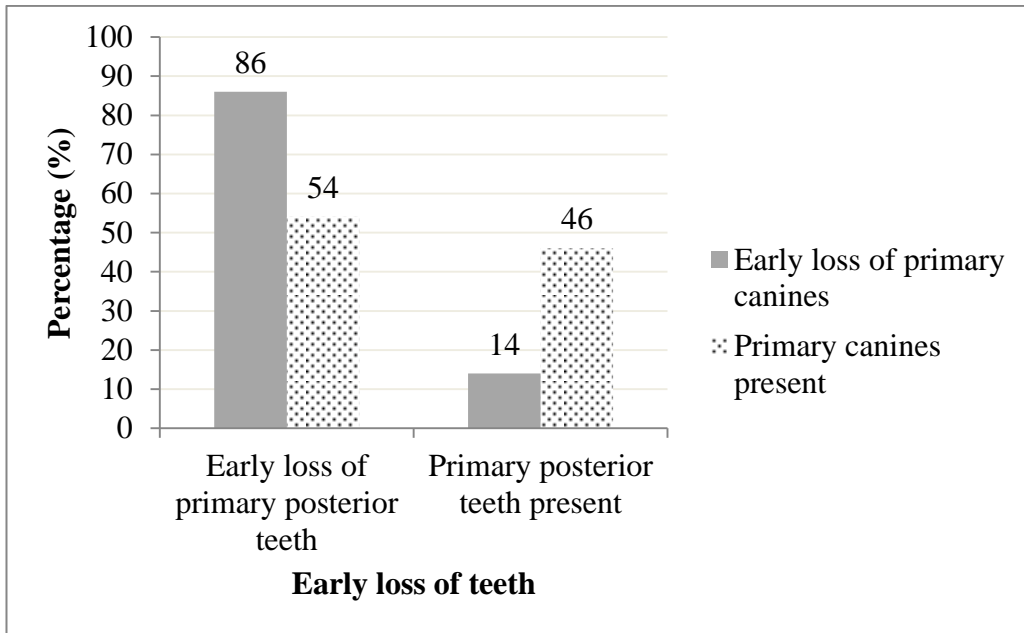


**Figure 3.4.7 Untreated gross interproximal caries**

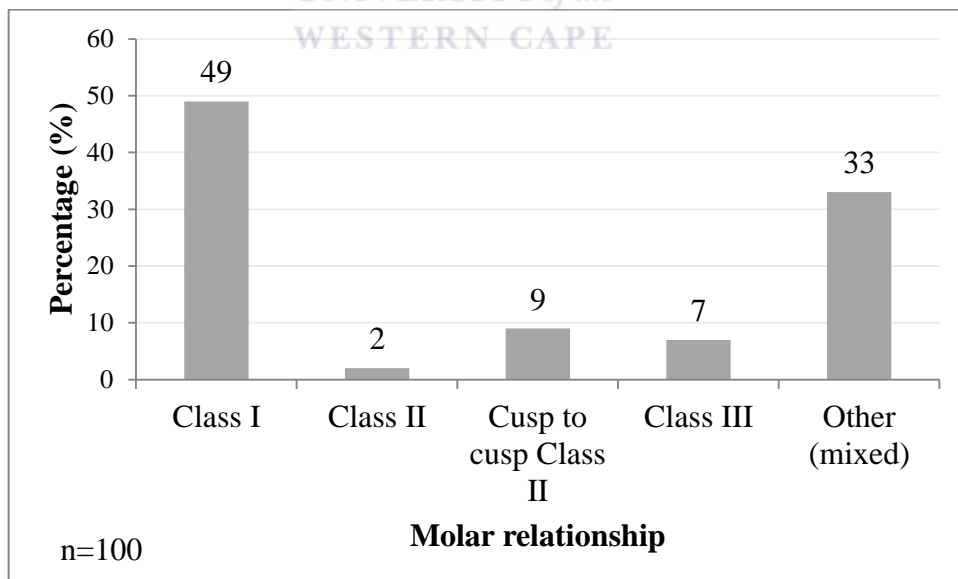
Only 5% of the sample received restorations or fissure sealants.



**Figure 3.4.8 Early loss of posterior teeth**

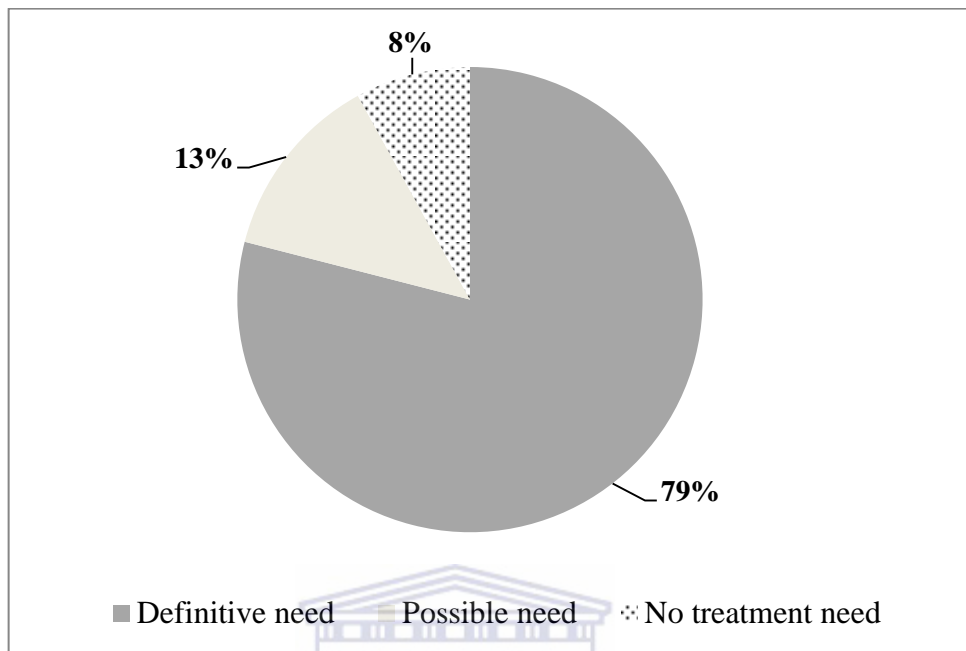


**Figure 3.4.9 Early loss of primary canines versus early loss of posterior teeth**  
 Overall loss of primary teeth were 71% and a highly statistically significant relationships between the early loss of primary canines and early loss of primary posterior teeth (Chi-squared test,  $p=0.0005$ ).

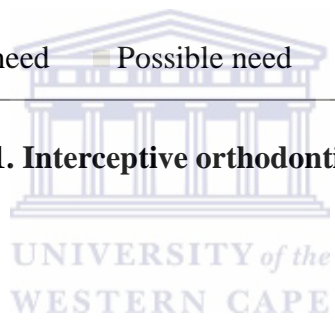


**Figure 3.4.10 Distribution of molar relationships**

### 3.5 Interceptive orthodontic treatment need



**Figure 3.5.1. Interceptive orthodontic treatment need**



## **CHAPTER 4: DISCUSSION**

### **4.1 Demographics**

An even distribution of children was seen between the clinics of Bellville and Bishop Lavis (Figure 3.1.1), with an almost equal number of boys and girls seen (Figure 3.1.2).

A third of the sample was 10 years of age, followed by 9-year-olds and 7-year-olds. The smallest number of children fell into the 8-year-old category (Figure 3.1.3).

### **4.2 Habits**

The present study showed a significant relationship ( $p=0.04$ ) between gender and habits present, where thumbsucking was more prevalent among girls than boys (Table 3.2.1). This interesting result is also supported by other studies (Mtaya *et al.*, 2009; Kharbanda *et al.*, 2013; Leme *et al.*, 2013).

Studies have recorded a statistically significant relationship between thumbsucking and other habits (Shetty and Munshi, 1998; Thomaz *et al.*, 2013). However, even though it was not statistically significant in the present study, it was evident that a large percentage of other habits was present (Table 3.2.1). The present study found no statistically significant difference between gender and other habits, but Thomaz *et al.* (2013) found girls to be at significantly higher risk for persisting with other habits.

Kharbanda *et al.* (2013) found tongue thrust to be the most common habit in their study (18.1%). However, in the present study it was less common than thumbsucking (Table 3.2.1). Girls were found to be 1.54 times more likely to have a tongue thrust (anterior open bite) than boys, but this result is not statistically significant (Table 3.2.1). This is supported by literature (Kharbanda *et al.*, 2013).

In the present study, it was found that children who thumbsucked were 1.5 times more likely to have an anterior open bite. This finding was supported by Mtaya *et al.* (2009), who found that girls who thumbsucked were 1.9 times more likely to develop an anterior open bite than boys.



Shetty and Munshi (1998) found a statistically significant relationship between tongue thrust and mouthbreathing. However, this was not confirmed in the present study. The present study found no statistically significant difference with the following:

- tongue thrust present and early loss of teeth
- thumbsucking and a complex tongue thrust present.

### **4.3 Interferences**

#### **4.3.1. *Functional interferences***

A total of 52% of the present sample presented with functional interferences, lip wedging (26%), mouthbreathing (25%), followed by a complex tongue thrust (1%) (Figure 3.3.1).

Kharbanda *et al* (2013) found mouthbreathing to be significantly more prevalent among boys than girls. However, in the present study this was not statistically significant. In a study by Oulis *et al* (1994), a strong association was reported between mouthbreathing in children with enlarged adenoids and tonsils, and the presence of a posterior crossbite (47%). However, in the present study no statistical difference was found between the two.

The present study found no statistically significant relationship between:

- mouthbreathing and lip wedging
- mouthbreathing and complex tongue thrust

Lip wedging (Figure 3.3.1) was present in a quarter of the sample, which is very high compared to other studies. Tausche *et al* (2004) reported that 6.1% of children had an increased overjet and lip wedging. The present study found no statistically significant relationship between lip wedging and mandibular crowding. A complex tongue thrust was also found to be an insignificant value (Figure 3.3.1).

### **4.3.2. Mechanical interferences**

In the present study, mechanical interferences occurred in 36% of the sample examined. Deep bites were the most common, followed by functional crossbites and Pseudo Class III cases (Figure 3.3.2). No statistical significant relationship was found between a deep bite and early loss of teeth.

Tausche *et al* (2004) found a deep bite (46.2%) and an increased overjet (37.5%) to be the most frequent discrepancies in children between 6 and 8 years of age. Proffit (2013) stated that significant deep bites affect approximately 20% of children in the mixed dentition. This correlates to the large percentage found in the current study (Figure 3.3.2), which found no significant difference between gender and a deep bite present.

In the present study just over a tenth of the sample presented with a functional crossbite (Figure 3.3.2) and, as mentioned in chapter 1, it is vital that treatment be started as soon as it is diagnosed. No statistically significant difference was found between gender and functional crossbites in the current sample. However, girls were found to be 1.4 times more likely to have a functional crossbite than boys.

The present study found only a small percentage of children presenting with a Pseudo Class III malocclusion (Figure 3.3.2) which is consistent with the average of 7.1% found by de Mûelenaere (1995). The detrimental effects of Pseudo Class III malocclusions is discussed in chapter 1.

## **4.4 Dental development**

The present study compared dental age to chronological age according to Proffit (2013). Almost half of the sample presented with normal development, while more than a third had accelerated development. A relatively low percentage of delayed eruption (Figure 3.4.1) was present.

When gender was compared to accelerated growth, a statistically significant relationship ( $p= 0.0145$ ) was found. Girls were twice as likely to have accelerated growth than boys (Figure 3.4.2).

In a third of the sample, permanent canines were present prematurely (Table 3.4.1). This directly influenced the large prevalence of accelerated growth. When the sample was stratified according to age, the majority of permanent canines were present among the 9 and 10-year-old children with a low prevalence among the 8-year-olds. The absence of permanent canines was noted among children in the 7-year-old category (Table 3.4.1).

It was interesting to find a highly statistically significant relationship ( $p= 0.0012$ ), between gender and premature canines present (Table 3.4.1). Girls were 2.7 times more likely to present with premature permanent canines than boys. This may relate to the results from Van Wyk and Drummond (2005) who found that malocclusion is more common in boys than in girls. The large percentage of premature canines present in the current study may be linked to the large prevalence of early loss of primary canines (Figure 3.4.3). Ishiguro (1990) found that children with early loss of primary teeth presented with earlier eruption of the permanent teeth, compared to children with normal exfoliation.

In the present study, mobility of the primary teeth was mostly asymmetrical and only a small portion presented with symmetrical mobility (Figure 3.4.4). Retained primary teeth was only found in 6% and no cases of infra-occlusion of primary teeth and supernumerary permanent teeth were found.

The present study also found most of the maxillary central and lateral incisors to have a normal eruption pattern i.e. eruption was not delayed (Table 3.4.2). However, the age of normal eruption should be kept in mind as 19% of the sample consisted of 7-year-olds with unerupted lateral incisors.

The present study found that most of the maxillary central incisors had no rotations present, however more than half of the maxillary lateral incisors and 18% of the mandibular lateral incisors were rotated (Table 3.4.3). This is clinically relevant, as it has been shown that rotated lateral incisors could indicate possible canine ectopia (Hudson *et al.*, 2010). However, no statistical difference was found between maxillary rotated lateral incisors and absent maxillary canine bulges.

The present study found no statistically significant relationship between:

- mandibular lateral rotations and the absence of mandibular canine bulges
- anterior crossbite and the presence of a posterior crossbite
- mandibular incisor crowding and mandibular canine bulges present.

Canine bulges were found in 1% of cases in the maxilla and 8% of the sample presented with no mandibular canine bulges. This included 7% of 8-year-old children. As mentioned in chapter 1, canines should be palpable from 9 years of age. Canine ectopia would therefore not apply to the 8-year-old children. The low prevalence of canine ectopia is mostly attributed to the large percentage of the permanent canines which have already erupted.

In the present study, the majority of children had no midline diastema present (Figure 3.4.5). Midline diastema were absent in almost three-quarters of 9-to 10-year-olds and a quarter were between the ages of 7 and 8-years (Figure 3.4.6).

The large percentage of midline diastemas absent in the 9-and 10-year-old group could be related to the large number of premature permanent canines present. However, the absent midline diastema in the 7-and 8-year-old group is an important finding. Proffit (2013) stated that midline diastemas should be present in the mixed dentition stage and disappear only once the permanent maxillary canines have erupted. Absence of a midline diastema at this age could indicate dental crowding in the permanent dentition (Patti and D'Arc, 2005).

In the present study, no significant relationship was found between midline diastema present and an active frenum present, as only 1% of the sample presented with an active frenum.

Both anterior and posterior crossbites were noted in the study population (Table 3.4.4). No statistically significant relationship was found between gender and posterior crossbites. Girls were however twice as likely to have a posterior crossbite. As mentioned earlier, thumbsucking is related to the development of a posterior crossbite and in the present study, more girls thumbsucked. This could clarify the higher number of posterior crossbites among them. No statistically

significant difference was found between an anterior crossbite and mandibular crowding; however, the relative risk was 1.5 times higher to have both present.

Kennedy and Osepchok (2005) states that a posterior crossbite is often associated with a functional shift. In the present study, 4% of the posterior crossbites presented with functional shifts.

Luzzi *et al* (2011) demonstrated that gross interproximal caries could result in loss of arch length. This is consistent with the findings of the present study, where an alarmingly high percentage of the children presented with gross untreated interproximal caries (Figure 3.4.7). Only 5% of children presented with restorations or preventive fissure sealants. No statistically significant relationship was found between untreated gross interproximal caries and an unfavourable molar classification. The detrimental effects of untreated gross dental caries are mentioned in chapter 1.

The present study showed a very large proportion of both early loss of primary canines (Figure 3.4.3) and primary molars (Figure 3.4.8). An overall loss of 71% of children presented with early loss of primary teeth. A highly statistically significant relationship (Figure 3.4.9) was found between early loss of primary canines and early loss of primary posterior teeth ( $p=0.0005$ ). This is directly related to the fact that the children presented with very poor oral hygiene and the low priority of restorative and preventive treatment at the clinics to address the problem.

When the early loss of primary teeth was compared to an unfavourable molar relationship strong associations were evident, but it was not statistically significant. The results showed that 42 of the 44 children (Figure 3.4.3) that had early loss of primary canines and 62 of the 68 who presented with early loss of primary molars (Figure 3.4.8) presented with an unfavourable molar relationship.

As mentioned in chapter 1, only a small percentage of children in the mixed dentition should present with a Class I molar relationship and most of them should have a normal cusp-to-cusp Class II molar relationship. The present study found an alarmingly high percentage of Class I and mixed molar relationships present,

with only a small percentage of cusp-to-cusp Class II present (Figure 3.4.10). The reason for the large Class I and mixed molar relationships are related to the high prevalence of early loss of primary teeth and resultant loss of leeway space (as mentioned in chapter 1).

These results show that urgent intervention is necessary, as the early loss of primary teeth due to untreated dental caries and premature extractions leads to the development of malocclusion.

#### **4.5 Interceptive orthodontic treatment need**

The present study perceived a very large interceptive orthodontic treatment need (79%) and possible need (13%) among children of the Tygerberg sub-district (Figure 3.5.1). Only a small number of children had normal occlusion and did not require any interceptive orthodontic treatment. This correlates with the results by Mûelenaere (1997), where 97% of a sample of 493 children presented with malocclusion.

Another study conducted in the public health sector of the United States has found that interceptive orthodontic treatment significantly reduces the need for complex, fixed orthodontic treatment (Jolley *et al.*, 2010). They suggested that if treatment was done in the mixed dentition, more patients could receive treatment and that less financial strain would be placed on the government funded systems (Jolley *et al.*, 2010).

#### **4.6 Limitations of the study**

##### ***4.6.1 Not all the children were accompanied by their parents***

As many parents had not accompanied their children, they could not be questioned about the children's thumbsucking habits or dental history.

When the children were asked about their thumbsucking and other habits, not all of them were aware of having had these habits during their earlier years and therefore the numbers could be higher.

Most of the children that presented with early loss of primary teeth were unaware at what age the teeth were lost. It was therefore difficult to know whether the 9- and-10-year-old children where primary canines were absent, could truly be classified as having had “spontaneous early loss of primary teeth.” The results are however significant in the 7-to-8 year age group, because early loss at this stage (as mentioned in chapter 1) could cause malocclusion.

#### ***4.6.2 No additional diagnostic aids were used***

As no radiographs were taken in this study, congenitally missing incisors, supernumerary teeth, canine ectopia and other dental anomalies could not be verified.

Without the radiographs and study models, it was also difficult to diagnose and confirm skeletal discrepancies.

#### ***4.6.3 Small sample size***

Although the required sample size was projected by a statistician, in retrospect it seems as though the sample of 100 was too small.

A larger sample size would have generated more significant results. Despite this, the huge impact of early loss of teeth on the development of malocclusion was evident, as a strong relationship was demonstrated between early loss of primary teeth and an unfavourable molar relationship.

## **CHAPTER 5: CONCLUSION AND RECOMMENDATIONS**

The study succeeded in answering the aims and objectives and demonstrated the enormous problem of malocclusion among children in the study population. Personal communication with the resident dentists at both clinics revealed that challenges would have to be overcome before interceptive orthodontic treatment could be provided at these dental clinics. These include an effective and efficient laboratory system which could make the appliances. Additional staff is also needed to cope with the demand for treatment.

These dentists are willing to provide interceptive orthodontic treatment on the condition that the above mentioned factors, together with the provision of the necessary equipment and orthodontic refresher courses are made available.

A major problem that was highlighted in the study was the presence of poor oral hygiene, grossly untreated dental caries and the lack of preventive and conservative treatment at these clinics to address it. The Bellville clinic was the only facility where children with fissure sealants and restorations were seen. More effort and resources should be made available to implement prevention at these community oral health centres. If the problem of poor oral hygiene and dental caries is addressed early enough, the prevalence of malocclusion would also decrease in this area.

Urgent intervention is needed from the Department of Health to address these problems, as interceptive orthodontic treatment should be seen as a primary health care service. Not only would the treatment be beneficial for the children of low socioeconomic status, but it would also lift the burden currently placed on the TOHC to provide complex fixed orthodontic treatment at a later stage. This in turn will help alleviate the growing waiting lists.



## REFERENCES

- Andersen, W.S., (1963). The relationship of the tongue-thrust syndrome to maturation and other factors. *American Journal of Orthodontics*; 49(4):264-275.
- Bacetti, T., (1998). A controlled study of associated dental anomalies. *Angle Orthod*; 68:267-274.
- Basdra, E.K, Kiokpasoglou, M., Stellzig, A., (2000). The Class II division 2 craniofacial type is associated with numerous congenital tooth anomalies. *Eur J Orthod*; 22(5):529-535.
- Bhalajhi, S.I., (2004). *Orthodontics 3<sup>rd</sup> Edition*. ARYA(MEDI) Publishing house. 63-80.
- Bresolin, B., Shapiro, P.A., Shapiro, G.G., Chapko, M.K., Dassel, S., (1983). Mouth breathing in allergic children: Its relationship to dentofacial development. *American Journal of Orthodontics*; 83(4):334–340.
- Cameron, A.C. and Widmer, R.P., (2008). *Handbook of Pediatric Dentistry*. 3<sup>rd</sup> Edition. Elsevier limited, Chapter 11.
- Cláudia, A., Chibinski, R., and Czlusniak, G.D., (2011). Evaluation of treatment for functional posterior crossbite of the deciduous dentition using Planas' direct tracks. *Indian Journal of Dental Research*, 22(5).
- Coetzee, C.E. and Wiltshire, W.A., (2000). Occlusal and oral health status of a group of 3-8-year-old South African black children. *SADJ*; 55: 252-258.
- Darendeliler, N., Dinçer, M., Soyulu, R., (2004). The biomechanical relationship between incisor and condylar guidances in deep bite and normal cases. *Journal of Oral Rehabilitation*; 31(5):430-437.
- De Boer, M., and Steenks, M.H., (1997). Functional unilateral posterior crossbite. Orthodontic and functional aspects. *Journal of Oral Rehabilitation*; 24: 614-623

Defabjanis, P., (2003). Impact of nasal airway obstruction on dentofacial development and sleep disturbances in children: preliminary notes. *J Clin Pediatr Dent.*; 27(2):95-100.

Delli, K., Livas, C., Sculean, A., Katsaros, C., Bornstein, M.M., (2013). Facts and myths regarding the maxillary midline frenum and its treatment: A systematic review of the literature. *Quintessence Int*; 44:177–187.

de Mûelenaere, K.R. and Wiltshire, W.A., (1995). The status of the developing occlusion of 8-9 year-old children from a lower socio-economic group in a developing country. *Journal of the D.A.S.A*, 50(3), 113-118.

de Mûelenaere, K.R., (1997) Possibilities for prevention of malocclusions in South African children. *SADJ*; January, 52, 9-14.

Dixit, U.B., and Shetty, R.M., (2013). Comparison of soft-tissue, dental, and skeletal characteristics in children with and without tongue thrusting habit. *Contemporary Clinical Dentistry*; 4(1):2-6.

Faria, P.T., de Oliveira Ruellas A.C., Matsumoto M.A., Anselmo-Lima W.T., Pereira FC., (2002). Dentofacial morphology of mouth breathing children. *Braz DentJ*; 13(2):129-32.

Fleming, P.S., Johal, A. and DiBiase, A.T., (2008a). Managing Malocclusion in the Mixed Dentition: Six Keys to success Part 1. *Dent Update*; 35: 607-613.

Fleming, P.S., Johal, A. and DiBiase, A.T., (2008b). Managing Malocclusion in the Mixed Dentition: Six Keys to success Part 2. *Dent Update*; 35: 673-676.

Florman, M., Veis, R., Alarabi, M., Alarabi, M., (2008). Diagnosing Early Interceptive Orthodontic Problems — Part 2. *RDH*, 28(4):1-14.

Graber, T.M., Chung, D.D.B. and Aoba, J.T. (1969). Tongue thrust in pre-school. *Am J Orthod*; 56:60-69.

Harari, D., Redlich, M., Miri, S., Hamud, T., Gross, M., (2010). The effect of mouth breathing versus nasal breathing on dentofacial and craniofacial development in orthodontic patients. *The Laryngoscope*; 120(10): 2089–2093.

Hlongwa, P. and du Plessis, J.B., (2005). Malocclusion among 12-year-old school children in Mankweng, Limpopo Province of South Africa. *SADJ*; 60(10): 455-457.

Hudson, A.P.G., Harris, A.M.P., Mohamed, N., (2009). The mixed dentition pantomogram: A valuable dental assessment tool for the dentist. *SADJ*; 64(10): 480-483.

Hudson, A.P.G., Harris, A.M.P., Mohamed, N., (2010). Maxillary canine management in the pre-adolescent: A guideline for general practitioners. *SADJ*; 65(8):366-370.

Hudson, A.P.G., Harris, A.M.P., Mohamed, N., (2011). Early identification and management of mandibular canine ectopia. *SADJ*; 64(10): 462-467.

Ishiguro, H., (1990). Effect on the development of permanent successors due to the extraction and non-extraction of infected deciduous teeth. *Aichi Gakuin Daigaku Shigakkai Shi*; 28(1 Pt 1):93-121.

Jolley, C.J., Huang, G.J., Greenlee, G.M., Spiekerman, C., Kiyak, H.A., King, G.J., (2010). Dental effects of interceptive orthodontic treatment in a Medicaid population: Interim results from a randomized clinical trial. *Am J Orthod Dentofacial Orthop*; 137(3): 324-333.

Joondeph, R., (1993). Early orthodontic treatment. *Am J Orthod Dentofacial Orthop*; August 199-200.

Kerosuo, H. (2002). The role of prevention and simple interceptive measures in reducing the need for orthodontic treatment. *Med Princ Pract*; 11 Suppl. 1:16-21.

Kennedy, D.B., and Osepchok, M., (2005). Unilateral Posterior Crossbite with Mandibular Shift: A Review. *Can Dent Assoc*; 71(8):569–73.

Keski-Nisula, K., Letho, R., Lusa., Keski-Nisula, L., Varrela, J., (2003). Occurrence of malocclusion and need of orthodontic treatment in early mixed dentition. *American Journal of Orthodontics and Dentofacial Orthopedics*, 631-638.

Kharbanda, O.P., Sidhu, S.S., Sundaram, K.R., Shukla, D.K., (2003). Oral habits in school going children of Delhi: A prevalence study. *Indian Soc Pedo Prev Dent*; 21(3):120 – 124.

Khinda, V., and Grewal, N., (1999). Relationship of tongue-thrust swallowing and anterior open bite with articulation disorders: a clinical study. *Journal of the Indian Society of Pedodontics and Preventive Dentistry*; 17(2):33-39.

King, G.J., and Brudvik, P., (2010). Effectiveness of interceptive orthodontic treatment in reducing malocclusions. *Am J Orthod Dentofacial Orthop*; 137(1): 18- 25.

Laing, E., Ashley, P., Naini, F.B., Gill, D.S., (2009). Space maintenance. *International Journal of Paediatric Dentistry*; 19: 155-162

Leme, M.S., Barbosa, T., D.S., Gavião, M.B.D., (2013). Relationship among oral habits, orofacial function and oral health related quality of life in children. *Braz Oral Res.*, (São Paulo); 27(3): 272-278.

Low, W., Tan, S., Schwartz, S., (1999). The effect of severe caries on the quality of life in young children. *Pediatric Dentistry*; 21(6):325-326.

Luzzi, V., Fabbrizi, M., Coloni, C., Mastrantoni, C., Mirra, C., Bossù, M., Vestri, A., Polimeni, A., (2011). Experience of dental caries and its effects on early dental occlusion: a descriptive study. *Annali di Stomatologia*; II (1-2): 13-18.

McIntyre, G.T., (2004). Treatment planning in Class III malocclusion. *Dent Update*; 31: 13-20.

Michael, G., and Arvystas, B.A., (1998). The rationale for early orthodontic treatment. *Am J Orthod Dentofacial Orthop*; 113(1):15-18.

Mahony D., Karsten A., Linder-Aronson S., (2004). Effects of adenoidectomy and changed mode of breathing on incisor and molar dentoalveolar heights and anterior face heights. *Aust Orthod J*; 20(2):93-8.

Mirabelli, J.T., Huang, G.J., Siu, C.H., King, G.J., and Omnelle, L., (2005). The effectiveness of phase I orthodontic treatment in a Medicaid population. *Am J Orthod Dentofacial Orthop*; 127:592-598.

Moss, M.L., and Rankow, R.M., (1968). The Role of the Functional Matrix in Mandibular Growth. *Angle Orthod*; 38:95-103.

Moss, M.L., (1997). The functional matrix hypothesis revisited. *Am J Orthod Dentofac Orthop*; 112:8-11, 221-226, 338-342, 410-417.

Moyers R.E., (1988). *Handbook of orthodontics*. 4<sup>th</sup> ed. USA: Year book medical publishers, 152-155, 544-550.

Mtaya, M., Brudvik, P., Åström, A.N., (2009). Prevalence of malocclusion and its relationship with socio-demographic factors, dental caries, and oral hygiene in 12- to 14-year-old Tanzanian schoolchildren. *European Journal of Orthodontics*; 31: 467–476.

Oulis, C.J., Vadiakas, G.P., Ekonomides, J., Dratsa, J., (1994). The effect of hypertrophic adenoids and tonsils on the development of posterior crossbite and oral habits. *J Clin Pediatr Dent.*; 18(3):197-201.

Patti, A., and D'Arc, G.P., (2005) *Clinical success in Early Orthodontic Treatment*. Paris: Quintessence International; 7-8, 24-32.

Pinto, A.S., Peter H. Buschang, P.H., Throckmorton, G.S., Patrick Chen, P., (2001). Morphological and positional asymmetries of young children with functional unilateral posterior crossbite. *American Journal of Orthodontics and Dentofacial Orthopedics*; 120(5):513-520.

Principato J.J., (1991). Upper airway obstruction and craniofacial morphology. *Otolaryngol Head Neck Surg*; 104(6):881-90.

Proffit, W.R., (2006). The timing of early treatment: An overview. *Am J Orthod Dentofacial Orthop*; 129:S47-9.

Proffit, W., Fields, H.W., Sarver, D.M., (2013). *Contemporary Orthodontics 5<sup>th</sup> Edition*. Elsevier 2-15, 46-50, 73-90, 133-145, 403, 415, 441-442.

Rabie, A.B.M., and Gu, Y., (2000a). Diagnostic criteria for pseudo-Class III malocclusion. *Am J Orthod Dentofacial Orthop*; 117(1):1-9.

Rabie, A.B.M., and Gu, Y., (2000b). Dental changes and space gained as a result of early treatment of pseudo-Class III malocclusion. *Aust Orthod J*; 16(1):40-52.

Rao, A., (2008). *Principles and practice of pedodontics*. 2<sup>nd</sup> ed. India: Jaypee, 61, 70-76, 122-160.

Resh, G.D., (2005). Diagnosis and prevention of maxillary cuspid impaction. *Int J Orthod Milwaukee*; 16:29-34.

Shapira, Y., and Kuflinec, M.M., (1998). Early diagnosis and interception of potential maxillary canine impaction. *JADA*; 129:1450-1454.

Shapira, Y., and Kuflinec, M.M., (2002). Intrabony migration of impacted teeth. *Angle Orthod*; 73:738-43.

Shetty S.R., and Munshi, A.K., (1998). Oral habits in children - a prevalence study. *J Indian Soc Pedod Prev Dent*; 16(2):61-6.

Singh G., (2007). *Textbook of orthodontics*. 2<sup>nd</sup> ed. New Delhi: Jaypee, 175-200, 557-579.

Singh, S.P., Utreja, A., Chawla, H.S., (2008). Distribution of malocclusion types among thumb suckers seeking orthodontic treatment. *J Indian Soc Pedod Prevent Dent*; S114-S117.

Singla, R., Singla, N., Madhumitha N., (2013). Management of deep overbite. *GUIDENT*, August; 40-44.

- Stojanović, L., (2007). Etiological aspects of anterior open bite. *Med Pregl*; 60(3-4):151-5.
- Tanaka, O.M., Vitral, R.W.F., Tanaka, G.Y., Guerrero, A.P., Camargo, E.S., (2008). Nailbiting, or onychophagia: A special habit. *American Journal of Orthodontics and Dentofacial Orthopedics*; 134(2):305-308.
- Tausche, E., Luck, O., Winfried, H., (2004). Prevalence of malocclusions in the early mixed dentition and orthodontic treatment need. *European Journal of Orthodontics*, 26(3):237-244.
- Tewari, A., (1970). Abnormal oral habits: Relationship with malocclusion and influence on anterior teeth. *J Indian Dent Assoc*; 42:81-84.
- Thomaz, E.B.A.F., Cangussu, M.C.T., Assis, A.M.O., (2013). Malocclusion and deleterious oral habits among adolescents in a developing area in north eastern Brazil. *Braz Oral Res.*, (São Paulo); 27(1):62-69.
- Urzal, V., Braga, A.C., Ferreira, A.P. (2013). The prevalence of anterior open bite in Portuguese children during deciduous and mixed dentition--correlations for a prevention strategy. *Int Orthod*; 11(1):93-103.
- Van Wyk, P.J., and Drummond, R.J., (2005). Orthodontic status and treatment need of 12-year-old children in South Africa using the Dental Aesthetic Index. *SADJ*; 60(8):334-339.
- Wong, C.A., Sinclair P.M., Keim R.G., and Kennedy D.B., (2011) Arch dimension changes from successful slow maxillary expansion of unilateral posterior crossbite. *Angle Orthodontist*; 81(4): 616-623.
- Yamaguchi, H., Sueishi, K., (2003). Malocclusion associated with abnormal posture. *Bull. Tokyo dent. Coll.* 4(2): 43-54.
- Yelampalli, M.R., Rachala, M.R., (2012). Timely management of developing class III malocclusion. *J Indian Soc Pedod Prev Dent*; 30(1):78-84.

# APPENDIX A

## WRITTEN INFORMED CONSENT (Parents)

### Information Sheet and Consent to Participate in Research

---

My name is Dr. Amanda Marais, and I am an MSc student from the Paediatric department of the University of the Western-Cape.

You are being invited to consider enrolling your child in a study that involves research on the interceptive orthodontic treatment need amongst children attending dental clinics in the Tygerberg sub-district.

The aim and purpose of this research is to find out what the need is for interceptive orthodontics amongst children attending these clinics so that systems can be put in place for patients to receive this type of treatment at their local clinics instead of just at the Tygerberg Oral Health Centre.

The study is expected to enrol a minimum of 100 children between the ages of 7-to-10 years and will involve the following procedures:

A clinical examination will be done of your child's mouth using a disposable tongue-depressor stick. A transparent ruler might be used to measure the distance between the top and bottom teeth. The study will only take about 10 to 15 minutes of your time.

The study does not involve any risks and/ or discomforts for the participants. Participation in this study is entirely voluntary and the names and personal details of participants will be kept confidential at all times. The parent and/or child may refuse to be examined at any time and will not be disadvantaged in any way. In such a case, the parent and/or child must tell the examiner that they do not want to continue with the study and the examination will be stopped immediately. None of their information will be used for the study.

The examination will be free of charge and no child will be turned away, even if the child does not participate in the study. Your child can still be referred to the Tygerberg Oral Health Centre if he/ she is in need of orthodontic treatment. No form of compensation will be given for participation.



This study has been ethically reviewed and approved by the UWC Senate Biomedical Research Ethics Committee (12/717).

In the event of any problems or concerns, you may contact the researcher at nr: 021 9373106, email: [2382354@uwc.ac.za](mailto:2382354@uwc.ac.za) or supervisors of the study: Dr. Athol Hudson, Orthodontic department, telephone nr 0219373104, email: [apghudson@uwc.ac.za](mailto:apghudson@uwc.ac.za); Dr. Nadia Mohamed, Paediatric department, telephone nr 0219373073, email: [namohamed@uwc.ac](mailto:namohamed@uwc.ac))

**I ..... have been informed about the study entitled (interceptive orthodontic treatment need amongst children attending dental clinics in the Tygerberg sub-district) by Dr. Amanda Marais.**

I understand the purpose and procedures of the study.

I have been given an opportunity to ask questions about the study and have received answers to my satisfaction.

I declare that my participation in this study is entirely voluntary and that I may withdraw my child at any time without affecting any treatment or care that he/ she would usually be entitled to.

If I have any further questions/concerns or queries related to the study I understand that I may contact the researcher at (021 9373106, email: [2382354@uwc.ac.za](mailto:2382354@uwc.ac.za)).

If I have any questions or concerns about my rights as a study participant, or if I am concerned about an aspect of the study or the researchers then I may contact:

**DENTISTRY RESEARCH ETHICS COMMITTEE**

**Research Office, Tygerberg Campus**  
**Francie van Zyl Drive**  
Private Bag X1  
Tygerberg  
7505  
Cape Town, SOUTH AFRICA

Tel: 27 21 937 3095 - Fax: 27 21 931 2287

---

**Signature of Participant**

---

**Date**

---

**Signature of Witness**  
**(When applicable)**

---

**Date**

---

**Signature of Translator**  
**(When applicable)**

---

**Date**






**Maxillary central incisors:**

Eruption	<b>Normal</b>	<b>Delayed</b>
Midline diastema	<b>N Y:</b>	<b>enlarged _____mm</b>
Frenum	<b>Normal</b>	<b>active</b>
Cross bite:	<b>N Y:</b>	<b>which teeth: _____</b>
Rotations:	<b>N Y:</b>	<b>which teeth: _____</b>

**Maxillary lateral incisors**

Present / absent: _____	Congenital / unerupted ?		
Size shape	<b>Normal</b>	<b>Peg</b>	
Rotations:	<b>N Y:</b>	<b>L</b>	<b>R</b>
Palatoversion / cross bite:	<b>N Y:</b>	<b>which teeth: _____</b>	



**Mandibular incisors**

Crowding	<b>N Y:</b>	<b>&lt; 5mm</b>	<b>&gt; 5mm</b>
Lateral incisors	<b>well aligned</b>	<b>lingually placed</b>	<b>rotated</b>

**Canines**

Early loss of C's:	<b>N Y:</b>	<b>which teeth: _____</b>		
Too early for buccal canine bulges	<b>N Y</b>			
Bulges present	<b>Mx</b>	<b>N Y:</b>	<b>L</b>	<b>R</b>
	<b>Md</b>	<b>N Y:</b>	<b>L</b>	<b>R</b>

**Posterior teeth**

Molar (6) class:      Unable    I    cusp to cusp II      II      III

Early loss:            N      Y:    which teeth: \_\_\_\_\_

Cross bite:            N      Y:    which teeth: \_\_\_\_\_

Infra occlusion:      N      Y:    which teeth: \_\_\_\_\_

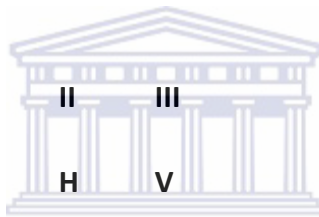Restorations:        N      Y:    which teeth: \_\_\_\_\_

Untreated gross interproximal caries:      N      Y:  
which teeth: \_\_\_\_\_

**Skeletal appearance**

Class            I            II            III

Growth          N            H            V



Is this patient's malocclusion suitable for interceptive orthodontic treatment?

Y      N      M