

Reliability of panoramic radiographs to determine the vertical position of the impacted third molar root tip from the inferior alveolar canal.

A mini-thesis submitted for the qualification in
Master of Science in Maxillofacial Radiology (5807)

By

Azizah Ahmad Fauzi (3204868)

Department of Oral and Maxillofacial Radiology, Faculty of Dentistry,
UNIVERSITY of the
University of Western Cape

(2013).

Supervisor: Prof. Mohamed Ebrahim Parker.

Co-supervisors: Dr. E J Norval,

Contents

ABSTRACT.....	4
LIST OF FIGURES	5
LIST OF TABLES	6
1. INTRODUCTION	7
2. LITERATURE REVIEW	8
2.1 The incidence of impacted mandibular third molar and its relationship to the inferior alveolar canal.....	8
2.2 Radiation dose comparison between panoramic radiography, medical computed tomography and cone beam computed tomography.	9
2.3 Overview of various radiographic approaches in the assessment of third molar to inferior alveolar canal.....	10
2.4 Indication of cone beam computed tomography in relation to impacted third molar removal.....	13
2.5 The accuracy of panoramic radiography versus cone beam computed tomography.	14
2.6 Measurement of vertical position of third molar in relation to its adjacent structure. ...	16
3. AIM AND OBJECTIVES OF STUDY	17
3.1 Aim of study.....	17
3.2 Specific Objective	17
4. MATERIAL AND METHODS.....	18
4.1 Data collection.....	18
4.2 Ethic clearance	19
4.3 Data analysis	19
4.4 Statistical analysis	21

5. RESULTS.....	22
6. DISCUSSION.....	28
7. CONCLUSION	32
8. REFERENCES	33
9. APPENDICES	36



ABSTRACT

Nowadays, the availability of radiographic modalities from conventional radiography to more advanced approaches such as medical computed tomography as well as cone beam computed tomography have been useful in providing insights of relevant anatomy prior to surgical procedures. The increased popularity of cone beam computed tomography has prompted interest in the utility of this approach for diagnostic application in dentistry, including the assessment of the proximity of impacted mandibular third molars to the inferior alveolar canal. It is important to understand the reliability of conventional panoramic radiograph in the assessment of this criterion since it is more commonly used as first line radiographic approach due to its availability and lower radiation dose. This study is aimed to investigate the reliability of conventional panoramic radiograph in the evaluation of the proximity of impacted mandibular third molar root tip to the inferior alveolar canal by correlating the results with cone beam computed tomography. A retrospective study of forty nine patients who underwent panoramic radiography as well as cone beam computed tomography for examination of impacted mandibular third molars was conducted. Two observers were participated in all image evaluation. In this study, both observers recorded statistically significant differences in the measurement of the apices of vertically impacted third molars and the inferior alveolar canal from panoramic radiographs and cone beam computed tomography images. The low reliability of panoramic radiograph to assess the vertical proximity between these two anatomical structures suggests the importance of additional assessment with cone beam computed tomography in cases where panoramic radiograph shows superimposition of the third molar root on the roof of the canal, presence of root below the roof of the canal and presence of bone height of less than one millimetre separating the third molar from the inferior alveolar canal.

LIST OF FIGURES

	Page
Figure 1: Three panoramic reconstructed slices which are created with one millimetre distance between each slice.....	36
Figure 2: A cropped panoramic radiograph which is magnified at 500% in the Microsoft Word's spread sheet.....	37
Figure 3: The standardize position of the magnified one centimetre ruler used in this study relative to the roof of the inferior alveolar canal	38
Figure 4: A cropped panoramic image with the standard ruler (the area bounded within blue line in Figure 3) after subsequent image magnification.....	39
Figure 5: A cropped panoramic radiograph which shows presence of root within the inferior alveolar canal.....	41
Figure 6: A cropped cone beam computed tomography panoramic reconstruction slice of the same patient in Figure 5 which shows superior position of the molar root tip away from the inferior alveolar canal.....	42
Figure 7: A plot of X and Y axes employed to compare cone beam computed tomography image measurements by 1 st observer (cbct1) versus the panoramic radiograph measurements counterpart (pan1).....	25
Figure 8: A plot of X and Y axes employed to compare measurements on panoramic radiographs by 1 st observer (pan1) versus 2 nd observer (pan2).....	26
Figure 9: A plot of X and Y axes employed to compare measurements of cone beam computed tomography images by 1 st observer (cbct1) versus 2 nd observer (cbct2).....	27

LIST OF TABLES

Table 1: A table which is used to record the distance between mandibular third molar root apex and the roof of inferior alveolar canal from panoramic radiographs and cone beam computed tomography images.....	40
Table 2: A table of data which presents the vertical position of 65 mandibular third molar root apices in relation to the roof of inferior alveolar canal, from panoramic radiographs and cone beam computed tomography images.....	24
Table 3: A table of seven radiological markers on panoramic radiograph which describe the likelihood of inferior alveolar canal being superimposed or intruded by mandibular third molar.....	43

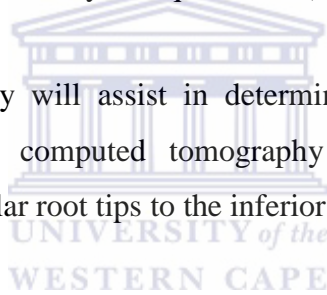


1. INTRODUCTION

Precise assessment of the position and proximity to the neurovascular bundle contained in the inferior alveolar canal of impacted mandibular third molars is important prior its surgical removal. Many complications are associated with removal of impacted mandibular third molar teeth, and this includes injury to inferior alveolar nerve. Impairment of this nerve will result in a sensory disturbance of the lower lip and chin of the affected side up to the midline. Preoperatively, it is important to evaluate the proximity of the molar root tips to the inferior alveolar canal. This will assist in the determination of the difficulty in the removal of the third molar, and provide detailed information to the operator in explaining to the patient the possible post-operative risk of alveolar nerve damage and complications.

This study investigates the proximity of the mandibular third molar root tip to the inferior alveolar canal in conventional panoramic radiographs as well as cone beam computed tomography with a method described by Bouquet et al (2004). This method is modified in order to suit our aim of this study.

The results from the study will assist in determining the reliability of panoramic radiographs versus cone beam computed tomography in assessing the pre-operative relationship of impacted third molar root tips to the inferior alveolar canal.



2. LITERATURE REVIEW

2.1 The incidence of impacted mandibular third molar and its relationship to the inferior alveolar canal.

A tooth which fails to erupt into its normal position and is confined in the alveolar bone is described as an impacted tooth (Stedman's Medical Dictionary, 2005). Impacted third molars are common, with a reported prevalence of between 23% to 65% (Snyder, 2007). In a study by Chu et al (2003), third molar impaction was far more common in the mandible than in the maxilla.

An important anatomical structure in relation to the mandibular third molar is the inferior alveolar canal (IAC) and its contents. The IAC is a tube of dense bone, which can be seen radiographically as two parallel radiopaque lines. The superior radiopaque line represents the roof of the IAC, whereas the inferior one corresponds to the canal floor. Within this IAC lies the inferior alveolar nerve and blood vessels.

The relationship of the third molar root tips to the IAC is variable and can be classified into two main categories (Neugebauer et al, 2008). The first category describes the vertical relationship between the mandibular third molar roots and the inferior alveolar canal. Within this category, the position of the molar root tips in relation to the canal can be either above, touching or below the roof of the canal. The second category which describes the horizontal relationship is used to assess bucco-lingual position of the root tips relative to the IAC.

When assessing the vertical relationship between molar root tips and the IAC on a conventional radiograph, presence of root intrusion into the canal or even superimposition of the root tip on the roof of the canal have been described to increase the risk of inferior alveolar nerve injury (Rood and Nooraldeen Shehab, 1990).

2.2 Radiation dose comparison between panoramic radiography, medical computed tomography and cone beam computed tomography.

When selecting an imaging modality for diagnostic purpose in the head region, it is important to consider not only the image quality but also the amount of radiation dose attributed to the various types of maxillofacial imaging examinations. In 1991, the International Commission on Radiological Protection proposed the calculation of the effective dose in order to estimate damage from radiation to an exposed population. Effective dose represents the dose to the total body that would constitute the same risk of summarized health detriment to the exposure received by a reference person (Snyder, 2007).

Pauwels et al (2012) reported that the effective radiation dose of a vast range of cone beam computed tomography scanners were between 19 μSv and 368 μSv . With the maxillary and mandibular volumes in medical computed tomography, the effective dose may range from 280 μSv to as high as 1410 μSv (SEDEXCT, 2011). For conventional panoramic radiography, a review of the literature from SEDEXCT collaborative research project (2011) showed that the effective dose associated with this diagnostic modality ranged between 2.7 μSv and 25 μSv . Thus, the radiation dose from cone beam computed tomography is generally higher than conventional panoramic radiography, but still significantly lower than medical computed tomography.

It is also important to point out that the radiation dose of cone beam computed tomography varies substantially depending on the field of view selected. The field of view (FOV) is a cylindrical volume which determines the size and shape of cone beam computed tomography reconstructed image. It may vary from a few centimetres height and diameter to a full head reconstruction. The size of FOV can be classified as large, medium or small FOV. According to Ludlow and Ivanovic (2008), when the diameter or height of the volume exceeds 15 centimetres, it is considered as a large field of view. For a small field of view, the diameter or height of the volume is less or equal to 10 centimetres, whereas, the intermediate range is considered as medium field of view. It has been reported by SEDEXCT (2011) that the average effective dose associated with a large FOV is 149 μSv . This differs from the average effective dose of medium and small FOV which is given as 101 μSv and 54 μSv respectively. Therefore, when performing cone beam computed tomography imaging in relation to an impacted third

molars, the smallest FOV compatible with the situation is recommended in order to lessen the radiation burden to the patient.

2.3 Overview of various radiographic approaches in the assessment of third molar to inferior alveolar canal.

There are several radiographic approaches which have been used for preoperative assessment of the relationship between the roots of mandibular third molar to the inferior alveolar canal (Ghaemina et al, 2009). Panoramic radiography has been used as a common diagnostic modality in dentistry, including the assessment of the impacted mandibular third molar. Like other conventional radiographs, this imaging modality suffers from image magnification, superimposition and distortion (Eraso et al 1997, Hassan 2010).

There are two types of image magnification associated with panoramic radiographs, namely vertical and horizontal magnification. In general, the amounts of the horizontal and vertical magnification vary at different rates within the image layer. The displacement of the object away from the focal plane of the image layer will result in variability of the image magnification factor either in vertical or horizontal directions.

By comparing the vertical magnification with the horizontal magnification, the variability of vertical magnification is lesser in the panoramic radiography. For example, the amount of magnification factor of PC-1000 panoramic machine ranges from 1.21 to 1.36 vertically and 1.07 to 1.71 horizontally within the image layer (Eraso et al, 1997). This is because the vertical magnification is related to the distance between the X-ray source and the focal plane of the image layer which is relatively constant even when the X-ray source is moved. Horizontal magnification is related to the centre of rotation, which is the point around which the X-ray source and the cassette holder rotate. The rotational movement of the X-ray source and the cassette holder results in a continuous movement of the centre of rotation in a sliding path. Consequently, the position of the centre of rotation becomes indefinite during panoramic image acquisition. Therefore, the horizontal magnification not only varies in terms of the patient position within the image layer but also varies from point to point on the image (Snyder, 2007).

Image layer of panoramic radiograph or also known as focal trough is a horse shoe shaped zone which is bounded by acceptable resolution limit at 1.5 lp / mm (Welander et

al, 1989). Using the average dental arch as a guide, the width of the image layer can be determined. Different panoramic units do not necessarily have a similar size of an image layer, since the average dental arch followed by different manufacturers varies. In case of mandibular third molars, the width of the image layer in this region as measured by various panoramic units varies between 13 and 26 millimetres (Snyder, 2007). The predetermined image layer according to the average size of the dental arch is a drawback in panoramic machine. This is because of the fact that not every patient has the size and shape of the mandible which can fit the average dental arch that has been fixed on the panoramic unit. Deviation in the size and shape of an individual jaw from a preselected image layer may cause the panoramic radiograph to become distorted and blurred.

Previously, the high resolution quality of medical computed tomography and its capability to accurately demonstrate the location and morphology of the inferior alveolar canal had made this modality useful in presurgical evaluation of the relationship between the alveolar canal and mandibular third molars (Hidenobu et al 2003, Mashasantiya et al 2005). The high cost of medical computed tomography and its relatively high radiation exposure to the thyroid gland, salivary gland, eyes, and skin are health issues to be considered (Freisfeld et al 1998, Aryatawong and Aryatawong 2000).

In recent years, cone beam computed tomography scanners have been developed specifically for dental and maxillofacial imaging (Arai et al 1999, Scarfe and Farman 2008). This technology is becoming more commonly used in dentistry instead of medical computed tomography since, it provides comparable images at reduced dose and cost (Loubele et al 2009, Tsiklakis et al 2005). The three dimensional cone shaped X-ray beam which is used in the cone beam computed tomography machine allows a volumetric data set of the maxillofacial region to be obtained with just a single scan. This provides an advantage to the cone beam computed tomography over the medical computed tomography, which requires multiple radiation exposures in order to obtain the similar volumetric data output.

On the computer monitor, the volumetric data set acquired by cone beam computed tomography is used to generate reconstructed images in three orthogonal planes which are axial, sagittal and coronal planes. Using the volumetric data set, secondary reconstructed images in non-orthogonal slices such as panoramic reconstruction and cross sectional slices can also be performed. These non-orthogonal slices are collectively known as multiplanar reformation images (Scarfe and Farman, 2008).

Absence of both magnification and distortion in secondary reconstructed images from cone beam computed tomography volumetric data had been described, hence, measurements performed on this reconstruction slice can be assumed to have a one : one relationship with the actual object (Snyder, 2007). The geometric and small size of the isotropic voxels of the cone beam computed tomography volumetric data sets which range from 0.076 to 0.4 millimetres also provides high contrast resolution with cone beam computed tomography images (Scarfe and Farman 2008).

In order to obtain a cone beam computed tomography panoramic image for evaluation of an impacted mandibular third molar, the axial view at the occlusal level of the third molars is used to visualize the mandible. Then, the focal plane of the image layer is constructed by locating points throughout the occlusal surfaces of the teeth present in the axial view (Snyder, 2007). The focal trough shape of the constructed panoramic image can be adjusted, since the computer software used to analyze data acquired by cone beam computed tomography allows adjustment to be made on the features of the curved multi planar reconstruction slice.

The ability of the cone beam computed tomography technology to customize the focal trough shape to suit an individual dental arch allows for improved visualization of the anatomical structures of the region of interest. Cone beam computed tomography proved to be a reliable technique for visualizing anatomical structures in the maxillofacial region including the inferior alveolar canal, and for assessing its relationship to the adjacent roots of teeth (Tantanapornkul et al 2007, Angelopoulos et al 2008, Sawamura et al 2003). However, the higher radiation dose and cost of cone beam computed tomography in comparison to panoramic radiography limits the use of this modality to cases where there is appropriate justification for assessment when employing conventional radiographic findings.

2.4 Indication of cone beam computed tomography in relation to impacted third molar removal.

Specific guidelines for the use of cone beam computed tomography concerning to the removal of impacted third molars has been published in SEDENTEXCT project (2011). According to these guidelines, the use of cone beam computed tomography may be indicated when there is insufficient information obtainable by conventional radiography for the assessment of an impacted tooth, where conventional radiographs suggest a direct inter-relationship between mandibular third molar and mandibular canal, and when a decision to perform surgical removal has been made.

The intimate relationship between a mandibular third molar and the mandibular canal from conventional radiograph has been described in the Scottish Intercollegiate Guideline Network (SIGN). According to this guideline, the presence of diversion of the inferior dental canal, darkening of the root when crossed by the canal, or interruption of the radiopaque line of the canal have been demonstrated to be associated with a significantly increased risk of nerve injury during mandibular third molar surgery. It is also suggested from this guideline that the presence of any of these findings warrants a second radiograph to be taken using different project geometry.

Although several guidelines have been adopted in relation to the use of cone beam computed tomography prior to impacted third molar removal, there is still a need for research data concerning on cone beam computed tomography-based diagnosis versus conventional imaging. In the SEDENTEXCT project (2011) recommendations for research in cone beam computed tomography-based diagnosis or treatment planning versus conventional imaging and research on the utility of cone beam computed tomography prior to third molar extraction, and clinical data regarding patient clinical outcomes when using cone beam computed tomography compared to conventional radiographs had been made. In this study, cone beam computed tomography-based imaging versus conventional panoramic imaging was compared during preoperative assessment of impacted mandibular third molars and their relationship to the inferior alveolar canal.

2.5 The accuracy of panoramic radiography versus cone beam computed tomography.

Flygare and Ohman (2008) suggested that in the absence of overlap between the inferior alveolar canal and a lower third molar, panoramic or intraoral radiograph are generally adequate for the evaluation of the proximity of lower third molar to the inferior alveolar canal. Several authors suggested that cone beam computed tomography is more reliable than panoramic radiography in the assessment of impacted third molar as well as its surrounding structures (Tantanapornkul et al 2007, Angelopoulos et al 2008, Sawamura et al 2003).

Concerning the relationship of impacted mandibular third molar to the inferior alveolar canal, studies have been done which compared the image produced from panoramic radiography with cone beam computed tomography images (Tantanapornkul et al 2007, Neugebauer et al 2008, Ghaeminia et al 2009). Tantanapornkul et al (2007) showed that cone beam computed tomography was superior to panoramic radiography in predicting neurovascular bundle exposure following assessment of the relationship of the third molar root tip to the inferior alveolar canal. They studied 161 impacted teeth and reported that the relative sensitivity of cone beam computed tomography and panoramic assessment in predicting the nerve exposure was 93% and 70%, and the specificity of cone beam computed tomography and panoramic assessment was 77% and 63%, respectively.

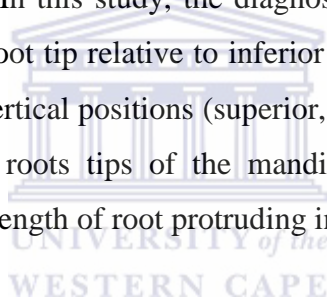
This finding is contradictory with the finding described by Ghaeminia et al (2009). They found that although cone beam computed tomography has an advantage in determining the horizontal (bucco-ligual) position of mandibular third molar to inferior alveolar canal, there is no significant difference in sensitivity and specificity between these two imaging modalities in predicting inferior alveolar nerve exposure. From this finding they also concluded that the accuracy of panoramic radiograph in predicting inferior alveolar nerve exposure is comparable to that of cone beam computed tomography even, in cases which show a close relationship between mandibular canals and third molar roots.

In both studies done by Tantanapornkul et al (2007) and Ghaeminia et al (2009), similar criteria were used to describe the relationship of third molar roots and inferior alveolar canals from panoramic radiographs and cone beam computed tomography

images. Investigators who evaluated these images were also blinded from the surgical results in these studies. The only advantage in the study done by Tantanapornkul et al (2007) in comparison to Ghaeminia et al (2009) was the larger sample size in the former. Fifty six mandibular third molars were studied by Ghaeminia et al (2009) and this sample size is almost three times less than that employed in the study done by Tantanaporkul et al (2007). A smaller sample size described by Ghaeminia et al (2009) could be due to more strict selection criteria used in the study performed.

The findings from Ghaeminia et al (2009) and Flygare and Ohman (2008), suggest that information from vertical position of third molar root tip to inferior alveolar canal may be sufficient to predict inferior alveolar nerve exposure.

A study by Neugebauer et al (2008) reported that the diagnostic findings from cone beam computed tomography and panoramic radiography in assessing of the vertical distance of the inferior alveolar canal to the root tip of mandibular third molars, presented with similar data. In this study, the diagnostic information of the position of the mandibular third molar root tip relative to inferior alveolar canal was determined by classifying them into three vertical positions (superior, at level or inferior). However, the exact distance between the roots tips of the mandibular third molar to the inferior alveolar canal as well as the length of root protruding into the canal were not measured.



2.6 Measurement of vertical position of third molar in relation to its adjacent structure.

Bouquet et al (2004) described a quantitative study in the localization of third molars in relation to the maxillary sinus. The study measured the exact distance of third molar roots in the sinus as well as the bone height separating the roots from the sinus. From these measurements, the reliability of panoramic radiographs was determined by comparing the results with medical computed tomography scan.

Similarly, the exact distance between third molar and the IAC can be measured. In this present study, cone beam computed tomography images were used for evaluation of the reliability of panoramic radiographs to determine the vertical position of third molar to inferior alveolar canal.



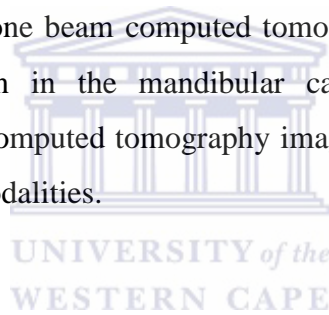
3. AIM AND OBJECTIVES OF STUDY

3.1 Aim of study

The aim of this study was to investigate the reliability of conventional panoramic radiograph in the evaluation of the proximity of impacted mandibular third molar root tip to the inferior alveolar canal by correlating the results obtained by means of cone beam computed tomography.

3.2 Specific Objective

The specific objectives of this study were i) to measure the thickness of bone which separates the root tips of third molar from the IAC on conventional panoramic radiographs as well as on cone beam computed tomography images, ii) to measure the third molar root protrusion in the mandibular canal on conventional panoramic radiograph and cone beam computed tomography images and iii) to compare the results obtained by both imaging modalities.



4. MATERIAL AND METHODS

4.1 Data collection

A sample size of 49 patients with a total of 65 root tips of impacted mandibular third molars who had both panoramic radiographs and cone beam computed tomography images for pre-operative assessment of the impacted molars were included in this retrospective study. The data were gathered from the Maxillofacial Radiology and Diagnostics Department at the Faculty of Dentistry of the University of Western Cape, as well as, from the Department of General Dental Practice and Oral maxillofacial Imaging at the Faculty of Dentistry of the University of Malaya. Initially, panoramic reconstructions of cone beam computed tomography images were selected from existing records of patients who went for cone beam computed tomography assessment prior to surgical removal of the third molar. Then, the matching conventional panoramic images were searched from a patient records database for subsequent comparison with the cone beam computed tomography images.

The panoramic images were performed using the Veraview digital panoramic unit (J. Morita, USA) operating at 60 to 70 kVp and 5 to 10 mA, as well as a PC-1000 unit (Panoramic Corporation, Fort Wayne, Indiana, USA) operating at 80 to 90 kVp and 6 mA. Cone beam computed tomography images were obtained with I-CAT unit (Imaging Sciences International, Inc. Hatfield, PA) operating at 120 kVp and 8 mA, as well as a NewTom VGi (Verona, Italy) operating at 110 kVp and 15 mA. The field of view selections ranged from small (8 and 13 centimetre in height and diameter) to medium (13 and 17 centimetre in height and diameter) for I-CAT unit. On the other hand, the field of view used in the impacted cases performed with the NewTom VGi unit was 8 centimetre high by and 12 centimetre in length.

The inclusion criteria employed in this study were (i) patients older than 18 years old, (ii) the presence of fully visible impacted mandibular third molars and (iii) visible inferior alveolar canals. Any radiographic record which showed incomplete root formation, pathology or resorption in apical area of mandibular third molars were excluded in this study.

4.2 Ethic clearance

Panoramic radiograph examination has been commonly used as an initial radiographic approach in the assessment of impacted mandibular third molars prior to surgical removal of the teeth. In some cases, patients with impacted mandibular third molars are referred for cone beam computed tomography to improve visualization of the impacted tooth and its surrounding structures. To allow comparison of panoramic radiographs and cone beam computed tomography images to be made only records which consisted of both diagnostic images were used in this study.

The results of the data obtained were collected with no reference to a specific individual name. Hence, the data from each individual remained confidential. Approval from the research ethics committee of the University of the Western Cape as well as from the medical ethics committee, Faculty of Dentistry, University of Malaya were obtained prior to commencement of the study.



4.3 Data analysis

All the images were viewed by a senior lecturer of Maxillofacial Diagnostic and Radiology Department, University of Western Cape as well as a maxillofacial radiology postgraduate student in the same institution. Calibration of the observer by training in the radiographic features for evaluation of molar root tips in relation to the inferior alveolar canal from cone beam computed tomography images and panoramic radiographs was done by the senior lecturer who also participated in the image evaluation in this study.

Concerning the panoramic radiographs, 35 panoramic radiographs were in digital form whereas 14 were in the form of analogue film. The digital panoramic radiographs were obtained using Veraview unit, whereas the analogue panoramic radiographs were obtained by using PC-1000 panoramic machine. The magnification factors on panoramic radiographs performed by these panoramic machines were 1.3 and 1.23 for the Veraview and the PC-1000, respectively. To minimize the influence of image magnification on the panoramic radiographs, the magnification was compensated by dividing the vertical and horizontal component of the panoramic images with its magnification factor.

In the case of analogue panoramic radiographs, since the films were converted into digital format using a Epson Perfection V750 Pro scanner in the Maxillofacial Radiology unit of the University of Western Cape, the magnification factor of the scanner was also taken into account in this study. The scanned panoramic images showed vertical and horizontal enlargement of one millimetre from the original panoramic radiographs. Therefore, in such cases the image magnification attributed by the scanner was initially removed from the digitized panoramic images before compensating for the magnification factor from panoramic radiography image acquisition.

Assessment of cone beam computed tomography images were done by using reconstructed panoramic views. When performing panoramic reconstruction, the points on the occlusal surface of the teeth which represent the focal plane were adjusted so that the mandibular canals and the mandibular third molar apices were visible when panoramic images were viewed at one millimetre thickness. In each subject, three panoramic reconstructed slices were created with one millimetre distance between each image (Figure 1, Appendix 1). The relationship of the tooth root apex to the inferior alveolar canal was assessed in this reconstruction plane on all slices. The panoramic reconstruction plane which showed the closest proximity of the root apex to the inferior alveolar canal was selected for subsequent comparison with the matched conventional panoramic radiograph.

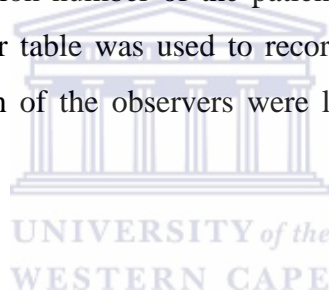
Subsequently, the selected panoramic reconstruction cone beam computed tomography images and the resized panoramic radiographs after removing the image magnification factor were cropped for approximately 3.5 centimetres in vertical and horizontal dimensions, using a snipping tool software. This was done to enable both observers to focus on the assessment of the proximity of the third molar apices to the inferior alveolar canal. The cropped images were entered in spread sheets in the Microsoft Word which is viewed at 100%. These images were magnified to 500% and a prepared standard one centimetre ruler with the same magnification was used to measure the proximity of the third molar root apices to the inferior alveolar canals. At this magnification, image enhancement of the cropped images was done by changing contrast and brightness level to improve visualization of the structures and allow the observers to determine the closest point of the root apices to the inferior alveolar canal (Figure 2, Appendix 2).

In order to standardize the vertical measurement from conventional panoramic radiographs and cone beam computed tomography images, the prepared standard ruler used in this study was set at an angle to the roof of the inferior alveolar canal and the measurement

was made from the roof of the canal towards the most apical part of the root (Figure 3, Appendix 3). Further magnification of the image and the standard ruler were performed to allow better visualization of the ruler's scale and the point made on the root apex (Figure 4, Appendix 4).

The measurements recorded in this study were categorized into positive, zero and negative measurements. A positive measurement was considered when the root apex was measured above the roof of the inferior alveolar canal. This measurement was also used to indicate presence of bone thickness separating the roots and the inferior alveolar canal. On the other hand, any root apex measured below the roof of the canal was considered as negative measurement, and this measurement was representative of the length of the root in the canal. When the root apex was superimposed on the canal, this was considered as a zero measurement.

All measurements in this study were recorded in the data collection table (Table 1, Appendix 5), where the registration number of the patient was used as a reference of data from the same subject. A similar table was used to record the measurements made by the second observer. Data from both of the observers were later compared in the new spread sheets in Microsoft Excel.



4.4 Statistical analysis

All of these measurements were entered and analyzed using Microsoft Excel. Means and standard deviation of the measurements recorded by both observers were calculated for each imaging modality. The reliability of panoramic radiographs in the assessment of the vertical proximity of the root apex to the canal was evaluated statistically by comparing panoramic radiographs measurements with cone beam computed tomography image measurements using the student t-test. The student t-test was also used to evaluate the inter-observer agreement in this study.

5. RESULTS

In the assessment of the vertical position of 65 mandibular third molar root apices from the roof of inferior alveolar canals (Table 2), 44 of the cases showed negative measurement from the panoramic radiography image evaluation. This finding also showed that most of the impacted mandibular third molars showed intrusion of the root into the inferior alveolar canal when panoramic radiographs were assessed. The lengths of these roots within the inferior alveolar canals were measured to be between 0.15 to 5.6 millimetres. On cone beam computed tomography, only 33 root apices were found within the alveolar canal, and the lengths ranged between 0.05 to 4.2 millimetres.

On the other hand, the number of root apices located above the inferior alveolar canals which gave positive measurements in panoramic radiographs as well as cone beam computed tomography images were 17 and 27 root apices, respectively. On panoramic radiographs, the thickness of bone height separating the root apices from the roof of the canal ranged from 0.2 to 2.75 millimetres. Whereas, on cone beam computed tomography images the height ranged from 0.1 to 4.75 millimetres. Several superimpositions of the root apices on the roof of inferior alveolar canals had also been found in both imaging modalities and these were recorded as zero measurement. There were four root apices found to be superimposed on the roof of inferior alveolar canals from panoramic radiographs and five root tips on cone beam computed tomography images.

An additional finding in this study indicated that eleven out of forty four roots were located within the canal from panoramic radiographs but were actually located superior to the canal on cone beam computed tomography panoramic reconstruction slices. This finding is demonstrated in Figure 5 (Appendix 6) and Figure 6 (Appendix 7). Two out of seventeen roots which were located less than one millimetre above the inferior alveolar canal in panoramic radiographs showed root protrusion into the canal in the cone beam computed tomography images.

From this study, both observers showed significant difference between cone beam computed tomography images and panoramic radiographs when measuring the vertical position between the root apices to the roof of the canals. The mean difference between panoramic radiographs and cone beam computed tomography images when measuring the vertical distance between impacted mandibular third molar root apices and the roof of the inferior alveolar canals, recorded by the first observer was 0.580 millimetres ($P < 0.001$). The

difference was statistically significant between the two methods. The mean difference between cone beam computed tomography images and panoramic radiographs measurements made by the second observer was 0.529 millimetres ($P < 0.001$), which also indicated a significant difference between both methods. This finding is demonstrated in the plot of cone beam computed tomography image measurements against panoramic radiograph measurements (Figure 7). It can be seen from this plot that the red points representing cone beam computed tomography image measurements are widely dispersed around the trend line of panoramic radiograph measurements, thus, indicating real bias between both methods.

In addition to this, the mean differences between the observer's measurements for both methods were also evaluated to determine the presence of bias. Using the paired version of the t-test, the mean difference in panoramic radiograph measurements between the first and the second observers was 0.047 millimetres, which was small but turned out to be significantly different from zero ($P=0.020$). At this stage, one may assume that the inter-observers agreement in the measurement of panoramic radiographs was low. However, by plotting panoramic measurements made by the first observer on the X-axis and panoramic measurements by the second observer on the Y-axis, the points cluster closely around the straight line reflecting the presence of only small bias between the observers' measurements on panoramic radiographs (Figure 8). The significant difference in the paired version of the test was explained by comparing the numbers of negative and positive differences in these two sets of panoramic radiograph measurements. From the assessment, the proportion of the negative difference was 0.3. This value is significantly different from 0.5; thus contributing to the significant difference in the paired version of the t-test, although a good inter-observers agreement is demonstrated from the plot of panoramic measurements by the first observer versus panoramic measurements by the second observer.

The mean difference in the measurements of cone beam computed tomography images between the two observers was 0.0031 millimetres and is not significantly different from zero ($P=0.837$). This showed absence of bias in the cone beam computed tomography measurements made by both observers. A good inter-observers agreement in cone beam computed tomography measurements is also demonstrated in Figure 9, which shows a close relationship of the clustering of points around the straight line.

Table 2: A table of data which presents the vertical position of 65 mandibular third molar root apices in relation to the roof of inferior alveolar canal, from panoramic radiographs and cone beam computed tomography images.

Evaluation categories	Panoramic radiograph			Cone beam computed tomography images		
	No. of roots	<i>m</i>	<i>M</i>	No. of roots	<i>m</i>	<i>M</i>
Root apices below the roof of alveolar canal (negative measurement)	44	0.15	5.6	33	0.05	4.2
Root apices above the roof of alveolar canal (positive measurement)	17	0.2	2.75	27	0.1	4.75
Root apices superimposed on the roof of alveolar canal (zero measurement)	4	-	-	5	-	-

M and *m* represent maximum and minimum value measured in millimetre, respectively.

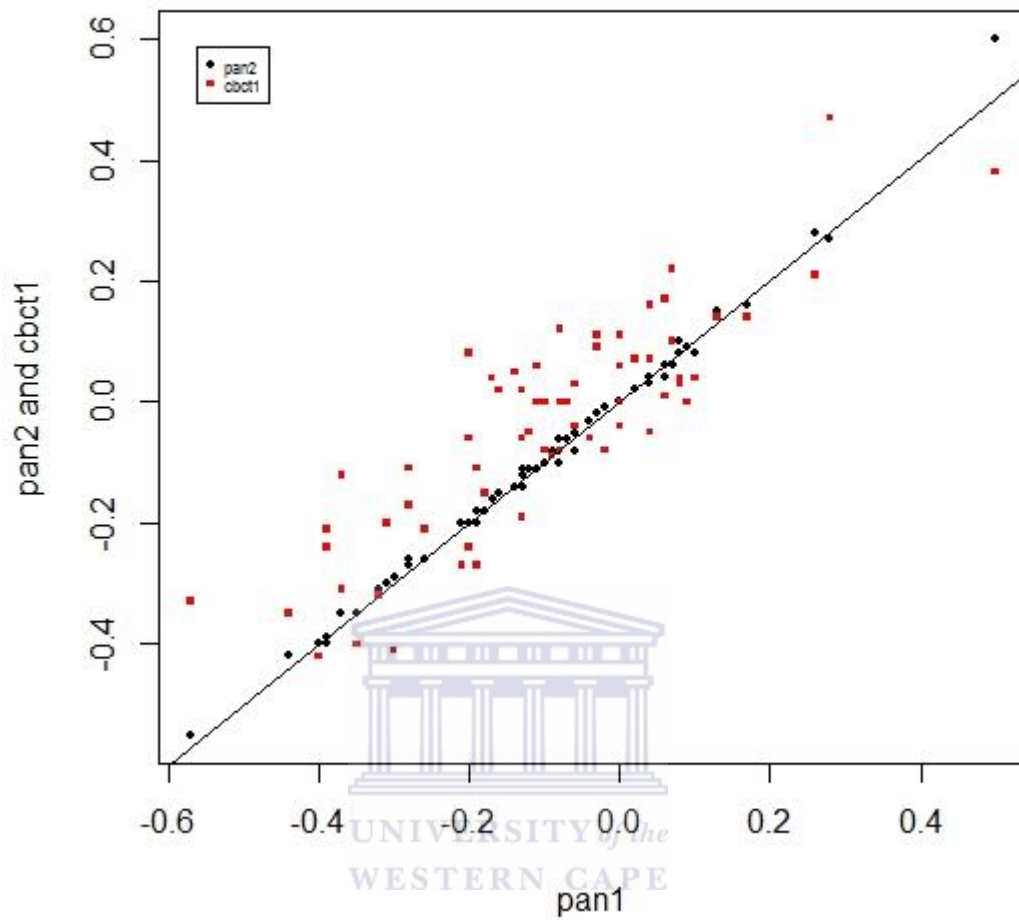


Figure 7: A plot of X and Y axes employed to compare cone beam computed tomography image measurements by 1st observer (cbct1) versus the panoramic radiograph measurements counterpart (pan1).

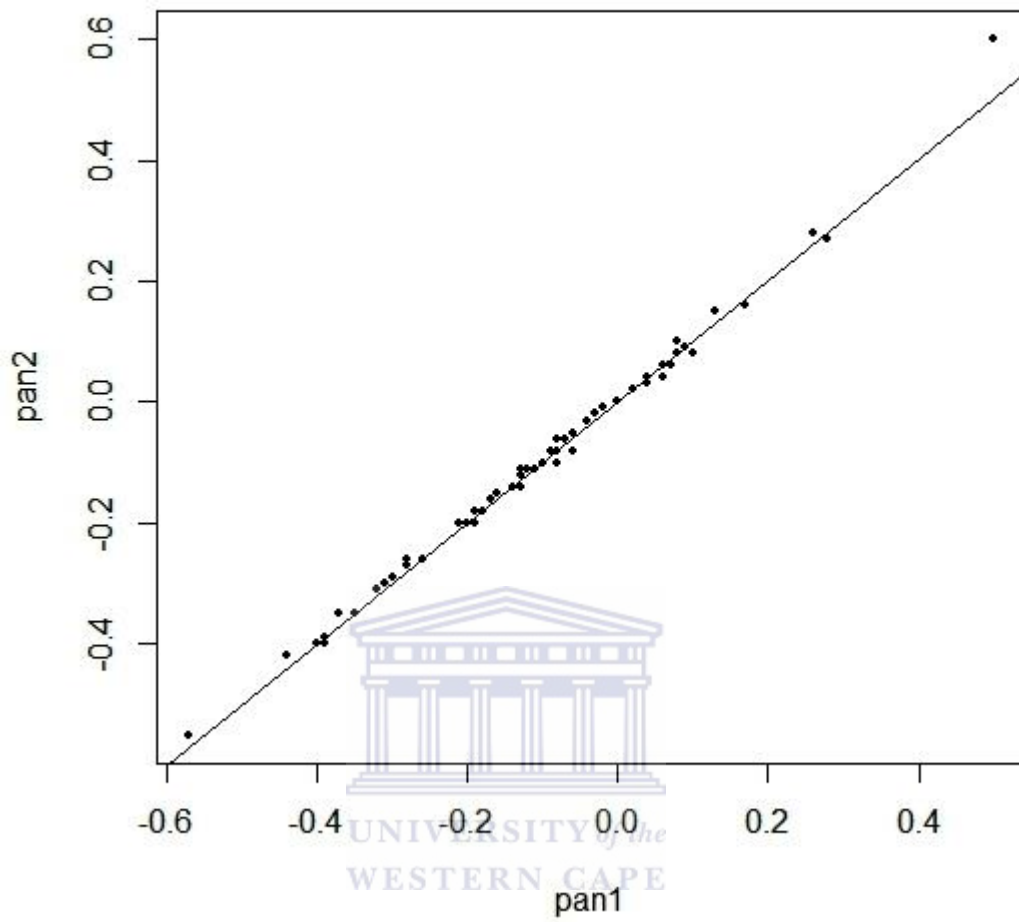


Figure 8: A plot of X and Y axes employed to compare measurements on panoramic radiographs by 1st observer (pan1) versus 2nd observer (pan2).

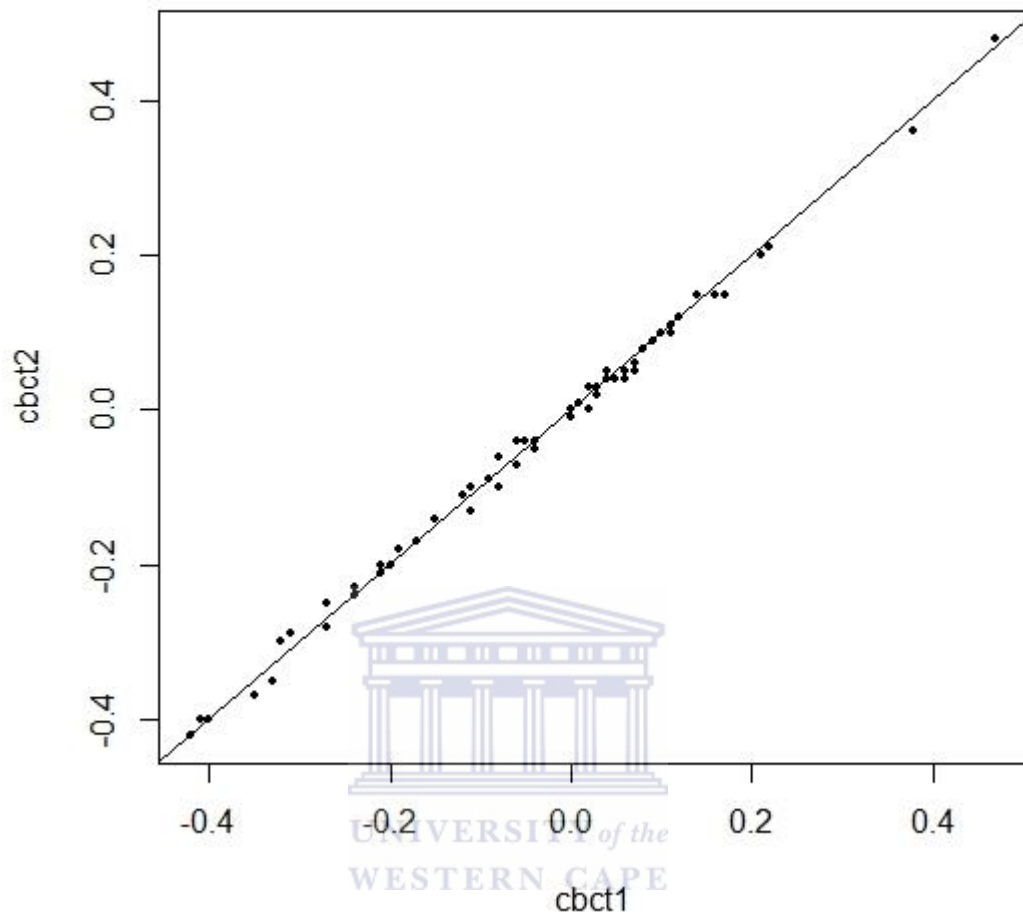


Figure 9: A plot of X and Y axes employed to compare measurements of cone beam computed tomography images by 1st observer (cbct1) versus 2nd observer (cbct2).

6. DISCUSSION

The incidence of inferior alveolar nerve injury from surgical removal of third molar varies from 0.4% up to 8.4% (Bataineh 2001). Injury of the inferior alveolar nerve is a worrisome consequence following third molar removal, since the symptoms associated with the nerve injury may persist for several months or in serious case the patient may end up with a permanent paraesthesia. In most cases, the presence of numbness from a nerve injury will resolve within or less than six months. In cases of permanent paraesthesia, the incidence is commonly reported to be less than 1% (Gulicher and Gerlach 2001, Sedaghatfar et al 2005, Susarla and Dodson 2007). Close proximity of the third molar's root apex to the inferior alveolar canal predisposes a patient to nerve injury following surgical removal of the tooth (Bataineh 2001). Therefore, in the preoperative assessment the third molar, accurate diagnostic assessment is important to achieve precise evaluation of the relationship of the root apex to the canal. Knowing the exact position of the root apex to the inferior alveolar canal will help the surgeon to determine the risk associated with the surgical procedure and to decide the most appropriate treatment plan.

Studies showed the diagnostic accuracy of cone beam computed tomography in predicting neurovascular bundle exposure prior to impacted mandibular third molar removal (Tantanapornkul et al 2007, Ghaemini et al 2011). However, due to the higher dose and cost of this imaging modality, many dental settings only rely on conventional radiographs such as panoramic radiograph in the assessment of impacted mandibular third molar. In the SEDENTEXCT guideline (2011), the close proximity of a mandibular third molar to the inferior alveolar canal indicates the use of cone beam computed tomography to evaluate the situation precisely. Nevertheless, this guideline also suggests that more studies are required to compare the reliability of conventional imaging with cone beam computed tomography in the assessment of the relationship of the third molar to the inferior alveolar canal. Understanding the limitation of conventional radiograph in the assessment of impacted third molar is paramount in determining the need of cone beam computed tomography in selected cases and avoid unnecessary radiation exposure to the patient.

So far, several studies have been made to compare the diagnostic accuracy of panoramic radiograph with cone beam computed tomography. It has been reported that panoramic image is comparable to cone beam computed tomography image in predicting neurovascular bundle exposure, despite its limitation to assess the horizontal relationship of

the mandibular third molar root apex to the inferior alveolar canal (Ghamenia et al 2009). In a study by Flaygare and Ohman 2008, it has been concluded that, in the absence of an overlap between inferior alveolar canal and mandibular third molar from panoramic radiograph, adequate assessment of the tooth relative to the canal still can be achieved.

In this study we found that two out of seventeen roots which were located above the inferior alveolar canal on panoramic radiographs showed protrusion into the canal from the cone beam computed tomography images. Whereas, eleven out of forty four roots which were located within the canal on panoramic radiographs were actually located superior to the roof of the inferior alveolar canal on cone beam computed tomography images. Therefore, the presence of protrusion of mandibular third molar roots in the inferior alveolar canal on panoramic radiographs does not always signify association of the root apices to the neurovascular bundle within the canal. In a similar fashion, the absence of root protrusion in the inferior alveolar canal on panoramic radiograph does not necessary indicate dissociation of the root apices from the canal on cone beam computed tomography images.

In relation to the above findings, it can be concluded that eleven of forty four cases (25%) with a high risk of nerve injury on panoramic radiographs showed alteration from the high risk to low risk after cone beam computed tomography panoramic reconstruction slices were analyzed. On the other hand, two of seventeen cases (11.8%) with a lower risk of nerve injury where the root apices were located above the canals changed into high risk, as cone beam computed tomography images demonstrated root protrusion into the canal. In consistent to the study by Susarla and Dodson (2007), we found that, additional pre-operative evaluation of impacted mandibular third molar with cone beam computed tomography can be significant in terms of determination of the risk associated with inferior alveolar nerve injury following extraction of the tooth.

Neugebauer et al 2008 demonstrated that diagnostic evaluation of the vertical position of mandibular third molar root apices to the inferior alveolar canal from panoramic radiographs gave similar clinical findings as cone beam computed tomography. In their study, the vertical position was only assessed qualitatively where the root apices were categorized into superior, inferior or at level of the canal. Quantitatively, we found that cone beam computed tomography proved more accurate by ± 0.53 to 0.58 millimetres than panoramic radiograph in the measurement of the vertical position of mandibular third molar root apices to the inferior alveolar canal. This result is statistically significant between the two imaging modalities. In support to the study done by Tantanapornkul et al (2007), we found that, the

panoramic radiograph is less reliable and gives less accurate measurements in comparison to cone beam computed tomography.

In a study of the proximity of maxillary third molars to the maxillary sinus by Hassan (2010), it had been described that superimposition of anatomical structures on conventional radiographs may result in over-projected root in the sinus. In the same manner, superimposition of buccal and lingual roots in conventional radiographs may also lead to over projection of mandibular tooth roots into the inferior alveolar canal.

In panoramic radiography, vertical magnification associated with this imaging modality is small and fairly constant. However, objects that are oblique which present with both vertical and horizontal components can appear slightly curved because of the significant change in the magnification of the horizontal component (Geist, 2001). Since most molar roots are oblique, image distortion of this anatomical structure is likely to be present on panoramic radiographs.

In this study, although the magnification factors of panoramic radiographs were compensated before any measurements were made, the influence of the magnification factor may not be totally eliminated as the vertical and horizontal magnifications on conventional panoramic images performed by a single panoramic machine vary from one another at different rates, even when the object is placed within the focal trough. Thus, superimposition of the anatomical structures, image distortion and magnification remain the main factors which are responsible for the inaccurate measurements of the conventional panoramic images found in the present study. The low reliability of panoramic radiographs to determine the vertical distance between the third molar root apices and the canal as demonstrated in this study suggest the importance of employing cone beam computed tomography as additional diagnostic modality for better evaluation of the impacted tooth.

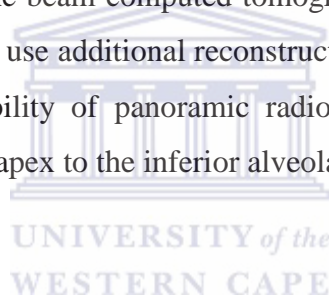
As described by Sedaghatfar et al (2005) and Neves et al (2012), this study recommends additional assessment of impacted mandibular third molar with cone beam computed tomography when panoramic radiographs suggest the presence of a root in the inferior alveolar canal or superimposition of the root on the canal.

In 1990, Rood and Nooraldeen Sheehab used seven radiological markers (Table 3, Appendix 8) to describe the possibility of root impingement on the inferior alveolar canal, as well as root protrusion into the canal from panoramic radiographs. Although the presence of these radiological markers have been associated with inferior alveolar nerve injury, the authors also described that the absence of these preoperative radiological signs does not

ensure that injury to the inferior alveolar nerve will not occur during surgery. It was reported in their study that five patients experienced labial sensation impairment without positive radiological evidence.

A finding in this study that was not reported in previous studies, is the presence of less than one millimeter of bone height separating the roof of the canal from the third molar root apex on two panoramic radiographs which suggested root protrusion into the canal from cone beam computed tomography. Therefore, other than the radiological markers as described by Rood and Shehab in 1990, the presence of bone less than one millimeter separating the roof of canal from the third molar root apex on panoramic radiograph may also indicate secondary evaluation of a case with cone beam computed tomography. However, since only two cases demonstrated as such in this study, more studies are recommended to confirm our findings.

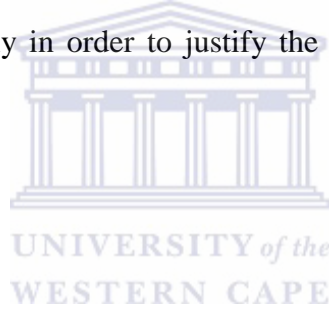
A limitation of this study was that the presence or absence of root protrusions in the inferior alveolar canal on panoramic radiograph was only compared quantitatively with two panoramic reconstructions of cone beam computed tomography images. Therefore, it is also recommended in future studies to use additional reconstruction slices in cone beam computed tomography to assess the reliability of panoramic radiographs in the assessment of the proximity of the third molar root apex to the inferior alveolar canal.



7. CONCLUSION

The reliability of panoramic radiograph to assess the vertical proximity of the mandibular root tip to the inferior alveolar canal is low. It is recommended in this study to use cone beam computed tomography as secondary diagnostic modality when panoramic radiograph shows superimposition of the third molar root on the roof of inferior alveolar canal and presence of the root below the roof of the canal. Additional evaluation with cone beam computed tomography in such cases are important to determine the actual risk associated with the inferior alveolar nerve injury following surgical removal of impacted mandibular third molar.

Presence of bone of less than one millimetre height between third molar root tip and inferior alveolar canal on panoramic radiograph may also indicate additional assessment of impacted mandibular third molar with cone beam computed tomography. Further studies are required to correlate this criterion with the incidence of neurovascular bundle exposure from cone beam computed tomography in order to justify the need of this imaging modality in such presentation.



8. REFERENCES:

- Angelopoulos, C., Thomas, S.L., Hechler, S., Parissis, N. and Hlavacek, M., 2008. Comparison between digital panoramic radiography and cone-beam computed tomography for the identification of the mandibular canal as part of presurgical dental implant assessment. *J Oral Maxillofac Surg*, 66(10), 2130-2135.
- Arai, Y., Tammissalo, E., Iwai, K., Hashimoto, K. and Shinoda, K., 1999. Development of a compact computed tomographic apparatus for dental use. *Dentomaxillofac Radiol*, 28, 245-248.
- Aryatawong, S. and Aryatawong, K., 2000. Evaluation of the inferior alveolar canal by cross-sectional hypocycloidal tomography. *Implant Dent*, 9, 339-345.
- Bataineh, A.B., 2001. Sensory nerve impairment following mandibular third molar surgery. *J Oral Maxillofac Surg*, 59, 1012- 1017.
- Bouquet, A., Coudert, J.L., Bourgeois, D., Mazoyer, J.F., Bossard, D., 2004. Contributions of reformatted computed tomography and panoramic radiography in the localization of third molars relative to the maxillary sinus. *Oral Surg Oral Med oral pathol Oral Radiol Endod*, 98, 324-327.
- Chu, F.C.S., Li, T.K.L., Lui, V.K.B., Newsome, P.R.H., Chow, R.L.K. and Cheund, L.K., 2003. Prevalence of impacted teeth and associated pathologies – a radiographic study of the Hong Kong Chinese population. *Hong Kong Med J*, 9, 158-162.
- Eraso, F.E., Scarfe, W.C., Hayakawa, Y., Smith, M. and Farman, A.G., 1997. Image layer characteristic of the PC 1000 (mark II). *Oral Radiology*, 13(1), 11-21.
- Flygare, L. and Ohman, A., 2008. Preoperative imaging procedures for lower wisdom teeth removal. *Clin Oral Investig*, 12, 291-302.
- Freisfeld, M., Drescher, D., Kobe, D. and Schuller, H., 1998. Assessment of the space for the lower wisdom teeth. Panoramic radiography in comparison with computed tomography. *J Orofac Orthop*, 59, 17-28.
- Geist, J.R., 2001. Panoramic Radiography. Sullivan-Schein Dental 04AS1601. Available at: [www. Henryschein.com/us-en/images/Dental/CEHP/Panoramic.pdf](http://www.Henryschein.com/us-en/images/Dental/CEHP/Panoramic.pdf)
- Ghaemina, H., Meijer, G.J., Soehardi, A., Borstlap, W.A., Mulder, J. and Berge, S.J., 2009. Position of the impacted mandibular third molar in relation to the mandibular canal. Diagnostic accuracy of cone beam computed tomography compared with panoramic radiography. *Int J Oral Maxillofacial Surg*, 38, 964-971.
- Ghaemina, H., Meijer, G.J., Soehardi, A., Borstlap, W.A., Mulder, J., Vlijmen, O.J.C., Berge, S.J. and Maal, T.J.J., 2011. The use of cone beam CT for the removal of wisdom teeth changes the surgical approach compared with panoramic radiography: a pilot study. *Int. J. Oral Maxillofac. Surg*, 40, 834-839.
- Gulich, D. and Gerlach, K.L., 2001. Sensory impairment of the lingual and inferior

alveolar nerve following removal of impacted mandibular third molars. *Int J Oral Maxillofac. Surg*, 30, 306-312.

Hassan, B.A., 2010. Reliability of periapical radiographs and orthopantomograms in detection of tooth root protrusion in the maxillary sinus: correlation result with cone beam computed tomography. *J Oral Maxillofac Res*, 1(1), e6.

Hiddenobu, M., Kazuo, S., Yoshimasa, K., Toshiyuki, O., Kazuki, M., Joji, S. and Tsugio, I., 2003. Preoperative assessment of the relationship between the mandibular third molar and the mandibular canal by axial computed tomography with coronal and sagittal reconstruction. *Oral Surgery, Oral Medicine, Oral Pathology, Oral Radiology, and Endodontology*, 96, 639-646.

Loubele, M., Bogaerts, R., Van Dijck, E., Pauwels, R., Vanheusden, S., Suetens, P., Marchal, G., Sanderink, G. and Jacobs, R., 2009. Comparison between effective radiation dose of CBCT and MSCT scanners for dentomaxillofacial applications. *Eur J Radiol*, 71(3), 461-468.

Ludlow, J.B. and Ivanovic, M., 2008. Comparative dosimetry of dental cone beam computed tomography devices and 64-slice computed tomography for oral and maxillofacial radiology. *Oral Surg Oral Med Oral Pathol Oral Radiol Endod*, 106, 106-114.

Mahasantiya, P.M., Savage, N.W., Monsour, P.A.J. and Wilson, R.J., 2005. Narrowing of the inferior dental canal in relation to the lower third molars. *Dentomaxillofacial Radiology*, 34, 154-163.

Neugebauer, J., Shirani, R., Mischkowski, R.A., Ritter, L., Scheer, M., Keeve, E. and Zoller, J.E., 2008. Comparison of cone-beam volumetric imaging and combined plain radiographs for localization of the mandibular canal before removal of impacted lower third molars. *Oral Surg Oral Med Oral Pathol Oral Radiol Endod*, 105(5), 633-642.

Neves, F.S., Souza, T.C., Almeida, S.M., Haiter-Neto, F., Freitas, D.Q., and Boscolo, F.N., 2012. Correlation of panoramic radiography and cone beam CT findings in the assessment of the relationship between impacted mandibular third molars and the mandibular canal. *Dentomaxillofacial Radiology*, 41, 553-557.

Pauwels, R., Beinsberger, J., Collaert, B., Theodorakou, C, Rogers, J., Walker, A, Cockmartin, L., Bosmans, H., Jacobs, R, Bogaerts, R, Horner, K., 2012. Effective dose range for dental cone beam computed tomography scanners. *European Journal of Radiology*, 81 (2), 267-271.

Rood, J.P. and Nooraldeen Shehab, B.A.A., 1990. The radiological prediction of inferior alveolar nerve injury during third molar surgery. *British Journal of Oral & Maxillofacial Surgery*, 28, 20-25.

Sawamura, T., Minowa, K. and Nakamura, M., 2003. Impacted teeth in the maxilla: usefulness of 3D Dental-CT for preoperative evaluation. *Eur J Radiol*, 47(3), 221-226.

Scarfe, W.C. and Farman, A.G., 2008. What is cone-beam CT and how does it work? *Dent Clin North Am*, 52,707-730.

Scottish Intercollegiate Guideline Network, 1993. Management of Unerupted and Impacted Third Molar Teeth: A National Clinical Guideline.

Sedaghatfar, M., Meredith, A.A. and Dodson, T. B., 2005. Panoramic radiographic findings as predictors of inferior alveolar nerve exposure following third molar extraction. *J Oral Maxillofac Surg*, 63, 3-7.

SEDENTEXCT project. Radiation Protection: Cone Beam CT for Dental and Maxillofacial Radiology. Evidence based Guidelines 2011. Available at: http://www.sedentexct.eu/files/guidelines_final.pdf. [Accessed: 20 March, 2012].

Snyder, R. L., 2007. *Cone Beam Computed Tomographic Simulation of Panoramic Radiology: Third Molar Assessment and Mandibular Canal*. Thesis (PhD). University of Louisville.

Stedman, T.L., 2005. *Stedman's medical dictionary*. 25th ed. Baltimore: Lippincott Williams & Wilkins.

Susarla, S.M. and Dodson T.B., 2007. Preoperative computed tomography imaging in the management of impacted mandibular third molars. *J Oral Maxillofac Surg*, 65, 83-88.

Tantanapornkul, W., Okouchi, K., Fujiwara, Y., Yamashiro, M., Maruoka, Y., Ohbayashi, N. and Kurabayashi, T. A., 2007. A comparative study of cone-beam computed tomography and conventional panoramic radiography in assessing the topographic relationship between the mandibular canal and impacted third molars. *Oral Surg Oral Med Oral Pathol Oral Radiol Endod*, 103(2), 253-259.

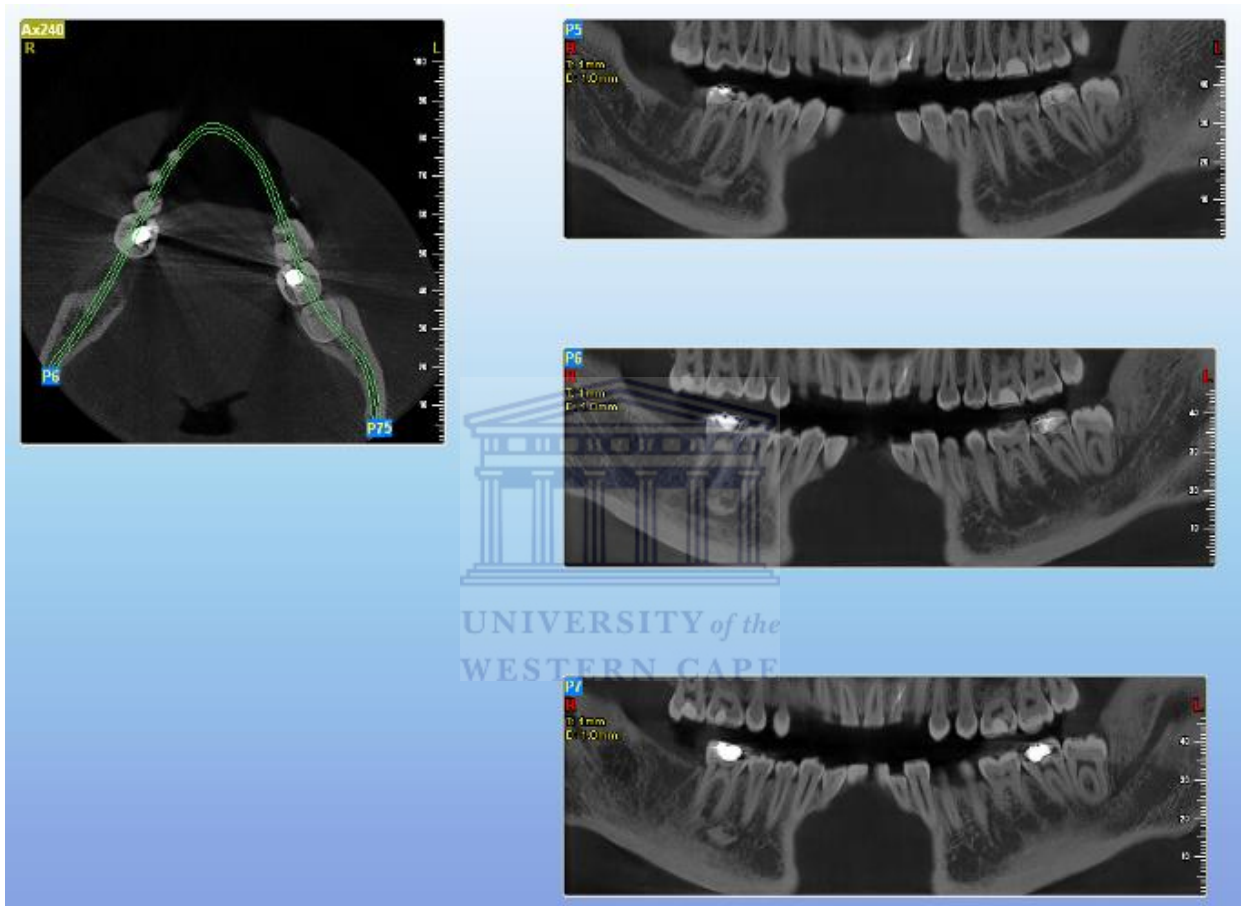
Tsiklakis, K., Donta, C., Gavala, S., Karayianni, K., Kamenopoulou, V. and Hourdakis, C.J., 2005. Dose reduction in maxillofacial imaging using low dose Cone Beam CT. *Eur J Radiol*, 56(3), 413-417.

Welander, U, Nummikoski, P, Tronje, G, McDavid, W.D., Legrell, P.E. and Langlais, R.P., 1989. Standard forms of dentition and mandible for applications in rotational panoramic radiography. *Dentomaxillofacial Radiol*, 18, 60-67.

9. APPENDICES:

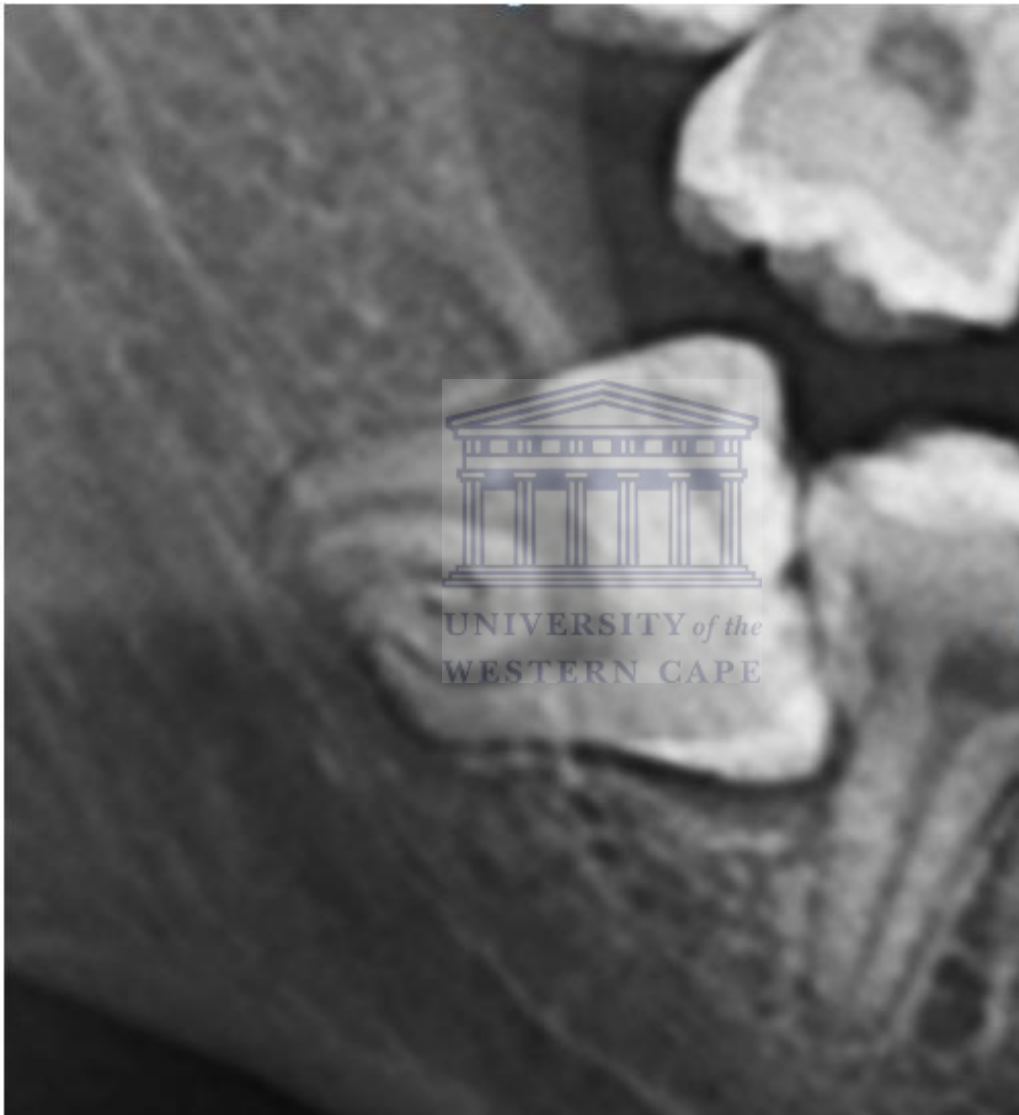APPENDIX 1

Figure 1: Three panoramic reconstructed slices were created with one millimetre distance between each image. Each plane was reconstructed at one millimetre thickness on the axial view at the level of third molar's occlusal surface.



APPENDIX 2

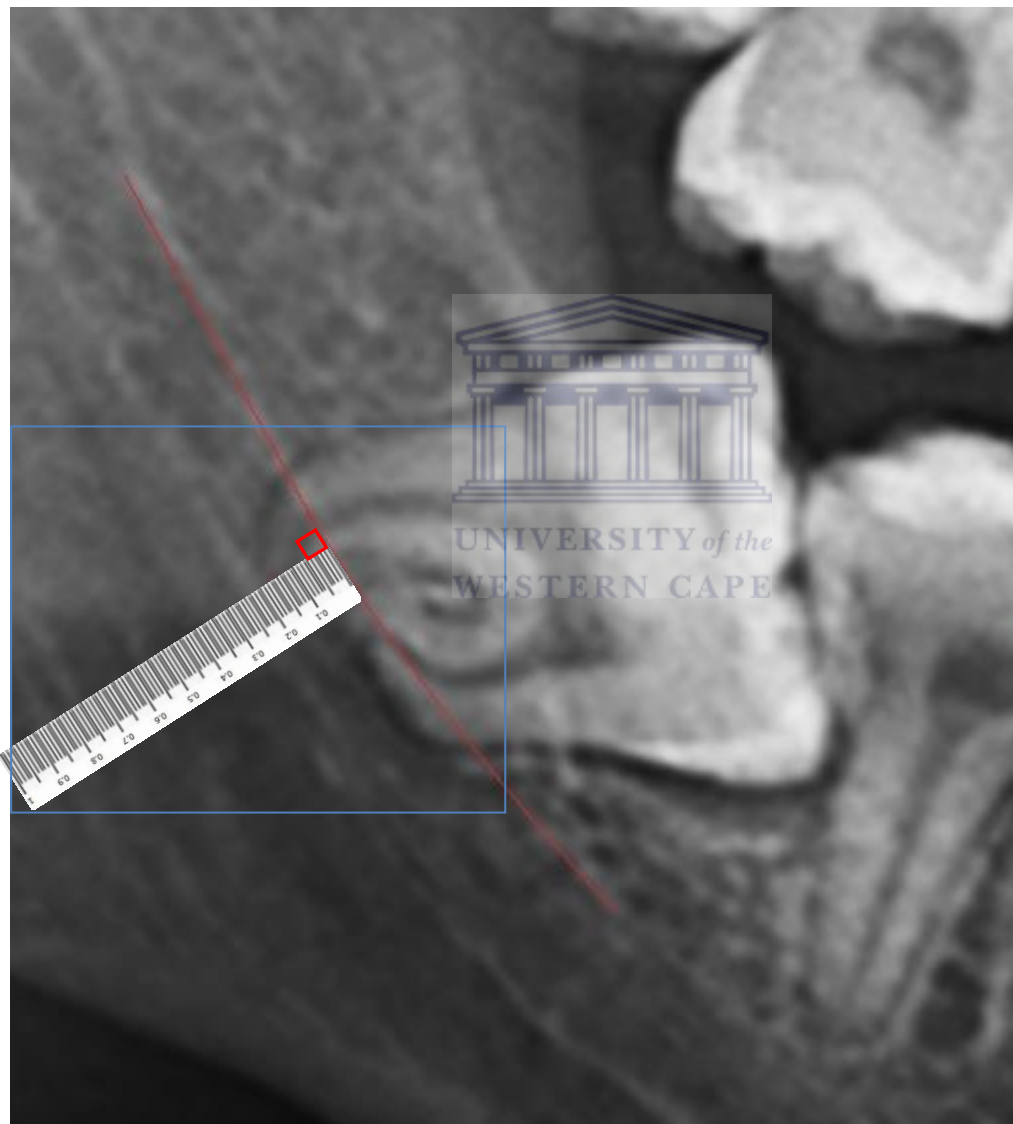
Figure 2: A cropped panoramic radiograph which is magnified at 500% in the Microsoft Word's spread sheet. This magnification is according to the magnification factor of the magnified standard one centimetre ruler used in this study. Manipulation of the image size, contrast and brightness level were made to assist in the image measurement.



APPENDIX 3

Figure 3:


The standardized position of the magnified 1 cm ruler used in this study relative to the roof of the inferior alveolar canal. The ruler was positioned at an angle to the roof of the canal and the image measurement was made from the roof of the canal towards the point on the root apex. Further magnification of the area bounded within the blue line is demonstrated in Figure 4.



APPENDIX 4

Figure 4:

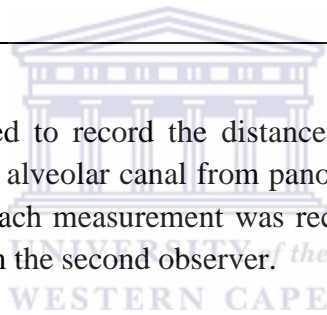
A cropped panoramic image with the standard ruler (the area bounded within blue line in Figure 3) after subsequent image magnification. The subsequent image magnification allows better visualization of the ruler's scale and the point on the root apex.



APPENDIX 5:

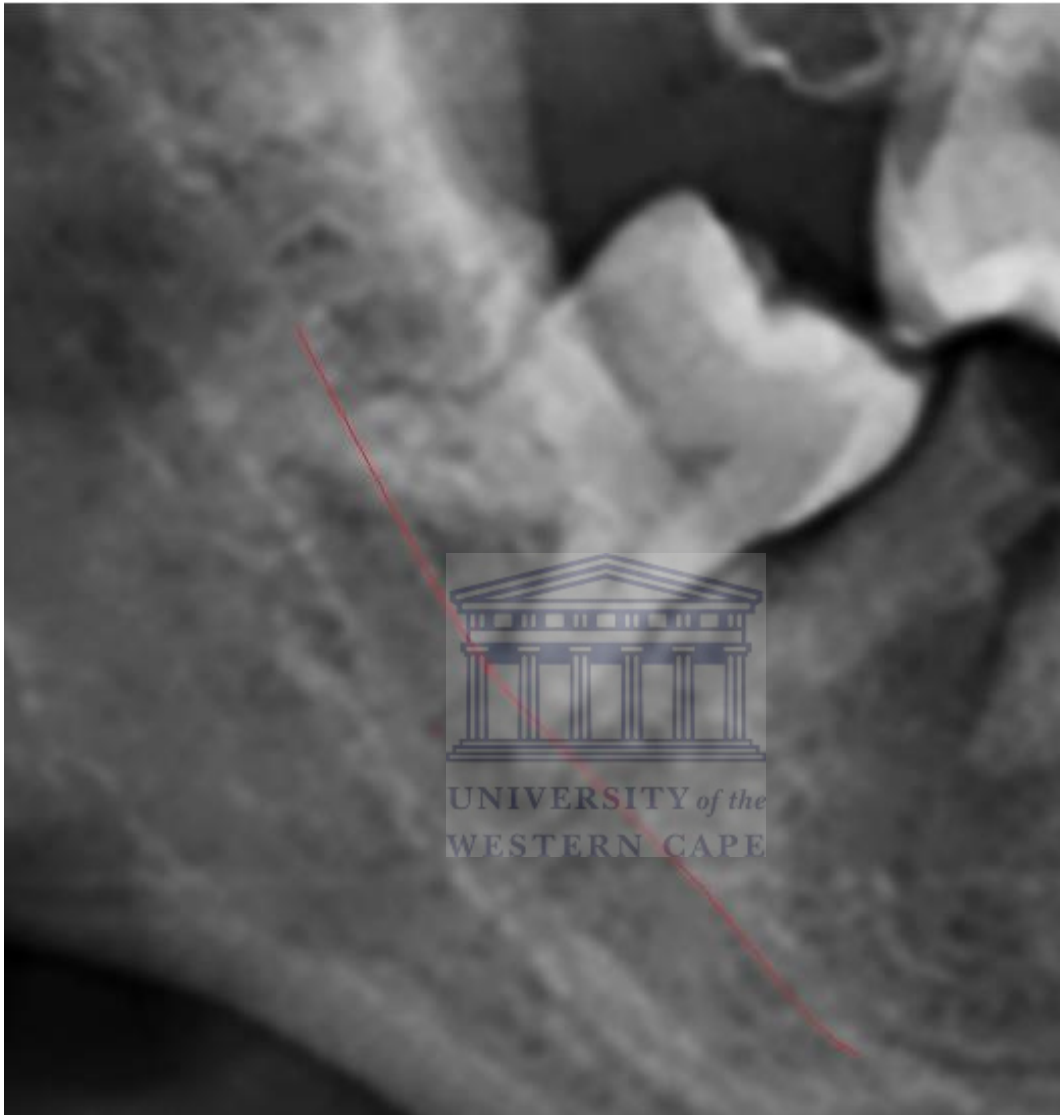Registration number	Tooth root	Panoramic radiograph (mm)	Panoramic view of cone beam computed tomography (mm)

Table 1: A table which was used to record the distance between mandibular third molar root apex and the roof of inferior alveolar canal from panoramic radiographs and cone beam computed tomography images. Each measurement was recorded in millimetre and a similar table was used to record data from the second observer.



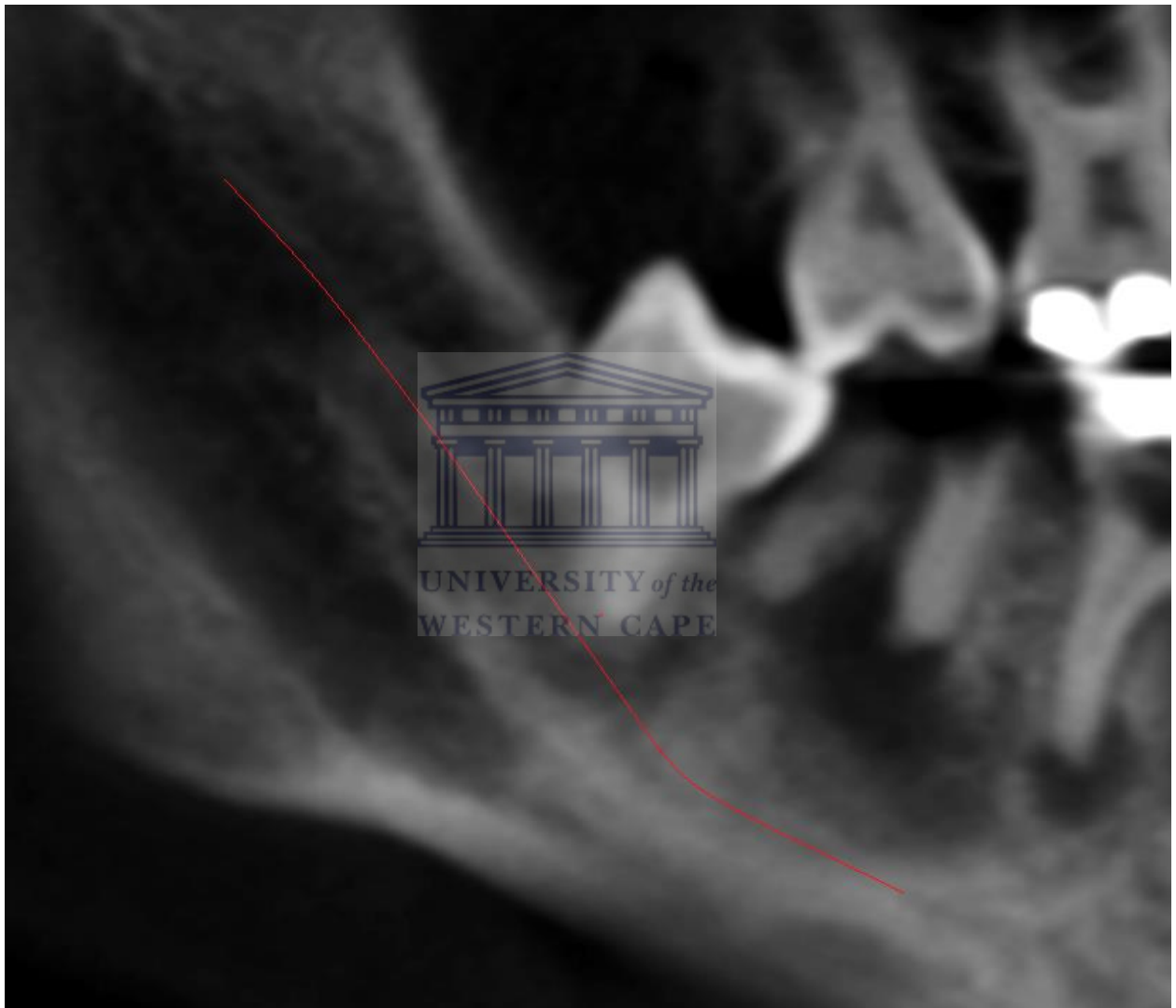
APPENDIX 6:

Figure 5: A cropped panoramic radiograph which shows presence of root within the inferior alveolar canal.



APPENDIX 7:

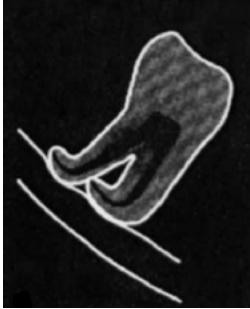


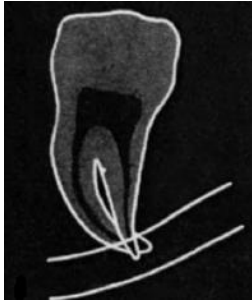
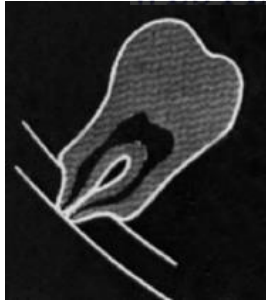
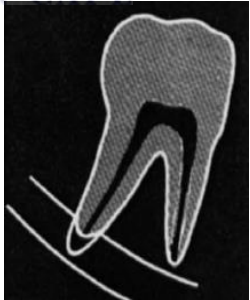
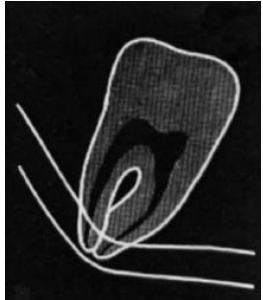
Figure 6: A cropped cone beam computed tomography panoramic reconstruction slice of the same patient in Figure 5 which demonstrates the position of the third molar root apex superior to the roof of the inferior alveolar canal.



APPENDIX 8

Table 3:

Seven radiological markers on panoramic radiograph describing the likelihood of inferior alveolar canal being superimposed or intruded by mandibular third molar (Rood and Nooraldeen Shehab, 1990).

Radiological markers which suggest the likelihood of mandibular third molar superimposed on the roof of the inferior alveolar canal.			
			
Deflection of root	Narrowing of canal	Interruption of the white line	
Radiological markers which suggest the possibility of mandibular third molar presence within the inferior alveolar canal.			
			
Darkening of root	Narrowing of root	Dark and bifid apex of root	Diversion of canal