

## **CONTENTS**

**Title Page**

**Keywords**

**Abstract**

**Declaration**

**Acknowledgements**

**List of Tables, Photographs and Graphs**

**Chapter 1:**

**INTRODUCTION**

**Chapter 2:**

**LITERATURE REVIEW**

**Chapter 3:**

**AIMS AND OBJECTIVES**

**Chapter 4:**

**RESEARCH DESIGN AND METHODOLOGY**

**Chapter 5:**

**RESULTS**

**Chapter 6:**

**DISCUSSION**

**Chapter 7:**

**CONCLUSION**

**REFERENCES**

**APPENDICES**

## KEYWORDS

oral piercing, perioral piercing, labrette, lip piercing, tongue piercing



UNIVERSITY *of the*  
WESTERN CAPE

## ABSTRACT

This study investigated the common sites and complications associated with oral and perioral piercings, and the oral hygiene practices of people with piercings (piercees). The attitude and behaviour of piercers towards the prevention and control of complications was also reviewed. The piercees completed a self-administered questionnaire, and were visually examined for sites of piercings and complications, and 10 piercers took part in an interview-led questionnaire. The completed questionnaires were coded, and the responses entered into a spreadsheet for analysis. Of the 126 participants (107 females and 19 males; ages ranging from under-16 to 24) 88.10% had a tongue piercing, 19.84% had a lip piercing, and 7.94% had both. One-hundred-and-seven (84.92%) had their piercing at a piercing or tattoo parlour, thirteen (10.31%) had the piercing procedure provided by a doctor or dentist, three went to a hairdressing salon, while one had a friend do the piercing and one individual did his own piercing. The most common post-procedure sequelae were pain (69.05%), swelling (52.38%) and difficulty eating, speaking and swallowing (70.63%). Post-piercing complications were reported by 17.56% (n = 22) of the sample, and these included chipping of teeth (n = 13), gingival recession (n = 2), damage to tongue and palate (n = 3), sore gums (n = 1), and sensitivity of teeth (n = 1). Those individuals who experienced chipping of teeth, had tongue piercings, and the gingival recession occurred in subjects with labial piercings or labrettes. These findings suggest that there is an association between piercings of the tongue and damage to teeth and piercing of the lower lip and gingival recession. All the piercers reported adequate cross-infection measures, and informed piercees of post-piercing care. It is apparent from the present study that few people had

serious problems related to lip and tongue piercings, notwithstanding the damage to hard and soft tissue, however, the providers of these procedures, and dental personnel should inform prospective piercees of the potential risks.





## DECLARATION

I, Ruebecca Ebrahim, hereby declare that the thesis entitled “Oral and Perioral Piercing in Tshwane” is my own work, and that it has not been submitted for any degree or examination at another university. All the sources that I have used or quoted have been indicated and acknowledged by a complete reference.

FULL NAME: RUEBECCA EBRAHIM

SIGNED:



DATE:

26 FEBRUARY 2007

## **ACKNOWLEDGEMENTS**

A study of this nature is only possible with the availability, co-operation, and goodwill of the subjects. I wish to thank all those participants who gave up their time to complete the questionnaire, and have photographs taken.

I would like to express my gratitude to my supervisor, Professor Sudeshni Naidoo, for her motivation and guidance. It was through her continuous direction, support, and expert supervision that I pursued and enjoyed doing this study.

A special thanks to Dr. Abdullah Khan and Dr. David Motloba for their guidance and helpful advice.

I would also like to thank Mr. Michael Nkwane at the Department of Education, who processed my request for permission to visit educational institutions, and provided me with a list of secondary schools in the area.

I am indebted to the principals and guidance counsellors at the following institutions, with whose co-operation this study was made possible:

- Tshwane South College ( Pretoria West Campus) – Mrs. A .Grobelaar
- Tshwane South College ( Citicol ) – Mr. T. Motau
- Tshwane South College ( Early Childhood Development Campus) - Annelize
- Hoerskool Pretoria-Wes – Mrs. S. Seevink
- Himalaya Secondary School – Mr. D. K. R. Dhoogar
- Tshwane North College – Ms. E. Masemola
- Pretoria Technical High School – Mr. G.R. Agocs
- Voortrekkerhoogte Hoerskool – Ms. M. van Schalkwyk
- Laudium Secondary School – Mr. D. Chetty

To my husband, Liaquat, I am grateful, for his opinions, input, and the strong pillar role he has played in all my endeavours.

A special thanks to my son Omar for his invaluable computer assistance and to my sons Mohamed and Adnaan, for their interest and enthusiasm.

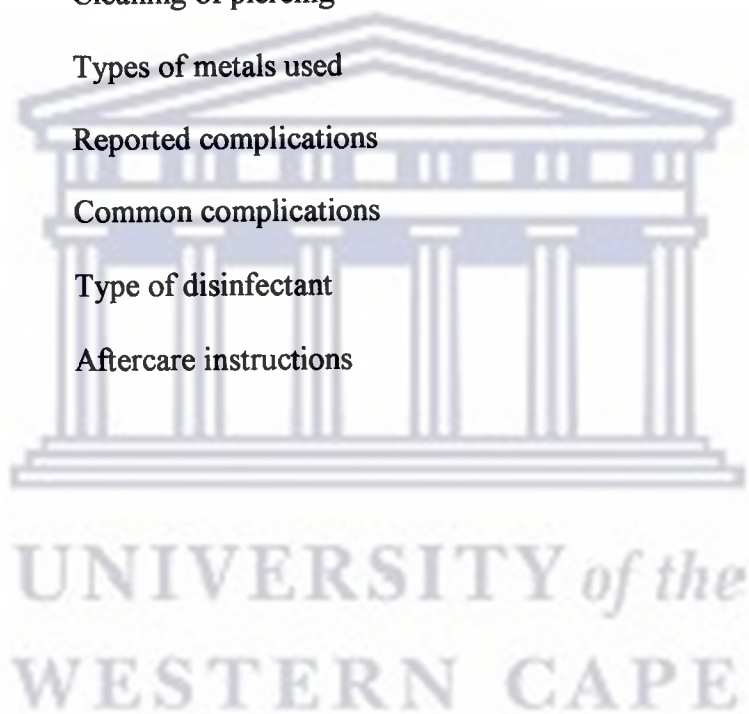
## **LIST OF TABLES**

Table 1: Complications associated with oral piercing

## **LIST OF FIGURES**

- Figure 1: Multiple oral and perioral piercings
- Figure 2: Barbell on tongue
- Figure 3: Lip piercings may be anywhere around the vermillion border
- Figure 4: Lateral view of a dorso-ventral piercing of the tongue
- Figure 5: A labrette
- Figure 6: Buccal view of a labrette
- Figure 7: Lingual barbells
- Figure 8: Piercing rings
- Figure 9: Tissue overgrowth at site of piercing
- Figure 10: Lingual barbell knocking against incisal edge
- Figure 11: Chipped incisal edge
- Figure 12: Buccal view of labrette with gingival recession
- Figure 13: Age group of sample
- Figure 14: Gender distribution
- Figure 15: Ethnic group
- Figure 16: Site of piercing
- Figure 17: The piercer
- Figure 18: Duration of piercing
- Figure 19: Main reasons for piercing
- Figure 20: Problems immediately following piercing
- Figure 21: Precautions after piercing

- Figure 22:** Healing time
- Figure 23:** Damage to teeth and/or gums
- Figure 24:** Problems since piercing
- Figure 25:** Response to problems
- Figure 26:** Sources of help for problems
- Figure 27:** Treatment
- Figure 28:** Cleaning of piercing
- Figure 29:** Types of metals used
- Figure 30:** Reported complications
- Figure 31:** Common complications
- Figure 32:** Type of disinfectant
- Figure 33:** Aftercare instructions



# ORAL & PERIORAL PIERCING IN TSHWANE

## CHAPTER 1: INTRODUCTION

Body piercing is a form of body modification. Some people practice piercing for religious or cultural reasons, while many choose to be pierced for spiritual, ornamental, or sexual reasons. Oral and perioral piercing has become an increasingly popular art form, especially among the young. To modern youth, this practice is an outward sign of provocation, rebelliousness, distinction, sexual attraction, and even mental disturbance. The less permanent nature of piercing has more appeal to youngsters as opposed to tattooing.

The American Academy of Pediatric Dentistry has issued a policy statement “strongly opposing the procedure of piercing intraoral and perioral tissues and the use of jewellery on intraoral and perioral tissues due to the potential for pathological conditions and sequelae associated with this procedure”. While the AAPD does not give specific reasons for opposing these procedures, numerous papers have documented the variety of complications that arise from mouth piercing (Rosivak and Kao, 2002).

As its popularity rises, an increasing number of patients are presenting with jewellery inserted into the oral and perioral tissues. It is therefore imperative that oral health care professionals are familiar with this practice, aware of its sequelae, and provide oral health education regarding oral hygiene and post-operative care to patients with oral piercings.

The prevalence of complications associated with oral and perioral piercings could represent a public health issue. Although several studies have been conducted in the United Kingdom and United States, there has been only one case report from South Africa. The report (Botha, 1998) focussed on an individual with a lesion associated with a tongue piercing. To date there has been no population study in South Africa.

**Figure 1: Multiple oral and perioral piercings**



UNIVERSITY of the  
WESTERN CAPE



## **CHAPTER 2: LITERATURE REVIEW**

### **INTRODUCTION**

This chapter is a comprehensive review of the literature available on oral and perioral piercings. It provides a background to body piercing, describes contemporary body piercing procedures, the healing process and aftercare. The different types of oral piercings and jewellery are discussed, as well as risks and complications associated with piercings.

### **2.1 SEARCH FOR LITERATURE**

An extensive search of the literature was carried out, using Pub Med. The search was limited to include articles from 1 January 1997 to 31 August 2006. A manual search was carried out on the Index Medicus to obtain articles from references cited in Pub Med. The keywords in the articles were as follows: *oral piercing, perioral piercing, intra-oral piercing, labrette, lip piercing, tongue piercing*

### **2.2 BACKGROUND TO BODY PIERCING**

Body piercing usually refers to the piercing of a part of the human body for wearing jewellery in the opening created.

#### **2.2.1 In ancient times**

Body piercing has been practiced since ancient times, by people all over the world (Armstrong et al, 2005). Mummified bodies that have been discovered during archaeological digs, include a mummy found in an Austrian glacier with an ear piercing 7-11 mm in diameter (Folz et al, 2000).

Nose and ear piercings are mentioned in the Bible, and nose piercing has been common in India since the 16<sup>th</sup> century. Some people in Southern India, to maintain a vow of silence, pierce the tongue with a skewer (Peticolas et al, 2000). Tongue piercing is not a recent practice and it was popular with the elite of Aztec and Mayan civilisations. The Mayans pierced their tongues to demonstrate virility and courage (Dubose and Pratt, 2004). The Eskimos pierced the lips of female babies as part of a purification ritual, and the lower lip of boys as part of the passage into puberty. Some ritualistic piercings can be temporary and may last only a few hours (Peticolas et al, 2000). The first materials used in these early piercings were stones, bones or ivory (Ring, 1984). The size, material, and type of piercing signified social standing as well as age. This practice was related to the religion, rituals of hunting, passage into puberty, signs of virility and courage and even to enforce a vow of silence (Ring, 1984).

### **2.2.2 Body piercing today**

Attitudes towards body piercing have grown more accepting in the West. Although some regard the practice of piercing as spiritual, others deride this approach as being faddish. In the modern era, increasingly creative and daring body art choices are becoming more acceptable and many people choose to wear jewellery for aesthetic purposes, for group identity, or for oral sexual gratification (Dubose and Pratt, 2004). There usually is no formal religious, tribal, or ornamental purpose. Some people choose to be pierced for symbolic reasons e.g. with gay men, piercing has traditionally been viewed as a form of public self-identification or “coming-out.” However, the current increasing popularity of piercing has diluted much of its specific cultural identification and symbolism. To modern youth this practice is an outward sign of provocation, rebelliousness and possible mental disturbance (Mayers et al, 2002).



## **2.3 CONTEMPORARY PIERCING PROCEDURE**

Permanent body piercings are created by creating an opening in the body using a sharp object such as a needle or scalpel, or removing tissue either with a scalpel or dermal punch. The common sites for oral piercing involve the lips, cheeks, tongue, fraenum, uvula, or a combination of these sites (Reichl and Dialely, 1995).

### **2.3.1 Standard needle method**

The standard needle method, practiced in the United States, involves making an opening using a hollow medical needle. The needle is inserted into the body part that is being pierced, but not all the way through, and the jewellery to be worn is pushed through the opening. This type of piercing does not remove any flesh but creates a slit (Reichl and Dialely, 1995).

### **2.3.2 Indwelling cannula method**

Many European piercers use a needle containing a cannula (hollow plastic tube placed at the end of the needle). The procedure is identical to the standard method, except that the jewellery is inserted into the back of the cannula, and the cannula and jewellery are then pulled through the piercing. With this method, the chance of the jewellery slipping during the insertion procedure is reduced (Reichl and Dialely, 1995).

### **2.3.3 Pierce and taper**

This method is sometimes used for the insertion of large gauge jewellery. After the needle is inserted, and the opening created, a tapered steel bar is inserted instead of the initial jewellery. The jewellery is then pushed through, following the steel bar (Reichl and Dialely, 1995).

## **2.4 THE HEALING PROCESS AND AFTERCARE**

A new piercing may be painful and tender for several days up to three weeks. Complete healing usually takes a few weeks. During the period of healing, care must be taken to avoid infection, and touching, and sexual activity (for oral and genital piercings) should be avoided. After the piercing is allowed to heal, a tunnel of scar tissue is formed, called a fistula (Levin et al, 2005).

### **2.4.1 Behaviours that support successful healing**

- Good hygiene
- Following the aftercare recommendations
- Taking sufficient supplements e.g. iron, zinc
- Follow-up visit to piercer

### **2.4.2 Behaviours that contribute to unsuccessful healing**

- Contact between new piercing and another person's skin
- Touching the piercing, apart from cleaning it
- Smoking and drinking alcohol (in the case of oral piercings)
- Contact between the piercing and bodily fluids, perfume or cosmetics
- Oral sex and genital intimacy
- Swimming in public pools, lakes, rivers, oceans, as they may be too harsh to promote skin cell healing. Chlorine in swimming pools may be an irritant, and bacteria and parasites in non-chlorinated water can lead to infections.

### **2.4.3 Cleaning and care of oral piercings**

Some piercers recommend using Listerine, while others, claiming that it is too harsh recommend a non-alcoholic mouthwash such as Oral-B-Non-Alcoholic or Biotene, or a diluted saline solution. Kissing and oral sex are advised against for four to six weeks after the piercing, as are hot and spicy foods. Cold foods such as ice cream and slushes are recommended. In the absence of complications, healing occurs within four to six weeks (Levin et al, 2005).

### **2.4.4 Changing of initial jewellery to allow for swelling**

For some piercings, particularly tongue piercings, changing of the initial jewellery is suggested. This is because the jewellery used initially, to allow for swelling, is significantly longer than the jewellery for a healed piercing.

## **2.5 TYPES OF ORAL PIERCINGS**

- Cheek piercing
- Lip piercing
- Tongue piercing
- Tongue frenulum piercing (web)
- Lip frenulum piercing
- Uvula piercing
- Madonna or Monroe piercing

Piercing the tongue is the most common oral piercing. It may be pierced through its “width” (dorso-lateral), in which case both spheres of the jewellery are on the dorsum of the tongue at the lateral borders, and located about halfway in the antero-posterior direction (Maibaum and Margherita, 1997).

The barbell is placed dorsally, curves down towards the ventral side of the tongue, and resurfaces at the dorsal aspect. This is not a safe procedure due to the vascularity of the tongue, and is not usually performed by professional piercers (Maibaum and Margherita, 1997).

More frequently, the tongue is pierced through its thickness (dorso-ventral direction) (Fehrenbach, 1998). The latter is commonly located in the middle of the tongue and the major blood vessels must be avoided during this procedure or it may result in blood vessel perforation with haemorrhage. This risk is increased if a person is medically compromised with diabetes, drug or alcohol dependency, HIV infection, bleeding disorders or oral infections (Fehrenbach, 1998). Accidental nerve damage may cause the loss of taste, tongue mobility, or even permanent numbness. Barbells are the most commonly used jewellery in dorso-ventral piercings, although tongue rings may be used when the piercing site is located near the tip or lateral borders of the tongue (Peticolas et al, 2000).

Another popular oral piercing is the labrette, which refers to a piercing that is below the bottom lip but above the chin. It can be placed above the labiomental groove, and centred under the vermillion border. Piercing in this site has been shown to contribute to gingival recession at the anterior facial surface of the mandibular region, due to physical trauma of the tissues (Chambrone and Chambrone, 2003; Sardella et al, 2002; O'Dwyer and Holmes, 2002).


Lip piercings can be placed anywhere around the vermillion border. The most common site is usually the lower lip near the commissure (Peticolas et al, 2000). The piercing goes through the lip extra orally and inserts into the oral cavity. A ring is often worn encircling the edge of the lip (Peticolas et al, 2000).

Less common intra- and perioral piercing locations include the cheek, lingual fraenum and the uvula. Cheek piercings are known as “dimples,” since the bilateral placement corresponds to the usual location of dimples. The intraoral placement of the ball of jewellery at the buccal mucosa can also lead to gingival recession and/or abrasion or chipping of the teeth (Peticolas et al, 2000; Chambrone and Chambrone, 2003).


The uvula is not a common site as there are inherent difficulties in performing the piercing and placement of the jewellery. Functional issues include the gag reflex, throat irritation, and swallowing (Peticolas et al, 2000).

The “Madonna” or “Monroe” piercing takes its name from the singer Madonna and the actress Marilyn Monroe. The flesh is pierced right about where Marilyn Monroe had her famous mole.

**Figure 2: Barbell on tongue**



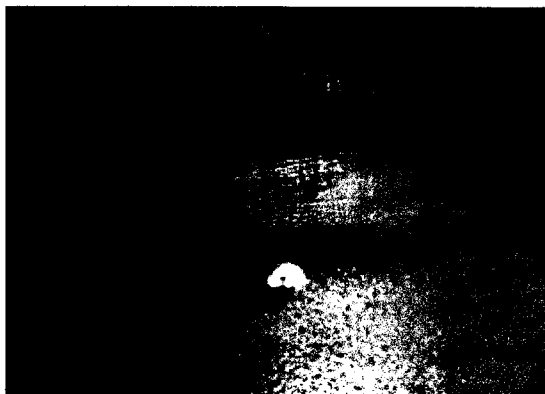
**Figure 3: Lip piercings can be placed anywhere around the vermillion border**



**Figure 4: A lateral view of dorso-ventral piercing of the tongue**



**Figure 5: A labrette**



**Figure 6: Buccal view of a labrette**






## 2.6 TYPES OF JEWELLERY USED

Modern piercings utilise rings, studs or barbell-shaped devices made out of yellow or white gold, surgical stainless steel, titanium, niobium, and even animal bones, which may cause allergic reactions in certain people (Armstrong, 1996). Barbells are the most popular form of jewellery placed in the dorso-ventral tongue piercing. Tongue rings are also utilised as jewellery when piercing the tip or lateral borders of the tongue. It is recommended that the jewellery be made of inert, non-toxic metal substances such as 14k or 18k gold, surgical stainless steel, titanium and niobium (Peticolas, et al, 2000).

**Figure 7: Lingual Barbells**



**Figure 8: Piercing Rings**



## 2.7 COMPLICATIONS AND RISKS ASSOCIATED WITH ORAL PIERCING

Body piercing is an invasive procedure not without risks. The risks can be minimized if the piercing is properly performed, and if the individuals take care of the new piercing as recommended by the piercer (Boardman and Smith, 1997). Complications resulting from an oral piercing may occur:

- During the procedure
- Shortly after
- Long after the piercing

**Table 1: Complications Associated with Oral Piercing**

<b>General</b>	Haemorrhage
	Nerve Damage
	Allergic reaction to cleaning products
	Allergic reaction to metal of jewellery
	Communicable Diseases: HIV, Hepatitis, Tetanus
	Infections
<b>Immediate</b>	Localised inflammation
	Localised infection
	Gingival trauma
	Bacteremia
	Ludwig's Angina
<b>Long-term</b>	Tissue hyperplasia
	Dehiscence
	Cracked/Fractured teeth
	Gingival Recession
	Tooth abrasion
	Aspiration/Ingestion

The most frequent problems reported in the literature during the first weeks are: oedema (Farah and Harmon, 1998), pain, inflammation (Scully and Chen, 1994), excessive salivation, abscess formation (Chen and Scully, 1992), mucosal and gingival trauma (Farah and Harmon, 1998), speech, mastication and swallowing interference (Price and Lewis, 1997), accumulation of food debris on piercing and calculus formation (Boardman and Smith, 1997).

There are several cases reporting natural and restored tooth fracture, especially of the incisal edge of anterior teeth (Botchway and Kuc, 1998), the lingual surface, and



cusps of posterior teeth injured during mastication (Fehrenbach, 1998; Maibaum and Margherita, 1997), and teeth where there may be involvement of the pulpal tissues (Botchway and Kuc, 1998). Patients presenting parafunctional habits such as bruxism may have a higher risk for tooth fracture.

Other risks and complications less frequent are: gingival recession (Chambrone and Chambrone, 2003; Sardella et al, 2002; O'Dwyer and Holmes, 2002), epithelial hyperplasia (Boardman and Smith, 1997), hereditary angioedema (Trachsel and Hammer, 1999), aspiration of jewellery (Wise, 1999), galvanic currents produced by the stainless steel appliance in contact with other metals in the mouth (Maibaum and Margherita, 1997), cyst formation (Wise, 1999), Ludwig's angina (Perkins and Harrison, 1997), hypotensive collapse (Hardee, Mallya and Hutchison, 2000), septicaemia and toxic shock syndrome (Reichl and Dailey, 1995). The perforation of the tongue, which presents a high concentration of blood vessels, can transmit systemic infections such as HIV, hepatitis B, C, D, and G, syphilis, tetanus, tuberculosis and herpes simplex (Write, 1995).

There is also a report of complication on oral intubation for general anaesthesia (Wise, 1999). Another direct implication for dental professionals is jewellery visualization on radiographs especially on panoramic and occlusal radiographs, obscuring oral facial structure interpretation (Botha, 1998).

## **2.7.1 Complications during piercing**

### **2.7.1.1 Haemorrhage**

The tongue is vascular and it will bleed during the procedure, but this bleeding is easily controlled, however extreme haemorrhaging should receive immediate attention (Peticolas et al, 2000). Bleeding is not a frequent complication of tongue piercing, due to the fact that the tongue is most frequently pierced in the midline, while the lingual arteries and veins run laterally (Boardman and Smith, 1997). Cases of prolonged bleeding from the tongue subsequent to a piercing have been reported (Rosivak and Kao, 2002; Shacham et al, 2003). Although a number of haemostatic options are available to treat soft tissue bleeding, for example, the use of pressure with gauze or cotton wool, topical haemostatic agents such as aluminium chloride, silver nitrate, ferric sulphate, and topical thrombin, or a local anaesthetic containing a vasoconstrictor (Rosivak and Kao, 2003), these reports add to the available literature describing possible detrimental sequelae following intraoral piercing.

### **2.7.1.2 Nerve damage**

The tongue is innervated by the Facial, Trigeminal, Hypoglossal, and Glossopharyngeal nerves, which may be damaged during piercing. Depending on which nerves are affected or damaged during the procedure, motor or sensory (taste) defects may occur (Peticolas et al, 2000).

### **2.7.1.3 HIV, Hepatitis, Tetanus, and other communicable diseases**

Sterilisation of equipment and the use of disposable needles are imperative as piercings involve blood and body fluids. Any of the above conditions may arise if precautions are not taken (Peticolas et al, 2000). In the United States, the National Institute of Health

has identified piercing as a possible vehicle for the transmission of hepatitis B, C, D, and G, and the HIV virus (Ram and Peretz, 2000).

## **2.7.2 Complications immediately following piercing**

### **2.7.2.1 Local inflammation of the tongue**

Local inflammation of the tongue will result in swelling, which can affect speech, mastication, and deglutition. These effects may last up to three to five weeks, and may be treated with a saline rinse (Peticolas et al, 2000).

### **2.7.2.2 Localised infection**

Infection can be prevented by meticulous aftercare. Should infection occur, systemic antibiotics and chlorhexidine rinses hasten healing (Peticolas et al, 2000). A review of the literature illustrates the case of a 20-year-old-woman who had her tongue pierced six days earlier, and presented with a swelling of the floor of the mouth and tongue, as well as a submental swelling. Local erythema and heat accompanied the swelling, and her elevated white blood cell count was indicative of polymorphonuclear leucocytosis. She was treated with antibiotics, the ornament was removed, the condition improved by the following day, and the infection was fully resolved within a week (Shacham et al, 2003).

### **2.7.2.3 Trauma to lingual gingiva**

The tendency to 'play' with the tongue piercing may result in erythema or oedema of the gingiva. This occurs from placement of the dorsal ball against the maxillary lingual tissue, or the ventral ball against the mandibular lingual tissue (Peticolas et al, 2000).

Ram and Peretz (2000) discuss the case of a patient complaining of a painful tongue a week after piercing. Oral examination revealed an inflamed and oedematous lesion around the stud, sensitive to touch. The patient had been diagnosed with a ventricular septal defect, which required prophylactic antibiotics prior to dental treatment. As this was “only a tongue piercing,” the patient did not take antibiotics. The patient was instructed to use a chlorhexidine mouthwash three times daily for a week, and the site healed uneventfully after two weeks (Ram and Peretz, 2000).

Another case report (Botha, 1998) is that of a 28-year-old female patient who was consulted for a crown lengthening procedure. Clinical examination revealed an asymptomatic lesion on the dorsal and ventral surfaces of the tongue, without any signs of inflammation. The patient reported having her tongue pierced some years previously, and the initial stud inserted was too short, causing pressure during healing, resulting in the lesions. This is an example of inflammation of the pierced site in the tongue, which healed by fibroplasia (Botha, 1998).

#### **2.7.2.4 Bacteraemia**

Bacteria introduced during piercing can result in a systemic infection. This may be characterised by symptoms such as fever, chills, shaking, or a red streaked appearance near the site of piercing (Peticolas et al, 2000).

#### **2.7.2.5 Ludwig’s angina**

This condition involves an inflammation of connective tissue, which spreads rapidly to involve the submandibular, submental, and sublingual spaces. It results in painful

swelling of the tongue, difficulty in speaking and swallowing, and compromised airway. Immediate professional intervention is essential (Peticolas et al, 2000).

Ludwig's angina has been reported in the literature (Perkins, Meisner, Harrison, 1997; Rosivak and Kao, 2002), where a 25-year-old woman was referred to hospital by her medical practitioner, for pain and swelling of her tongue and the floor of her mouth. The patient also presented with swelling of the submandibular, sublingual, and submental spaces. Four days prior to the referral, she had a metal barbell placed in her tongue and her medical practitioner had prescribed Amoxyllin capsules twenty-four hours earlier (Perkins, Meisner, Harrison, 1997). The patient required hospitalization for eight days, during which she received intravenous antibiotic therapy, and two nasal intubations, before recovery. Due to several complications during treatment, a presumptive diagnosis of secondary neurogenic diabetes insipidus was made (Rosivak and Kao, 2002).

It is difficult to determine how commonly infective or other complications occur, but the severity of the complications suffered by this patient, make it obvious that a good medical history, and knowledge of possible complications, is essential in the practice of tongue piercing.

### **2.7.3 Long - term complications**

#### **2.7.3.1 Tissue Hyperplasia**

Tissue overgrowth can occur at the site of piercing, and this may be accompanied by pain and oedema. The tissue can be excised, the wound treated, and the barbell re-inserted (Peticolas et al, 2000).



**Figure 9: Tissue overgrowth at site of piercing**



#### **2.7.3.2 Dehiscence**

Over time, the ball of the labrette or barbell rubbing against the mandibular anterior facial gingiva, can create a dehiscence. This may occur at any location where metal continually abrades against soft tissue (Peticolas et al, 2000).

#### **2.7.3.3 Fractured/Cracked Teeth**

Damage to teeth can result from careless insertion, or during chewing and eating, or from parafunctional oral habits, and playing with the barbell against the teeth. Maxillary or mandibular teeth can sustain chipping, resulting in sensitivity to cold and sweets (Peticolas et al, 2000). The most prevalent injuries include chipping of enamel, cuspal fractures, and deep-seated cracks extending to the pulp (Brooks et al, 2003).

Two cases of fracture to teeth were reported by Ram and Peretz (2000). In the first case, a 17-year-old female complained of sensitivity of a maxillary lateral incisor, particularly when having cold drinks and when breathing through the mouth. Clinical

examination revealed a small enamel-dentine fracture, and a barbell stud on the anterior portion of the tongue. The patient reported that she habitually knocked on the teeth with the device. She decided not to restore the tooth until she removed the device, as the habit of knocking on the tooth could not be stopped (Ram and Peretz, 2000).

In the second case, involving a fifteen-year-old girl, the complaint was a fractured maxillary left central incisor and a mandibular right central incisor, which she wanted reconstructed. The patient had the tongue piercing for three months and the fractures had occurred two months prior to the visit when she knocked the stud against the teeth. This patient also decided not to restore the tooth for the moment, after being informed that the restoration would fail as long as the habit of knocking the stud against the teeth continued (Ram and Peretz, 2000).

A case report by Brennan et al (2006) draws attention to the possibility of multiple dental fractures as a result of trauma incurred from a barbell inserted into the tongue. An eighteen-year-old female reported to the Accident and Emergency Department of the Dublin Dental School and Hospital, complaining of sensitivity to cold drinks and when breathing, and concern about chipped teeth. On examination, fractures of teeth 15, 24, 34 and 36 were observed. In addition, there was loss of incisal edge integrity, on the incisal edges of teeth 11 and 21. A barbell stud had been inserted in the anterior aspect of the tongue one year previously. The patient reported that she habitually knocked the device against her teeth, and closed her mouth holding the device between the maxillary and mandibular teeth. She also had a habit of flicking the dorsal cap of the barbell along the occlusal aspects of her teeth on the right side. She indicated that the barbell had initially been placed, with the steel cap on the dorsal aspect of the

tongue, and the plastic cap on the ventral aspect. After being informed by a friend that this was incorrect, the patient reversed the placement of the ornament. The risks of further fractures were explained to the patient, and the teeth were restored with composite resin restorations (Brennan et al, 2006).

**Fig 10: Lingual barbell knocking against incisal edge**      **Fig 11: Chipped incisal edge**



#### **2.7.3.4 Gingival recession and Tooth abrasion**

Repeatedly pressing the tongue barbell against the mandibular lingual gingiva can lead to slight, moderate or severe recession of soft tissues. Labrette or lip piercings can cause recession of the mandibular facial gingival. Similarly, the jewellery can cause abrasion of the dentition (Peticolas et al, 2000).

There have been several reports of gingival recession (Brooks et al, 2003; Chambrone and Chambrone, 2003; Keiser et al, 2004), and fractures of dentition (Ram and Peretz, 2000; Brennan et al, 2006). A case report of a 19-year-old female college student with dental hypersensitivity and gingival recession, who had undergone lip piercing six months earlier, is presented: Clinical examination revealed gingival recession on the



buccal gingival walls of both lower central incisors, and exposed roots, which were abraded by the piercing barbell. Removal of the traumatic agent, and correction of the mucogingival defect, resulted in recovery within five months, with the absence of dental hypersensitivity (Chambrone and Chambrone, 2003).

In their article ((Brooks et al, 2003) present five case reports of patients who experienced mild to moderate gingival recession after having lip or tongue piercings. A study in New Zealand, investigating the periodontal and dental trauma resulting from lip and tongue piercings (Keiser et al, 2005), found that of the forty-three individuals who participated, most of those (80%) with a labial piercing had 1+ labial site with gingival recession. Almost one-third of those with a tongue piercing had at least one lingual site with gingival recession. These findings suggest that oral piercings were associated with localized gingival recession (Keiser et al, 2005).

The number of cases in which oral and dental complications are associated with lip piercings is smaller than those related to tongue piercings (Chambrone and Chambrone, 2003).

In a report describing the association of multiple piercings with localized gingival recession, by Er et al (2000), the patient, a twenty-six year-old female university student had a piercing in the median lower lip area, and multiple piercings on her tongue. On examination, root exposure as a result of gingival recession of the mandibular right incisor was observed. The patient stated that the exposure occurred after the placement of the barbell on the lower lip. Contrary to advice, the patient refused to remove any of the piercing jewellery (Er et al, 2000).

Another case report (Kretchmer and Moriarty, 2001) illustrates the destructive nature of the jewellery with respect to teeth, gingival and alveolar bone. A twenty-two-year-old male was admitted to the University of North Carolina at Chapel Hill Department of Periodontology for an evaluation of the mandibular anterior sextant. Clinical examination revealed localized inflammation, the presence of plaque and calculus, loss of attachment and bleeding on probing. Calculus was also present on the ventral ball of the tongue stud. Treatment included removal of plaque and calculus and flap curettage, and the patient removed the piercing. A six-month follow-up visit by the patient revealed that the attachment loss had stabilized (Kretchmer and Moriarty, 2001).

**Fig 12: Gingival recession**



#### **2.7.3.5 Aspiration or Ingestion**

Aspiration or ingestion of jewellery parts can occur at any time during insertion or removal. The barbell consists of a metal bar connecting two balls. One side of the bar has threads for screwing the ball into position, if the ball becomes loosened, there is the potential for swallowing or aspirating it (Peticolas et al, 2000). The swallowing of a portion of a barbell placed on the tongue has been reported (Boardman and Smith, 1997; De Moor et al, 2000; Cheong, 1984).

#### **2.7.4 Other Complications**

Other complications in the literature include the barbell becoming embedded in the tongue, a brain abscess that followed a tongue piercing and endocarditis after a tongue piercing.

Two cases of a barbell becoming embedded in the tongue are described in the literature. In the first case (Shacham et al, 2003) a sixteen-year-old girl tried to remove the barbell inserted in her tongue approximately two years earlier. She unscrewed the ball but pulled the barbell in the opposite direction, inserting the ball in her tongue. Under local anaesthetic, an incision was made, the ornament was removed, and the patient was discharged the following day without any adverse effects (Shacham et al, 2003).

Theodossy (2003) describes how the ventral surface of the tongue healed over the barbell, requiring surgical intervention. Two weeks after having a piercing and barbell placed, a patient presented to the emergency department, as she was unable to remove the barbell, which was completely embedded in her tongue. The barbell had to be removed under local anaesthetic, and the tissue under the surface of the tongue had become fibrosed (Theodossy, 2003).

A brain abscess in a twenty-two-year-old woman is reported (Rosivak and Jao, 2003; Martinello and Cooney, 2003). The patient who had a midline tongue piercing, reported pain, swelling, and a purulent discharge two days after the procedure. On removing the stud, the local inflammatory symptoms resolved. However, four weeks later, she experienced nausea, headache, vomiting, and vertigo, which would not be relieved by

analgesics (Martinello and Cooney, 2003). The patient received a six-week course of antibiotics, and her symptoms resolved (Rosivak and Jao, 2003).

There are several case reports of endocarditis associated with piercing. A study by Akhondi and Rahimi (2002) of a twenty-five-year-old man who reported to Memorial Health University Medical Centre, with fever, chills, rigors, and shortness of breath, of six days duration. The patient had an aortic valvuloplasty, and body piercing poses a risk because it invades subcutaneous areas, and could cause infectious complications. On examination, there was no local sign of infection, the patient was treated with a six-week course of antibiotics, through a peripherally inserted catheter line at home (Akhondi and Rahimi, 2002).

Dubose and Pratt (2004) reported on a previously healthy eighteen-year-old woman who developed endocarditis and subsequent emboli to the brain after initial blood-borne infection from a pierced tongue. Four days after the piercing, she allowed a male friend to use her piercing stud to reopen the site of his previously pierced tongue. She immediately replaced the stud in her newly pierced tongue, without sterilizing it. Over the ensuing six weeks, she developed fevers, nausea, malaise, and dyspnea on exertion. Broad-spectrum antibiotic therapy was initiated, and she ultimately underwent surgical intervention because of septic embolisation. She ultimately made a full recovery, and was discharged from hospital after thirty-five days (Dubose and Pratt, 2004).

A case of a twenty-seven-year-old man, with a history of intravenous drug abuse was reported by Lick et al (2005). Since a tongue piercing six weeks previously, the patient had experienced stabbing flank pain, intermittent fevers, chills, and fatigue. A

presumptive diagnosis of infective endocarditis was made, and the patient was treated with intravenous antibiotics, after which he made an uneventful recovery (Lick et al, 2005).

Until more light is shed on the relationship between piercing and endocarditis, prophylactic measures are indicated and should be formulated for people at high risk (Akhondi and Rahimi, 2002).

## **2.8 SELECTION OF JEWELLERY**

The jewellery should be made of inert, non-toxic metal substances (Peticolas et al, 2000). Surgical stainless steel, titanium and a plastic called bioplast, are recommended, and used. If gold is used, it should be 14k or 18k. Silver plating and finishes that may wear off quickly leave abrasive brass that predisposes the pierced site to infections and allergic responses (Peticolas et al, 2000).

## **2.9 SUMMARY**

This chapter detailed the literature available as follows: Background to body piercing, contemporary piercing procedure, the healing process and body piercing aftercare, types of oral piercings, complications and risks associated with oral piercings, and the selection of jewellery.



## **CHAPTER 3:**

## **AIMS AND OBJECTIVES**

### **AIMS**

The aims were twofold, firstly to investigate the sites of oral piercings, complications and oral hygiene procedures practised by piercees, and secondly to investigate the attitude and behaviour of piercers towards infection control and prevention of complications.

### **OBJECTIVES**

- To determine the different sites of intra- and perioral piercing in the sample
- To determine the type of material used as intra- and perioral jewellery
- To determine the post-piercing oral hygiene procedures practised by the sample
- To determine the problems and complications related to intra- and perioral piercing
- To determine the attitude and behaviour of piercers towards the prevention of complications

## **CHAPTER 4: RESEARCH DESIGN AND METHODOLOGY**

### **INTRODUCTION**

Since piercing of the body is most common among teenagers and young adults, the study sample of piercees was obtained at secondary schools and colleges in the Tshwane area. Body piercers work in a non-regulated environment and since body piercing, particularly piercings of the oral and perioral tissues is becoming a common practice, a study of the attitudes and knowledge of piercers and piercees was conducted in the Tshwane area.

This chapter describes the study design, sample, survey method, how the questionnaire was piloted, data entry and method of analysis.

#### **4.1 CHOICE OF RESEARCH METHOD**

The choice of research method is related to the aim of the study, and will depend on the type of information required. There are a variety of research methods available, none of which are necessarily superior to the other, but are used for different purposes. In this chapter, reasons will be put forward for the use of the qualitative and quantitative methodology.

##### **4.1.1 Qualitative Research**

Qualitative research has a number of characteristics, which differ from quantitative research. The most fundamental being its express commitment to viewing actions, events, norms, values, attitudes, etc. from the perspective of the population that is being studied.

This type of approach clearly involves a willingness to empathize with those being studied, as well as a capacity to penetrate the frames of meaning in which they operate. Consequently, this results in data, which is largely textual in nature, but also based in the language and experiences of the informants. Qualitative research aims to achieve this by means of deliberate interaction between the researcher and those being researched.

One of the main purposes of qualitative research is to provide a detailed description of the social aspect of those being investigated. An important contribution of descriptive detail for the researcher, is to produce analyses and explanations which do justice to the context in which his or her observations and interviews are conducted.

Qualitative research tends to favour a strategy that is relatively open and unstructured, rather than one, which has decided in advance, precisely what ought to be investigated, and how it should be done. In this way, it is argued that this open research strategy enhances the opportunity of encountering entirely unexpected issues, which may be of interest to the researcher.

Qualitative research methods are:

- characterized by small numbers of subjects chosen for convenience, but not necessarily representative of the entire population
- open ended and dynamic processes where the interviewer plays a crucial role in the data collection process
- concerned with uncovering and exploring data, rather than counting it



- able to use a wide variety of techniques to collect data, including in-depth interviews, group interviews, participant observation and projective techniques
- led by the respondents' priorities and are therefore more representative of their views
- concerned more with what things exist and why, rather than how many

#### **4.1.2 Sampling Errors**

Sampling errors may occur if care is not taken in the choice of participants.

#### **4.1.3 Non-sampling errors**

Non-sampling errors may result from the possibility of respondents wishing to give socially desirable responses, particularly in group interviews. Inexperienced interviewers, and the researcher's prejudices may also influence the analysis.

### **4.2 STUDY DESIGN**

In this study, there were many factors that influenced the choice of research method chosen. These were:

- the aims of the study
- the review of the literature
- the advantages of qualitative and quantitative methodology
- the acceptability of the research method to the participants

### **4.3 STUDY SAMPLE**

Convenience sampling was the method chosen for the selection of participants. This method involves selecting anyone who is available and convenient to include in the study. The size of the sample was determined by the number of participants available to the researcher that would result in a meaningful study.

#### **4.3.1 Piercees**

Learners attending secondary schools and colleges in the Tshwane area were included in the study population. Verbal permission was sought to visit these institutions, and where requested, letters were sent to the administrators of the relevant schools requesting permission to conduct the study (Appendices A, B, C and D).

#### **4.3.2 Piercers**

Piercers, working at tattoo parlours and piercing studios, in and around the Tshwane area were located by asking the learners interviewed where they had been for the procedure. A few were identified from the local telephone directory, while others were located in shopping malls and flea markets. Some were referred by fellow piercers.

### **4.4 DATA COLLECTION AND CAPTURING**

For this study, it was decided that a self-administered questionnaire with open and closed ended questions was the most appropriate way to elicit the required information, from both, the piercees (participants with piercings), and the piercers (participants who perform the piercing procedure).

Consent forms and questionnaires drawn up by the researcher were distributed to participants. This form was used to record data, which was then captured on computer using Minitab (Database prepared in Microsoft Access application).

## **4.5 INSTRUMENT**

A questionnaire is used to collect factual and/or attitudinal data for measurement. It needs to be well designed to elicit accurate and valid responses.

### **4.5.1 Design Rules**

The questionnaires in this study were designed to:

- Suit the aims of the study
- Be clear, unambiguous and simple to understand
- Minimize potential errors from respondents
- Encourage co-operation and not to alienate the respondent
- Elicit an honest response and avoid leading the respondent to answer in a particular way
- Enable an efficient and meaningful analysis of the data acquired

### **4.5.2 The development of the study questionnaire**

Planning of the questionnaire began in February 2006. After a review of the literature and discussions with the supervisor, the questions were formulated and the questionnaire completed.

### **4.5.3 Piloting the questionnaire**

A self-administered survey questionnaire was created, and tested in a pilot study. The pilot study was carried out to:

- Test the suitability of the method of collecting data
- Check the adequacy of the questionnaire
- Ensure that all questions were clear and unambiguous
- Remove any items that did not yield usable data

### **4.5.4 Preparation of final questionnaire**

After the pilot study, irrelevant and ambiguous questions were identified, and either reformulated or deleted. The tool was thus adapted and refined for use in the study. This resulted in an improved and redesigned questionnaire and an increase in the efficiency of the enquiry. Those questionnaires completed during the pilot study were included in the results.

The questionnaire consisted of fifteen questions on the following issues:

- General information
- Reason for having a lip and/or tongue piercing
- Complications associated with piercing
- Oral hygiene care.

## **4.6 PROCEDURE**

In order to set up the study, a letter (Appendix E) was sent to the Acting Deputy Chief Education Specialist: Policies and Planning, at the Department of Education, in Tshwane. A meeting was subsequently arranged, at which the nature of the study was discussed.

The researcher was then presented with a document (Appendix F) outlining the procedure to be followed, when applying to do research in GDE schools.

Permission to proceed (Appendix G) was obtained, after submitting a covering letter (Appendix H) and the following documentation:

- Research request form
- Protocol
- Questionnaire and Consent form
- Declaration by Supervisor

### **4.6.1 Survey of piercees**

All researchers are dependant on the availability and goodwill of their subjects. After an initial meeting with the counsellor at the Student Support Centre of a college, it was decided to place posters at strategic points in the college building and grounds, informing and encouraging students to be interviewed, at the Student Support Centre (Appendix I and J).

On the day of the interviews, an announcement on the public address system, reminded students of the interview. Students came in either alone, or in groups of two or three.

The researcher introduced herself, explained the purpose of the study, and informed participants that all information was to be confidential and used for purposes of the study only. The consent forms (Appendix K), self-administered questionnaires (Appendix L) and pens were handed to each participant. Participants were requested to answer all questions, and to complete the consent form. A similar procedure was followed at three more colleges in Tshwane.

Where secondary schools were concerned, the procedure followed was somewhat different. Secondary schools on the list provided by the Department of Education were selected for convenience. The principals of the schools were contacted telephonically, and the purpose of the study was explained. An appointment was arranged at the convenience of the school concerned.

On arrival at the schools, it was arranged that all participants (those learners with piercings that were willing to participate in the study) would be assembled. The researcher introduced herself, and explained the purpose of the study to the learners. Participants were also informed that all information was confidential and would be used for purposes of the study only. The consent forms, questionnaires and pens were then distributed, and learners were asked to complete all questions and read, and sign the consent form. The survey instrument was designed to be non-intrusive and simple to complete to ensure a high response rate. Although self-administered, participants had an opportunity to verify anything that they did not understand, as the researcher was available to explain any questions that were ambiguous or unclear.



#### **4.6.2 Oral Examination**

All participants were examined visually for the different types and sites of piercings, and associated complications. With the consent of participants, photographs were taken to illustrate the sites of piercings and problems that may have occurred. The participants were informed that the photographs would be taken of the piercing and/or problem only, and they would not be identifiable. All photographs were taken with a digital camera, and the picture was shown to the participant for approval.

#### **4.6.3 Survey of piercers**

A second consent form (Appendix M) and questionnaire (Appendix N) was designed to assess the behaviour and precautions taken by tongue piercers towards infection control, and aftercare instructions that may be given to piercers.

The questionnaire of eleven open and closed ended questions, contained questions relating to tongue and lip piercings, including:

- The use of local anaesthesia
- The use of disposable needles
- Cross-infection and hygiene measure
- Type of material used for piercings
- Aftercare instructions
- Management of complications

The researcher gave a brief background about the research project, and the aims of the study were explained to the potential participant before consent was obtained. It was pointed out that all information collected would remain confidential, and used for

purposes of the study only. Participants who agreed to take part in the study were interviewed at their workplace by the researcher.

An administered questionnaire, consisting of eleven questions, was completed by piercers, to obtain an accurate and valid response. Participants were given the opportunity to add their own comments at the end of the interview. The completed questionnaires were coded, and the responses entered into a spreadsheet for analysis.

#### **4.7 VALIDITY AND RELIABILITY**

Only the researcher was involved in conducting interviews, taking photographs, keeping records, gathering, entering, and interpretation of data, thereby ensuring confidentiality and standardized recording of information.

#### **4.8 LIMITATIONS**

- The time since piercing in the sample varied, which could result in recall bias
- Sensitivity of certain questions e.g. ethnic group
- Difficulty of ascertaining socio-economic status of piercees
- Difficulty in determining the demography of the sample

#### **4.9 ETHICAL CONSIDERATIONS**

The protocol was submitted to the Senate Research Committee at the University of the Western Cape for approval. Approval was obtained – approval number 04 / 5 / 13.

Written permission was obtained from the District Director, Department of Education, to visit secondary schools and tertiary colleges, in order to interview learners with piercings (Appendix G).

Permission was also obtained from the Principals and/or Student Support Counsellors at the institutions to interview learners. With the assistance and co-operation of these staff members appointments were arranged.

The purpose and benefits of the study was explained to the participants. Written consent was obtained from the students to participate in the study (Appendix K). They were reassured that all information obtained will be kept strictly confidential and will only be used for the purpose of the study.

The study was non-invasive and carried out on the college and/or school premises. A copy of the completed study will be sent to all the schools and colleges that participated, and to the District Director, Department of Education.

#### **4.10 STATISTICAL ANALYSIS**

Descriptive and inferential statistical analyses were carried out, to evaluate the responses of the study participants to the two questionnaires. The data from the two questionnaires were analysed separately.

Data was firstly captured from the questionnaires, entered into Microsoft Exel, and the SPSS package was used to analyse the data. For the closed-ended questions, a 'yes' answer yielded a value of one, and 'no' was assigned a value of zero, to facilitate counting. For open-ended questions numerical values were assigned to the answers. Data was subjected to tests of association like Chi-square tests.

#### **4.10 SUMMARY**

This chapter detailed the research design and methodology, from the choice of research method, study sample and study design, through data collection, instrument, and procedure, to validity, ethical considerations, and statistical analysis.

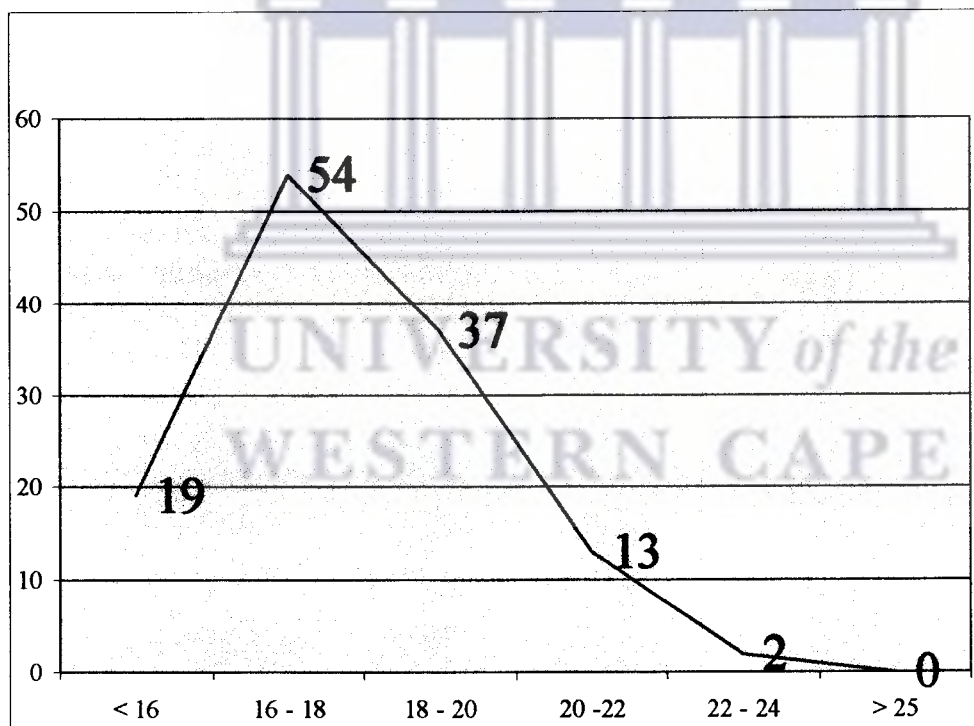
## CHAPTER 5: RESULTS

### 5.1 SURVEY OF PIERCEES

#### 5.1.1 Response rate

All the piercees interviewed, were learners at secondary schools, and students at colleges in the Tshwane area. Not every student/learner who had a piercing took part in the study. One hundred and twenty six piercees completed the self-administered questionnaire and immediately handed it to the researcher.

#### 5.1.2 Age

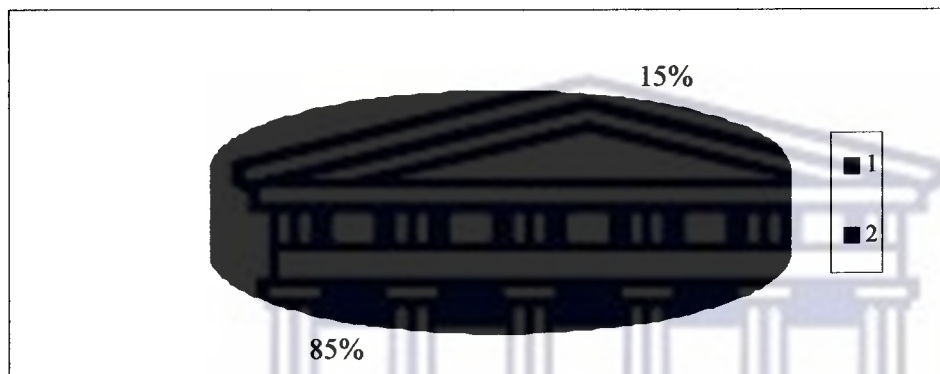


**Figure 13: Age distribution of the sample**

The participants ranged in age from fourteen to twenty-four, with mean age of 17.46 years, median of 17 years, and standard deviation of 1.86 years (variance of 3.45 years).

The majority of respondents, consisting of 42.86% (n = 54) of the sample were in the 16-18 age group. This was followed by 29.36% (n = 37) in the 18-20-year-old category. Nineteen were under 16, thirteen were between 20 and 22-years-old, and two were between 22 and 24-years-old (Figure13).

### 5.1.3 Gender



**Figure 14: Gender distribution**

One hundred and seven of the 126 six respondents were female (85%), (Figure 14).

### 5.1.4 Ethnic group

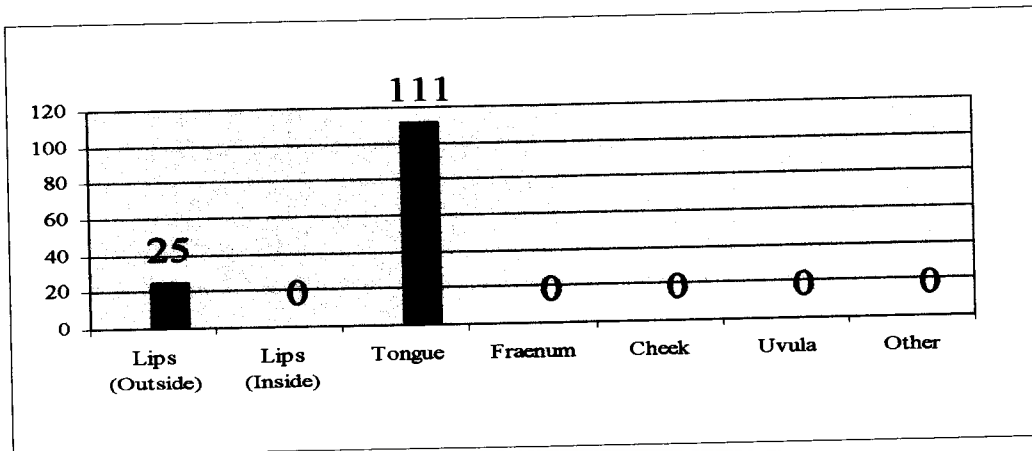


**Figure 15: Ethnic group**

The demography of the sample is illustrated in the above graph.



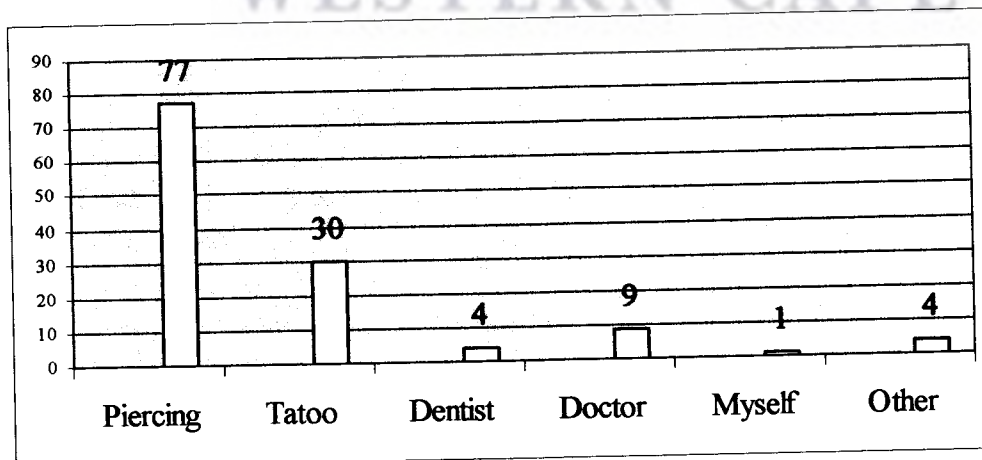
### 5.1.5 Site of piercing



**Figure 16: Site of piercing**

The tongue was the most common site of piercing, <sup>with</sup> (88.10%, n=111) having a tongue piercing, and 19.84% (n=25) having a labrette or piercing of the lower lip. Ten respondents (7.94%) had both the lip and tongue pierced. Other piercing sites mentioned in the literature, such as cheek, uvula and fraenum, were not observed in the present sample (Figure 16).

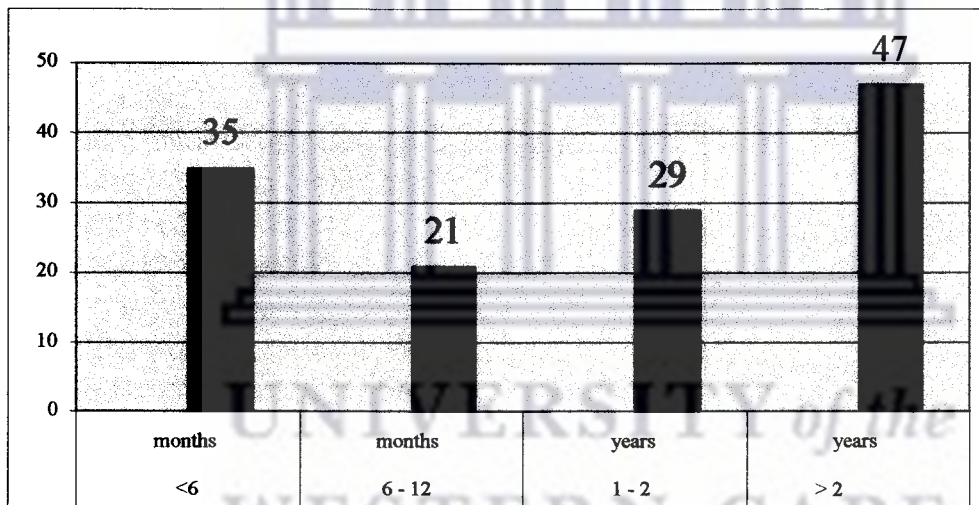
### 5.1.6 Who did the piercing?



**Figure 17: The piercer**

In response to the question “Who did the piercing,” one participant did his own piercing, and one had a friend do it for him. Three had the piercing done at a hairdressing salon. The majority (61.11%, n=77) visited a piercing studio and thirty (23.81%) went to a tattoo studio for the piercing. Four individuals (3.17%) reported that they had the piercing done by a dentist, and nine (7.14%) responded that a doctor had performed the piercing (Figure 17).

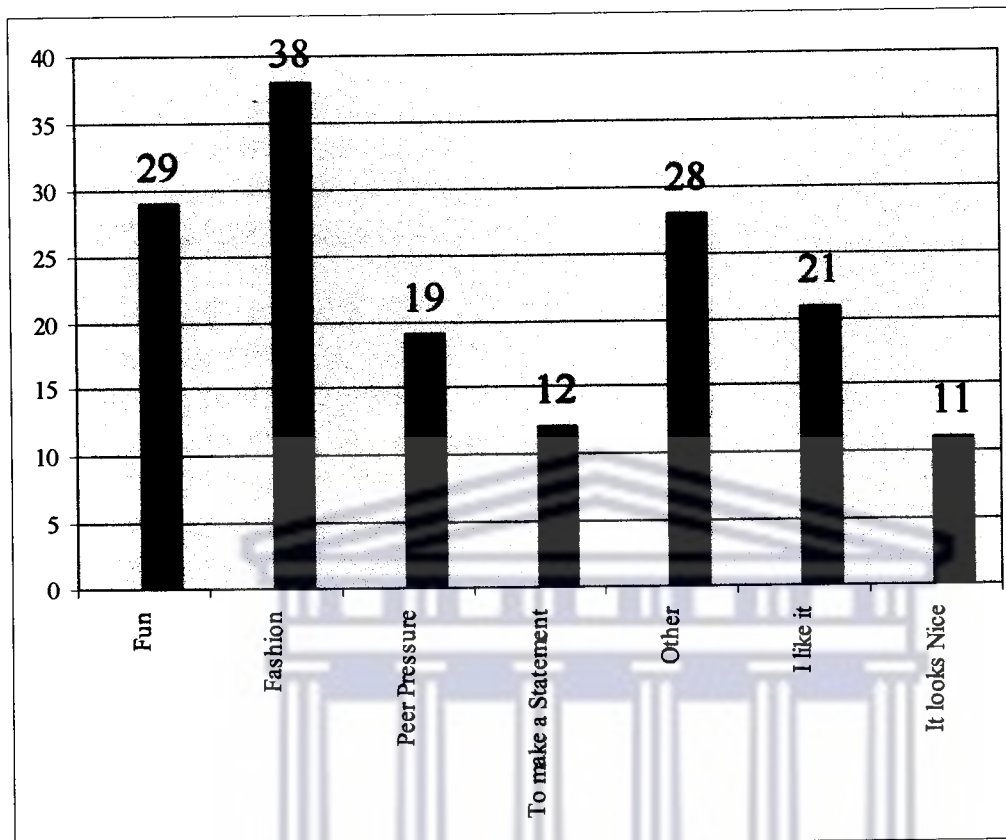
### 5.1.7 Duration of piercing



**Figure 18: Duration of piercing**

The length of time that the piercings had been *in situ* varied from under six months to over two years. The majority of participants (37.30%; n = 47) had the piercing for more than two years, twenty-nine (23.01%) had theirs for between one and two years, while 21 (16.66%) had had theirs for six to twelve months. Thirty-five respondents (27.77%) had their piercings for less than six months (Figure 18).

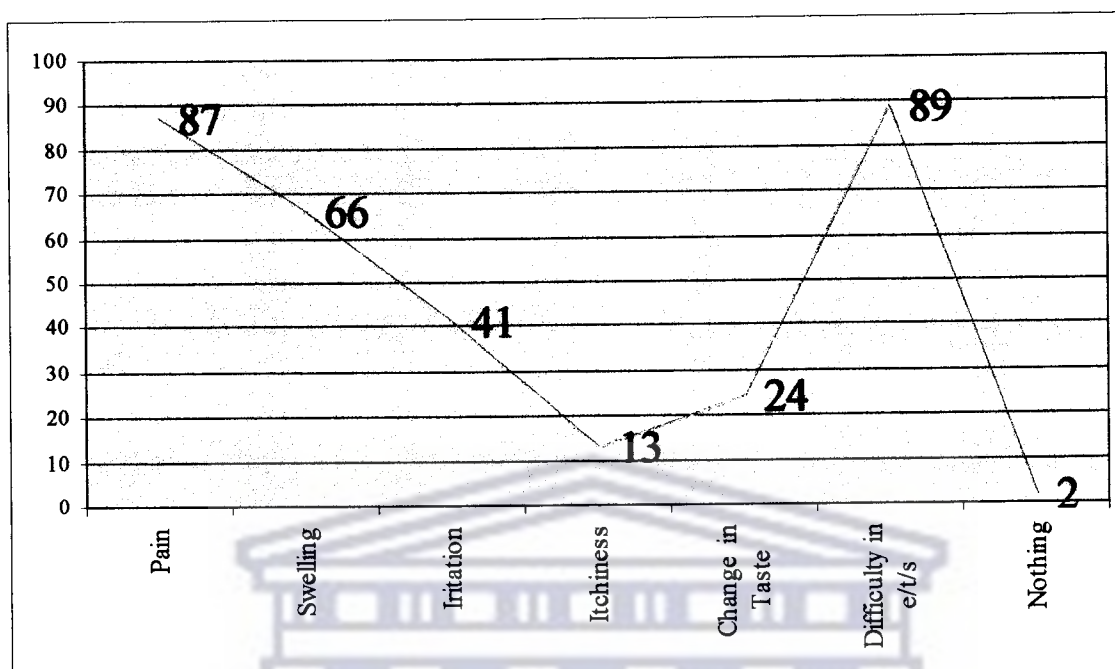
### 5.1.8 Main reasons for piercing



**Figure 19: Main Reason for Piercing**

The reasons reported for piercing were: Fashion (30.16%); Fun (23.01%); Looks nice (16.66%); Peer pressure (15.08%); to Make a statement (9.52%); Like it (8.73%). Other reasons included two respondents wanting to inflict physical pain on themselves, one wanting to annoy her parents, and some reported that they wanted to experience what it would be like to have a piercing. One participant did the piercing in response to a 'dare', and one thought it would help to quit 'thumb-sucking', which it did. Some had the piercing for erotic reasons (Figure 19).

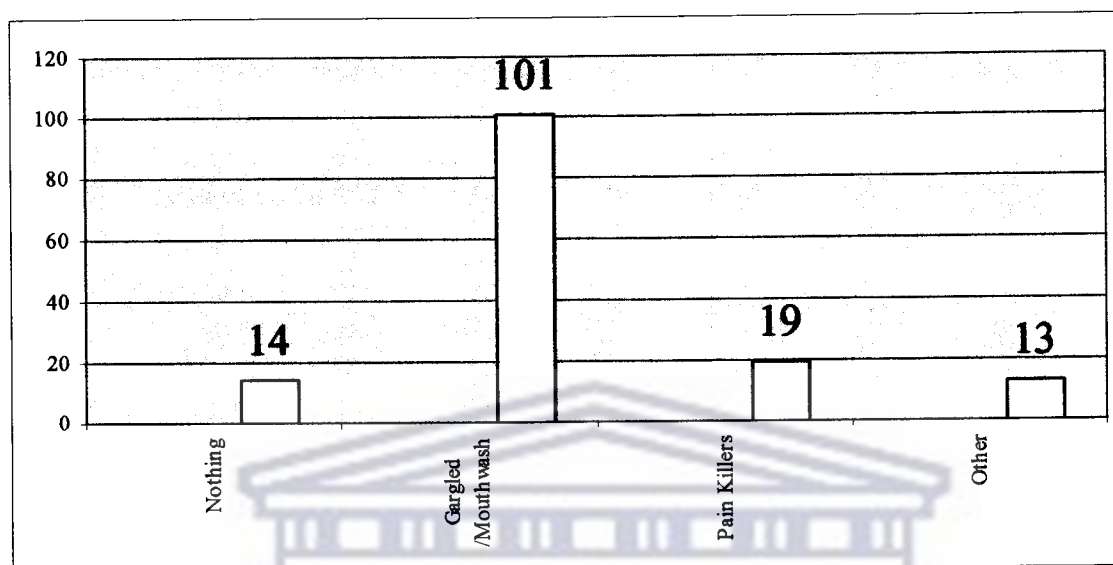
### 5.1.9 Problems immediately following piercing



**Figure 20: Problems immediately following piercing**

Almost all piercees ( $n = 124$ ; 98.41%) experienced problems immediately after the piercing. The most frequently reported problems were difficulty in eating, speaking and swallowing (70.63%), pain (69.05%), swelling (52.38%), irritation (32.54%), change in taste sensation (19.05%) and itchiness (10.32%), (Figure 20).

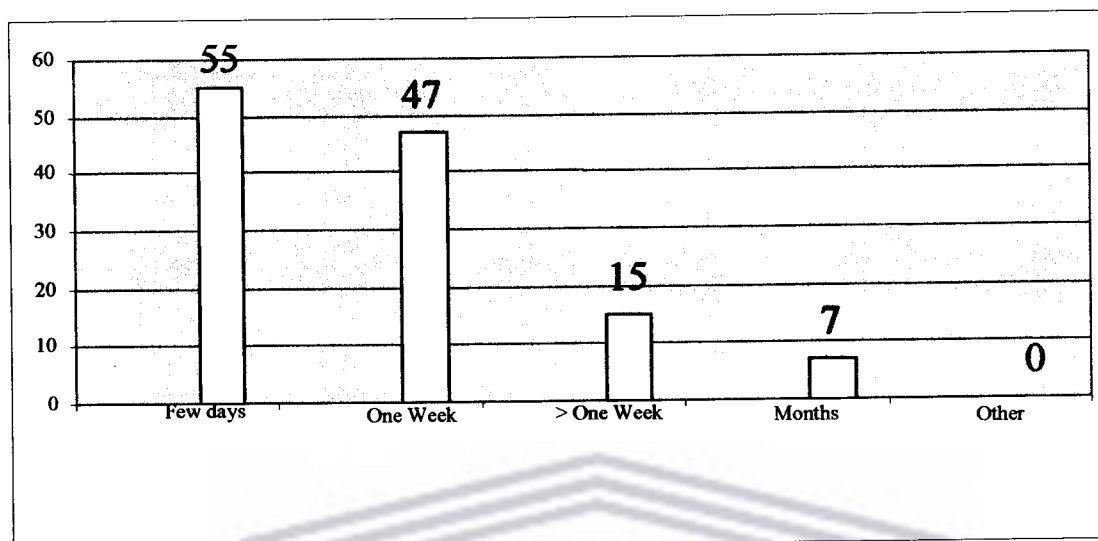
### 5.1.10 Precautions after piercing



**Figure 21: Precautions after piercing**

Gargling with a mouthwash after piercing is the most commonly reported precaution taken by piercees (n = 101; 80.16%). Nineteen (15.08%) reportedly took painkillers, and fourteen (11.11%) said that they did nothing. Other precautions taken included eating ice-cream, sucking on ice, and gargling with a solution of bicarbonate of soda and water (Figure 21).

### 5.1.11 Healing time

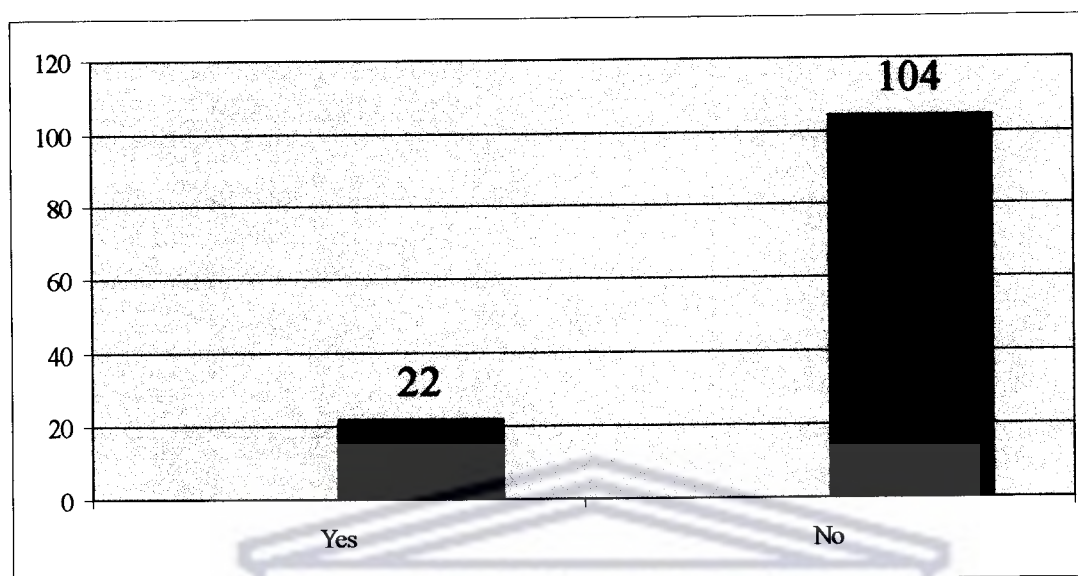


**Figure 22: Healing time**

Healing time varied from a few days to a few months. While fifty-five (43.65%) individuals reported that the site of piercing healed within a few days, forty-seven (37.30%) stated that it took a week to heal. Healing took more than a week in fifteen cases (11.90%), and for a small minority (n = 7; 5.55%) it took a few months (Figure 22).



### 5.1.12 Damage to teeth and/or gums




**Figure 23: Damage to teeth and/or gums**

To determine the amount of damage, participants in the survey were asked whether they had noticed any damage to teeth and gums. The majority of respondents ( $n = 104$ ; 82.54%) reported that they had not experienced any damage to teeth or gums. Twenty-two (17.56%) indicated that some damage had resulted from the piercing. No healing anomalies were observed in the majority of cases, while granulation tissue appeared on the tongue of one individual (0.79%), and one participant reported a hole on her tongue (Figure 23).

There was a statistically significant relationship between site of piercing and damage to surrounding hard and soft tissue. The presence of piercing jewellery on the tongue and/or lip was associated with damage to teeth and gums (Pearson's Chi-Square of 23.66;  $df = 8$  and  $p\text{-value} = 0.003$ ).

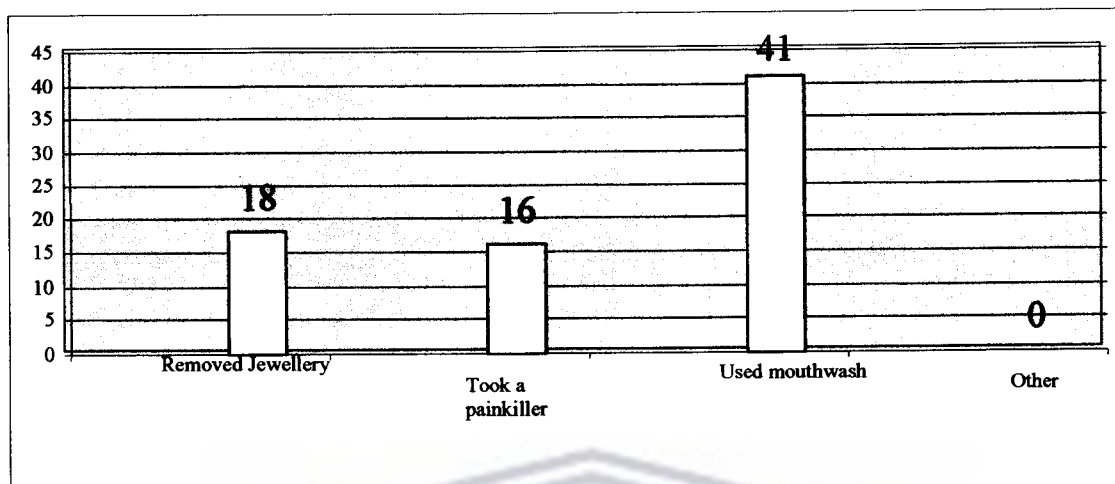
### 5.1.13 Problems since piercing



**Figure 24: Problems since piercing**

The majority of piercees ( $n = 87$ ; 69.05%) did not experience any long-term problems after the piercing. The nature of some of the problems included: pain (20.63%); difficulty eating (11.90%); difficulty speaking (10.32%); infection of piercing (8.73%); difficulty swallowing (5.55%) and swollen glands (5.55%). One individual experienced a metallic taste in the mouth, one reported damage to the palate caused by playing with the jewellery, and one felt that the incisors had become sensitive after the piercing (Figure 24).

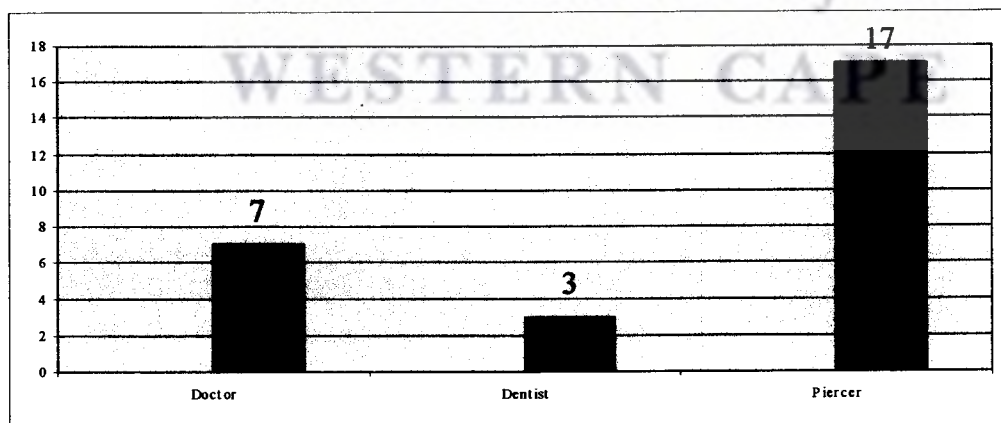
### 5.1.14 Response to problems



**Figure 25: Response to problems**

In response to dealing with problems experienced after a piercing, forty-one individuals (32.54%) used a mouthwash, 18 (14.28%) removed the jewellery, and 16 (12.70%) took painkillers (Figure 25).

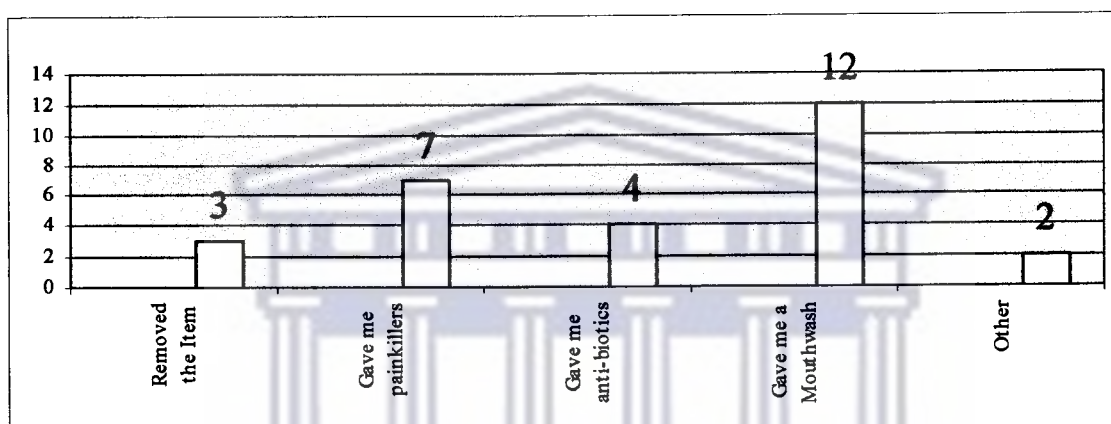
### 5.1.15 Sources of help for problems



**Figure 26: Sources of help for problems**

Twenty-seven participants reported that they had sought advice regarding a problem following the piercing. Seventeen individuals (13.49%) returned to the piercer for help, seven (5.55%) consulted a doctor, and three (2.4%) went to a dentist for treatment (Figure 26).

### 5.1.16 Treatment



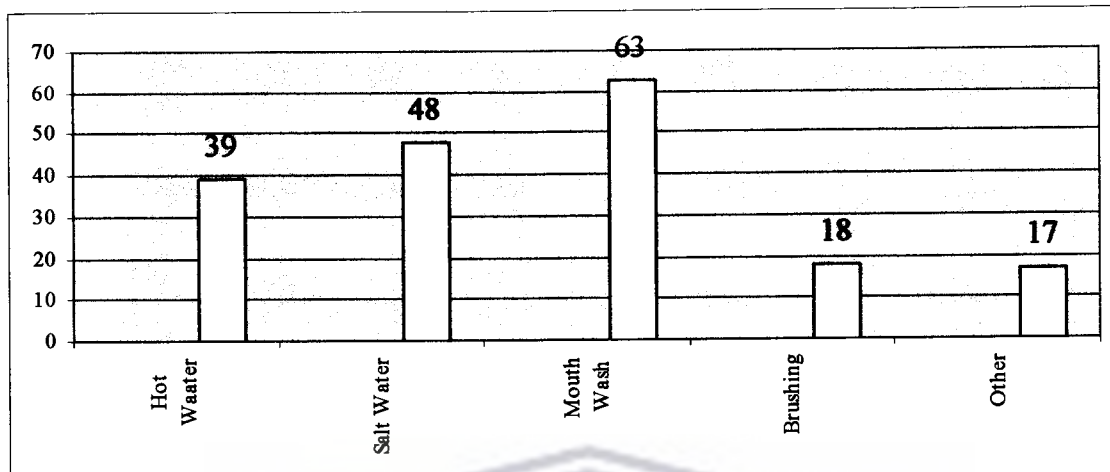
**Figure 27: Treatment**

The following methods of treatment were undertaken to deal with the problems:

Removed the jewellery	2.38%
Given painkillers	5.55%
Given antibiotics	3.17%
Given a mouthwash	9.52%

With regards to any incidents occurring after the piercing, no piercing modifications were required in the majority of cases. One individual reported that the jewellery was changed, and one was re-pierced (Figure 27).

### 5.1.17 Cleaning of piercing



**Figure 28: Cleaning of piercing**

Participants were asked how piercings were cleaned. Half the respondents (50%) used a mouthwash, 48 (38.09%) gargled with salt water, and 39 (30.95%) used hot water. Eighteen individuals (14.29%) stated that they used a toothbrush to clean the piercing. Other methods of cleaning included sterilizing ( $n = 8$ ), four individuals using spirits, one using soap, one who used bleach, and one who cleaned the piercing with toothpaste (Figure 28).

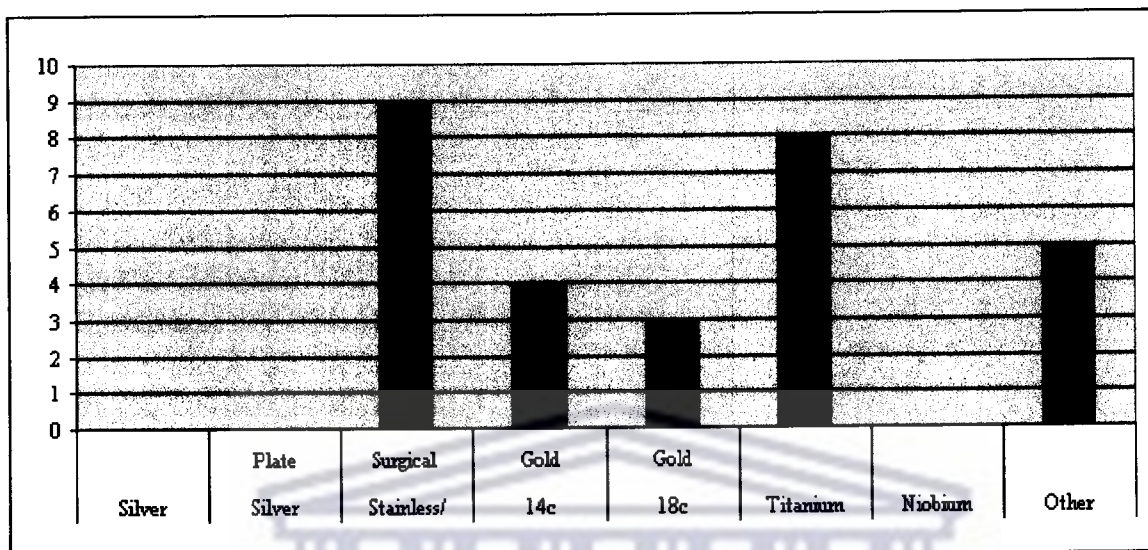
## 5.2 SURVEY OF PIERCERS

### 5.2.1 Response rate

The managers of eleven piercing establishments in Tshwane were contacted either personally or telephonically. One piercer did not perform oral piercings, and one did not wish to take part in the study. Finally, ten piercers, representing nine establishments agreed to complete the questionnaire.



## 5.2.2 Metals used



**Figure 29: Types of metals used**

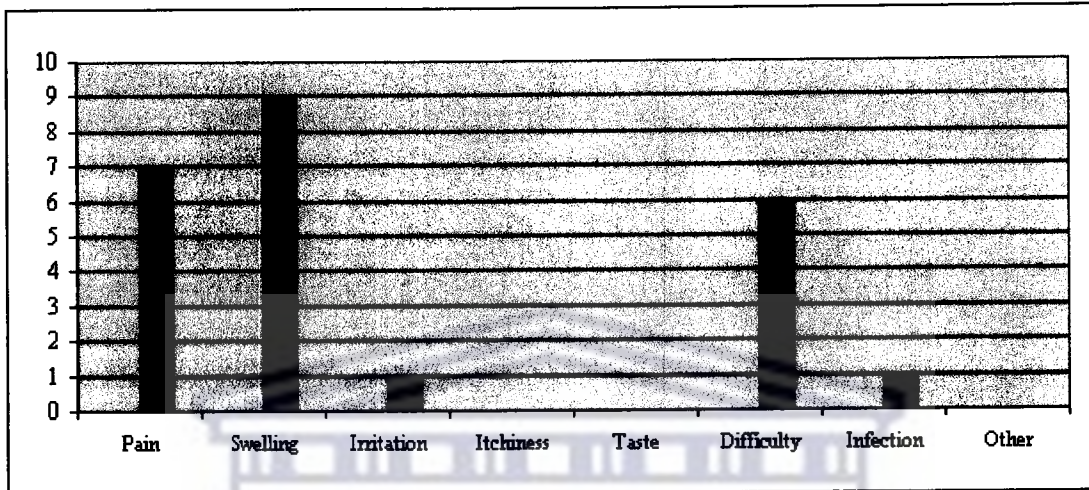
The majority of piercers use stainless steel for piercing, except in the cases of allergies, when titanium is used. Gold is used on request, and 18 and 22-carat gold is preferred to 9 or 14 carat. A new plastic material called bioplast is also reportedly being used by many piercers. This product is flexible and available in long strips, which may be cut to the required length. It is often used in cases of allergies or sensitivity, or for individuals with a short tongue. As bioplast is made in different colours, it was the preferred choice for some individuals. Piercers reported that there is less swelling and less risk of infection with this material (Figure 29).

## 5.2.3 Reported complications

The majority (90%) of piercers said that pain and swelling were the most common complications reported following piercing. One piercer did not consider pain and

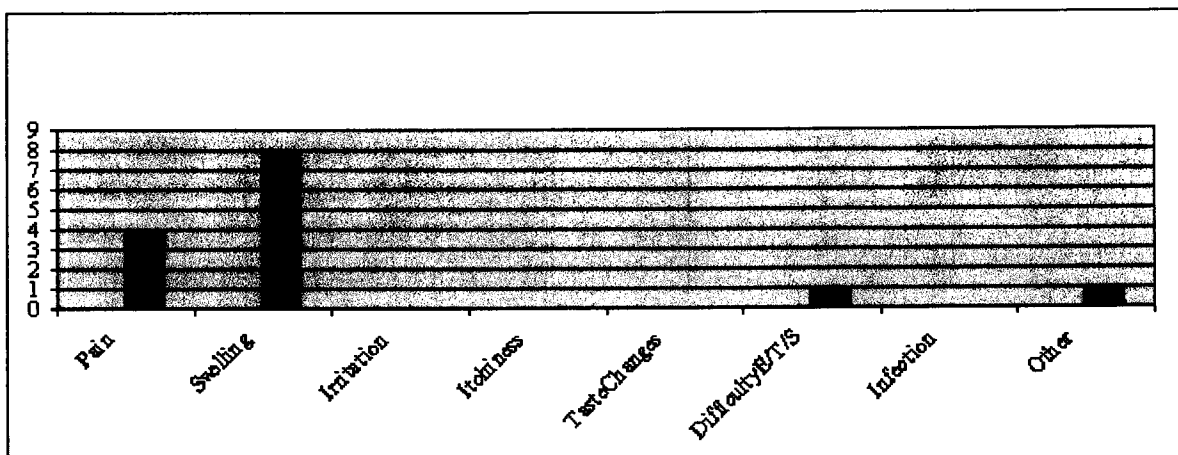


swelling as a “complication” but rather as normal reactions to the piercing procedure and local tissue damage (Figure 30).



**Figure 30: Reported complications**

In response to a list of possible complications, swelling was most commonly reported (90%), followed by pain (70%) and difficulty in eating, talking and swallowing (60%). Eighty percent of the participants reported that swelling was the most common complication, followed by pain (40%) and difficulty eating, speaking and swallowing and discomfort (Figure 31).



**Figure 31: Common complications**

#### 5.2.4 Hygiene and cross-infection measures

While 90% (n = 9) of piercers use an antibacterial disinfectant to clean the site prior to piercing, one respondent did not use anything. Almost three-quarters of the piercers (70%) use a mouthwash prior to piercing, while the remaining 30% use alcohol. All the piercers interviewed, said that they use disposable needles, as all are aware of the risk of cross-infection (Figure 32).

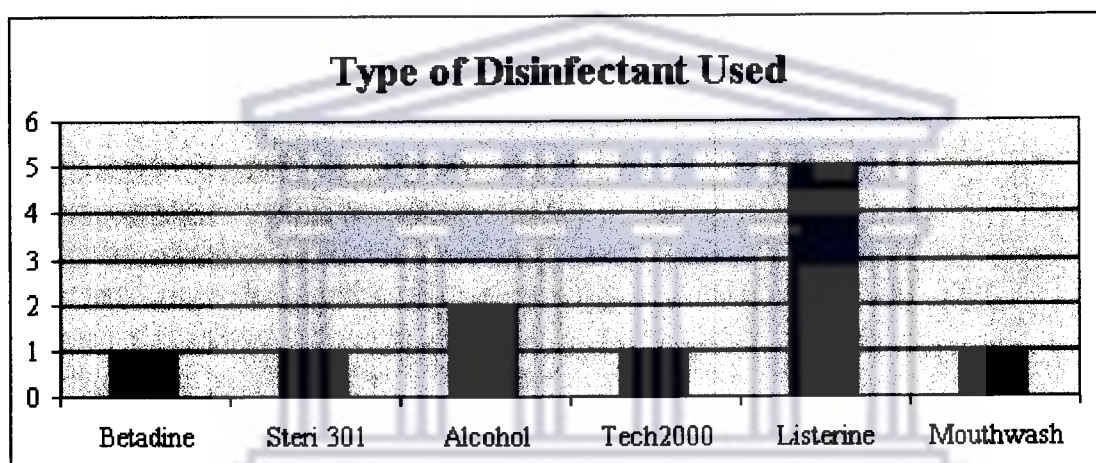


Figure 32: Type of disinfectant used

#### 5.2.5 Anaesthesia

Half the piercers (50%) use a topical anaesthetic before piercing. One piercer's response to the question "Do you use an anaesthetic before piercing?" was "Yes and No, depending on the patient's pain threshold and personal choice". The others (40%) did not use any form of anaesthetic.

#### 5.2.6 Emergency / First Aid

Almost all the piercers (n = 9; 90%) reported that they had a first aid kit on the premises, and one did not.

### 5.2.7 Aftercare instructions

All the piercers interviewed gave verbal advice, as well as written aftercare instructions to piercees. This ensured that piercees are well informed about what to expect after a piercing and how to take care of a new piercing. They were also advised that the barbell used initially for a tongue piercing, which has a shank of 22mm long, should be changed to one with a shank of 18mm or 16mm after a month or after the swelling has subsided. This was to avoid adverse dental consequences. However, all respondents reported that very few piercees return to change the barbell. The aftercare instructions inform piercees how to deal with pain, swelling, and difficulty eating, speaking and swallowing. They are also advised on the precautions that should be taken to avoid infection of the piercing site e.g. rinsing the mouth after smoking, no kissing, and to avoid swimming in public pools. However, instructions did not discuss excessive bleeding as a possible complication or how it should be dealt with.

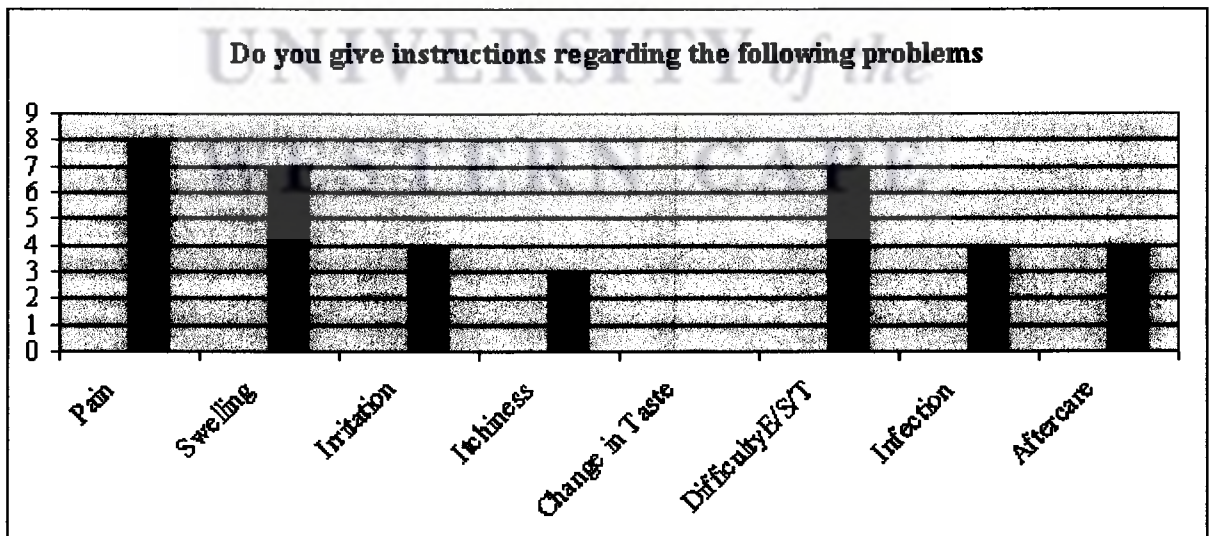


Figure 33: Aftercare instructions

## **CHAPTER 6: DISCUSSION**

To the best of our knowledge, this is the first study of oral and perioral piercings in a South African sample, to determine the common sites and complications associated with this practice.

This questionnaire-based survey of individuals with oral and perioral piercings indicates that this trend is common among sixteen to eighteen-year-olds. This study showed that more females have piercings than males and piercings of the tongue were more common than labrette or other perioral piercings. Although jewellery made of stainless steel, surgical steel and titanium are frequently used, a new plastic product on the market called bioplast, is gaining in popularity. This material is flexible, available in different colours, may be cut to the required size, and results in less swelling and decreased risk of infection.

Although the literature reports several cases in which hospital treatment was necessary, none of the subjects of this study required hospitalization for complications associated with a piercing. This study indicated that the nature of the complications reported, are commensurate with the piercing procedure and local tissue damage, and include swelling, pain, and initial difficulty eating, speaking, and swallowing. None of the respondents reported excessive bleeding after the procedure. This is due to the fact that the tongue is most frequently pierced in the midline, while the lingual veins and arteries are found running laterally (Boardman and Smith, 1997).



Long-term complications, experienced weeks or months after the piercing were related to the jewellery, rather than the actual piercing. Common dental problems included chipping and cracking of teeth, and gingival recession on the labial aspect of the lower incisors. Although some participants reported chipping of teeth, particularly upper central incisors, they indicated that this was a result of 'playing' with the jewellery in the mouth by continuously knocking the tongue against the palatal and lingual surfaces of the teeth.

This study found an association between lip piercings and gingival recession, similar to the findings of Sculley and Chen (1994) and Er et al (2000), and underlining the need for individuals who have piercings to be informed of possible periodontal consequences. In the present study chipping of teeth was only found in 10% of the respondents, in contrast to Keiser et al (2005) in New Zealand who reported chipping in 28% of participants, and De Moor and co-workers (2000), found that 12 of the 15 cases examined had chipping of teeth.

Campbell et al (2002) have reported a correlation between the length of the barbell and trauma to posterior teeth. This was verified by the piercers interviewed by the researcher, who stated that they asked clients to return after the swelling had subsided to change the barbell for one with a shorter bar. The longer shank barbell is to allow for the initial swelling following a piercing. However, most piercers reported that very few individuals return to change the long bar for a shorter one. Chambrone and Chambrone (2003) stated that if the long-shank barbell used for initial placement is not replaced, adverse consequences such as dental fractures may occur.

Those individuals who experienced chipping of teeth, had piercings of the tongue, and gingival recession occurred in subjects with lip piercings. These findings suggest that there is an association between piercings of the tongue and damage to teeth (hard tissue) and lip piercings, and lip piercings and damage to gingival (soft tissue). In this study sample, the number of cases of oral and dental complications associated with piercings of the lip was significantly smaller than those related to tongue piercings, concurring with the findings of Chambrone and Chambrone (2003).

One of the piercees reported that the ball of the labrette on the inside of the oral cavity caused gingival recession because it was too sharp, and when the ball was changed to a smaller one, the situation improved. One of the piercers interviewed, maintained that the thinner and finer the buccal aspect of the jewellery worn in a lip piercing is, the more likely it is to cause gingival recession, because it 'hooks' onto the gingival margin. Soft tissue trauma or tearing may also occur as a result of friction with the jewellery, and one participant reported damage to the palate. A case of sensitivity of upper central incisors was also reported. This was first suggested by Dianjelis (1997) who reported two cases of cold sensitivity attributed to cracked tooth syndrome, following the placement of a lingual barbell. He proposed that the barbells act as a stressor that may propagate cracks in enamel and dentine.

It was apparent from this study that the number of dental complications increased with the duration of the piercing. Of the 17.56% (n = 22) of the sample that experienced problems, eleven had had the piercing for more than two years, four had it for 1-2 years, 2 had the piercing for between six and twelve months, and five had the jewellery in place for under six months.



The cross-infection measures practiced by the piercers interviewed in this study are commendable. The survey showed that piercers were aware of the possibility of cross-infection, and took the necessary precautions. All the piercers used disposable needles, and with the exception of one, all cleaned the site of piercing with an antibacterial agent. Although it was not included in the questionnaire, the majority reported using an autoclave to sterilise items.

It is reassuring that piercers adopt similar cross-infection control measures as health professionals. The piercers are aware of cross-infection and the possible spread of blood-borne diseases such as HIV; however, they did not seem to be aware of the importance of a medical history before performing the piercing procedure. One piercer stated that the onus was on the client to make sure that he/she was fit to undergo the procedure, and in the case of minors, it was the responsibility of the parent or guardian. This is cause for concern, and indicates that some form of legislation should be implemented to standardise the body piercing industry.

All the piercers gave clients verbal as well as written instructions on care of the piercing during the recovery period. It was recommended that:

- the hands are washed before touching or cleaning the pierced area, which should be cleaned twice a day
- kissing and oral sex should be avoided
- public swimming pools, jacuzzis and steam baths should be avoided
- in order to prevent keloid or scar tissue, avoid fiddling with the jewellery
- an antibacterial mouthwash that does not contain alcohol should be used after meals.

## **CHAPTER 7: CONCLUSION**

The increasing popularity of lip and tongue piercings is of significance to the dental profession. The review of the medical and dental literature has revealed oral/dental and medical complications arising from these piercings, including some life-threatening complications.

As the practice of body piercing, particularly oral and perioral piercing continues, the dental profession needs to be aware of the risk for damage to soft and hard tissue. Dental personnel have a role in informing patients about the potential risks, and the importance of wearing appropriate jewellery, e.g. a barbell with a shank of the correct length, to avoid chipping teeth.

In the first 24 to 48 hours after a piercing, most individuals experience pain, swelling, and difficulty eating, speaking and swallowing, which are regarded as normal sequelae following the procedure and only a minority require medical intervention or the advice of a healthcare professional.

The findings of this study suggest that a number of clinical parameters increase the risk of damage. These include the barbell shank length, habitually biting, chewing or playing with the pierced item, and the length of time that the piercing has been in the mouth. Since the general population is not aware of these potential complications, no professional medical or dental opinion is sought prior to oral piercings. It is important that as part of the informed consent process, prospective piercees are informed of the likelihood of dental consequences.

## REFERENCES

- Akhondi H, Rahimi A R. Haemophilus aphrophilus endocarditis after tongue piercing. *Emerg Infect Dis* 2002; **8**: 850-851.
- Armstrong M L, Ekmark E, Brooks B. Body piercing: promoting informed decision making. *J Sch Nurs* 1995; **112**: 20-25.
- Armstrong M L. You pierced what? *Pediatr Nurs* 1996; **22**: 236-238.
- Boardman R, Smith R A. Dental Implications of oral piercing. *J Calif Dent Assoc* 1997; **25**: 200-207.
- Botchway C, Kuc I. Tongue piercing and associated tooth fracture. *J Can Dent Assoc* 1998; *Br Dent J* 2000; **188**: 657-658. **64**: 803-805.
- Brennan M, O'Connell B, O'Sullivan M. Multiple dental fractures following tongue barbell placement: a case report. *Dent Traumatol* 2006; **22**: 41-43.
- Brooks J K, Hooper K A, Reynolds M A. Formation of mucogingival defects associated with intraoral and perioral piercing. *JADA* 2003; **134**: 837-843.
- Campbell A, Moore A, Williams E, Stephens J, Tatakis DN. Tongue piercing: impact of time and barbell stem length on lingual gingival recession and tooth chipping. *J Periodontol* 2002; **73**: 289-297.
- Chambrone L, Chambrone LAC. Gingival recession caused by lip piercing: case report. *J Can Dent Assoc* 2003; **69**: 505-8.
- Chen M, Scully C. Tongue piercings: a new fad in body art. *Br Dent J* 1992; **172**: 87.
- Diangelis AJ. The lingual barbell: a new etiology for the cracked-tooth syndrome. *JADA* 1997; **128**: 1438-1439.
- Dubose J, Pratt J W. Victim of fashion: Endocarditis after oral piercing. *Curr Surg* 2004; **61**: 474-476. An original report published by Elsevier Inc. on behalf of the Association of Program Directors in Surgery.
- Er N, Ozkavaf A, Berberoglu A, Yamalik N. An unusual cause of gingival recession. *J Periodontol* 2000; **71**: 1767-1769.
- Farah C S, Harmon D M. Tongue piercing: Case report and review of current practice. *Aust Dent J* 1998; **43**: 387-389.
- Fehrenbach M J. Tongue piercing and potential oral complications. *J Dent Hyg* 1998; **72**: 23-25.

Folz B J, Lippert B M, Kuelkens C, Werner J A. Hazards of piercing and facial body art: a report of three patients and literature review. *Ann Plast Surg* 2000; **45**: 374-381.

Hardee P S G F, Mallya L R, Hutchison I L. Tongue collapse resulting in hypotensive collapse. *Br Dent J* 2000; **188**: 657-658.

Kieser J A, Thomson W M, Koopu P, Quick A N. Oral piercing and oral trauma in a New Zealand sample. *Dent Traumatol* 2005; **21**: 254-257.

Kretchmer M C, Moriarty J D. Metal piercing through the tongue and localized loss of attachment : a case report. *J Periodontol* 2001; **72**: 831-833.

Lick S D, Edozie S N, Woodside K J, Conti V R. Streptococcus viridans endocarditis from tongue piercing. *J Emerg Med* 2005; **29**: 57-59.

Maibaum W W, Margherita V A. Tongue piercing: a concern for the dentist. *Gen Dent* 1997; **45**: 495-497.

Martinello R A, Cooney E L. Cerebellar brain abscess associated with tongue piercing. *CID* 2003; **36**: 32-34. Brief Report.

Mayers L B, Judelson D, moriarty B, Rundell K. Prevalence of body art (body piercing and tattooing) in University undergraduates and incidence of medical complications. *Mayo Clin Proc* 2002; **77**: 29-43.

Meskin L H. A few piercing thoughts. *J Am Dent Assoc* 1998; **129**: 1519-1520.

O'Dwyer JJ, Holmes A. Gingival recession due to trauma caused by a lower lip stud. *Br Dent J* 2002; **192**: 615-6.

Perkins C S, Harrison J M. A complication of tongue piercing. *Br Dent J* 1997; **182**: 147-148.

Price S S, Lewis M W. Body piercing involving oral sites. *J Am Dent Assoc* 1997; **128**: 1017-1020.

Ram D, Peretz B. Tongue piercing and insertion of metal studs: Three cases of dental and oral consequences. *J Dent Child* 2000; **67(5)**: 326-329.

Reichl R B, Dailey J C. Intraoral body piercing: a case report. *Gen Dent* 1995; **44**: 346-347.

Rosivak R A, Kao J Y. Prolonged bleeding following tongue piercing: a case report and review of complications. *J Pediatr Dent* 2002; **25:2**: 154-156.

Sardella A, Pedrinazzi M, Bez C, Lodi G, Carrassi A. Labial piercing resulting in gingival recession. A case series. *J Clin Periodontol* 2002; **29**: 961-3.

Scully C, Chen M. Tongue piercing (oral body art). *Br J Oral Maxillofac Surg* 1994; **32**: 37-38.


Shacham R, Zaguri A, Librus H Z, Bar T, Eliav E, Nahlieli O. Tongue piercing and its adverse effects. *Surg Oral Med Oral Pathol Oral Radiol Endod* 2003; **95**: 274-276.

Theodossy T. A complication of tongue piercing. A case report and review of the literature. *Br Dent J* 2003; **194**: 551-552.

Trachsel D, Hammer J. A vote for inhaled adrenaline in the treatment of severe upper airway obstruction caused by piercing of the tongue in hereditary angioedema. *Int Care Med* 1999; **25**: 1335-1336.

Wise H. Hypoxia caused by body piercing. *Anaesthesia* 1999; **54**: 1129.

Write J. Modifying the body: piercing and tattoos. *Nurs Stand* 1995; **10**: 27-30. 1999; **25**: 1335-1336.



UNIVERSITY *of the*  
WESTERN CAPE

## APPENDICES



UNIVERSITY *of the*  
WESTERN CAPE



**APPENDIX A**



UNIVERSITY *of the*  
WESTERN CAPE



facsimiletransmit

<b>To:</b>	The Chairperson of the Governing Body	<b>Fax No:</b>	(012) 343 2359
<b>Co:</b>	Pretoria Technical High School	<b>Date:</b>	Wednesday, 29 March 2006
<b>From:</b>	Ruebecca Ebrahim	<b>Pages:</b>	One

RE: Request for Permission to interview your learners

I am in my final year of research for my Masters dissertation (MSc. Dental Public Health) at the University of Western Cape. My student number is: 2467794

The topic for my research thesis is "*An Investigation into Oral and Perioral Piercing.*" For research purposes I have to interview as many people with piercing of the lip and/or tongue as possible. This study has not been previously undertaken in South Africa; however, studies undertaken overseas have indicated dental problems. I hope that my research will assist in minimising these problems in South Africa.

I understand that some of the learners at your School may have pierced their lips or tongue, and it would be beneficial to my research to meet with such learners.

Should you wish to verify any of the above information, my Supervisor is:

Professor Sue Naidoo  
University of Western Cape  
Department of Community Dentistry  
Contact Telephone Number : (021) 937 3148.

I would appreciate your faxed reply.

Thanking you.

Yours Sincerely  
Ruebecca Ebrahim

**CONFIDENTIAL**

**APPENDIX B**



UNIVERSITY *of the*  
WESTERN CAPE



To: Mr G.R. Agocs  
Pretoria Technical High School  
Private Bag X346  
Pretoria  
0001

17<sup>th</sup> May 2006  
Hand Delivered

Re: Request to Interview Learners

Dear Sir

I have spoken to Mr. Enslin, who suggested that I put my request to you in writing.

Please find attached copies of:

- The original fax sent to your school
- The letter of approval from the Department of Education
- My questionnaire

Your consideration of this matter would be appreciated.

Should you have any queries please contact me.

Thanking You  
Ruebecca Ebrahim

P.O. Box 58  
Pretoria 0001  
South Africa

Email: [faarte@hotmail.com](mailto:faarte@hotmail.com)

<http://etd.uwc.ac.za/>

**APPENDIX C**



UNIVERSITY *of the*  
WESTERN CAPE



P. O. Box 58  
Pretoria 0001 South Africa

Tel: +27 (012) 374 3035  
Fax: +27 (012) 374 0775  
Cell: 082 778 6640  
E-mail: lebrahim@mweb.co.za

facsimiletransmital

<b>To:</b>	Ms Marie van Schalkwyk	<b>Fax No:</b>	012- 651 4434/5
<b>Co:</b>	Voortrekkerhoogte Hoerskool	<b>Date:</b>	Tuesday, 16 May 2006
<b>From:</b>	Ruebecca Ebrahim	<b>Pages:</b>	One + two

Re: Request to interview students with oral (lip and tongue) piercings.

Attached please find a copy of the permission granted by the Dept. of Education to conduct research at schools.

Should you have any queries please do contact me.

With kind regards.

Yours sincerely,  
Ruebecca Ebrahim



UNIVERSITY of the  
WESTERN CAPE

**CONFIDENTIAL**



**APPENDIX D**



UNIVERSITY *of the*  
WESTERN CAPE



facsimiletransmital

<b>To:</b>	Ms Eunice Masemola	<b>Fax No:</b>	012 – 326 5298
<b>Co:</b>	Tshwane North College	<b>Date:</b>	Wednesday, 17 May 2006
<b>From:</b>	Ruebecca Ebrahim	<b>Pages:</b>	Three

Re: Request to interview students with oral (lip and tongue) piercings.

Dear Madam

Regarding our telephonic conversation, and my inability to reach Mr. Joseph Toba, herewith details of my request.

I am in my final year of research for my Masters Dissertation (MSc.Dental Public Health) at the University of western Cape.

The topic for my research thesis is "An Investigation into Oral and Perioral Piercings."

For research purposes, I am required to interview people with piercings of the lip and/or tongue. This study has not been undertaken in South Africa, however studies overseas have indicated dental problems. I hope that my research will assist in minimizing these problems in South Africa.

I understand that some of the learners at your college have piercings, and it would be beneficial to my research to meet with them. I hope that you can assist me in this regard.

Attached please find a copy of the permission granted by the Dept. of Education to conduct research at schools.

Should you have any queries please do contact me.

With kind regards.

Yours sincerely,  
Ruebecca Ebrahim

**CONFIDENTIAL**

**APPENDIX E**



UNIVERSITY *of the*  
WESTERN CAPE

**Liaquat (Charles) Ebrahim**

**From:** "Liaquat (Charles) Ebrahim" <lebrahim@mweb.co.za>  
**To:** <timothym@gpg.gov.za>  
**Sent:** 22 February 2006 10:15  
**Subject:** Request permission

Department of Education

Dear Mr. Michael Nkwane

I have spoken to Mrs Gerda Labuschange, who suggested that I write to you.

I am a Master's student (MSc. Dental Public Health) at the Department of Community Dentistry, Faculty of Dentistry, University of Western Cape.

I am interested in doing my research thesis on "Infections associated with piercing of the oral cavity - lip and tongue piercing". In order to do this I require to interview candidates between the ages of sixteen and twenty-three.

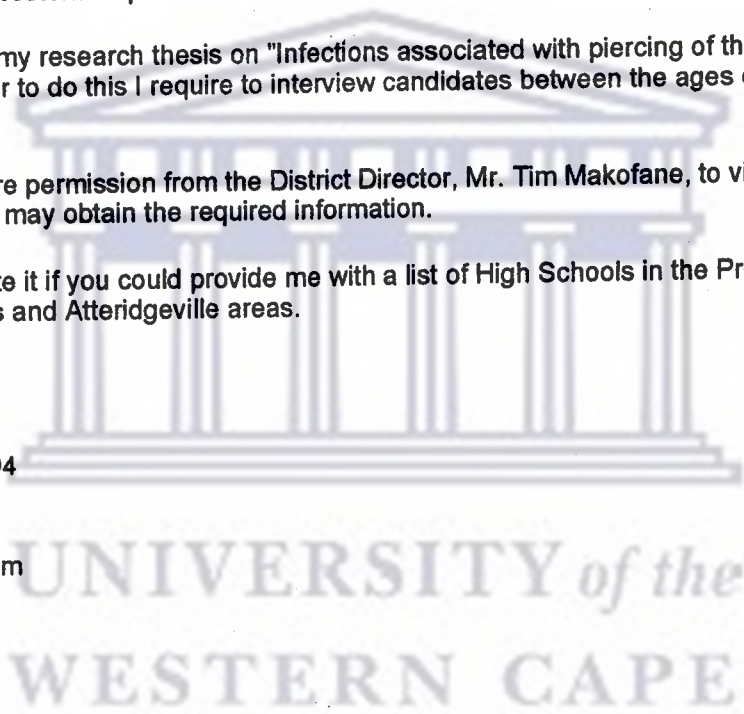
I understand that I require permission from the District Director, Mr. Tim Makofane, to visit schools in the Pretoria West area, from where I may obtain the required information.

I would greatly appreciate it if you could provide me with a list of High Schools in the Pretoria west, Danville, Laudium, Lotus Gardens and Atteridgeville areas.

Thanking You  
Yours Sincerely  
Ruebecca Ebrahim  
Reg. No. UWC - 2467794

Liaquat [Charles] Ebrahim  
P. O. Box 58  
Pretoria 0001  
South Africa

Tel: +27 12 374 3035  
Fax: +27 12 374 0775  
Mobile: 082 778 6640



22-Feb-06

**APPENDIX F**



UNIVERSITY *of the*  
WESTERN CAPE

## PROCESS TO FOLLOW WHEN APPLYING TO DO RESEARCH IN GDE SCHOOLS

1. **Students who apply through this District** do not necessarily have to do the research in the schools in District Tshwane South. The District Office assists them to apply for approval from Head Office.
2. **Students should complete the Application form** which requires to have
  - a **Proposal** regarding what research the student wishes to do ( a copy of the proposal submitted to the Institution of learning where the student is enrolled is excellent).
  - an **approved questionnaire**, if the student is using a questionnaire. The questionnaire should be approved by the ethics committee at the Institution where the student is enrolled.
  - the **lecturer/promotor** of the student is required to complete a portion of the Application form.
  - the **names of GDE institutions/schools** in the District that the student wishes to enter to do the research should appear on the application form.
3. **The student should note the following:**
  - **The Senior Manager of the District** should approve these schools to be used for research via the Policy and Planning Official working with Research applications.
  - **It takes TWO months** to be granted approval for research to be done in any GDE institution. The application is processed by the Research Committee at Head Office.
  - **NO research may be done in GDE Schools** from 30 September of a year to the end of the second week of the following February. ( This is the time when schools do final Assessment and evaluation of learners' work and when the new school year begins. Learners are placed into new classes/schools with different educators and they need to be given time to settle down).
4. **The Application Form and Annexures** may be submitted by e-mail to the GDE Head Office. The e-mail address is given on the last page of the Application Form. The Application form can also be submitted to Head Office via the Policy and Planning Unit of the District.
5. **When Approval has been granted** to the student by the GDE Head Office that student should let the District Policy and Planning Unit know **and send a copy of the approval form to the Policy and Planning Unit of the District.**
6. Once the District has the Approval forms the student should verify the schools where he/she wishes to work, lets the Policy and Planning Unit know and the Unit will inform these schools. If this is not done there can be a delay in the student's research.



7. The student must carry a copy of the GDE's Approval form with her/him when entering the schools to do research. A student should always report to the Principal on entering the school.
8. Once the Research has been completed and evaluated, the student must send a copy to the Research Committee of the GDE at Head Office for it to be evaluated, accessed and placed into the GDE Library. ( The copy can also be handed in to the Policy and Planning Unit who can be requested to send it to the GDE Head Office for processing).
9. The Policy and Planning Official at the District Office will have the names of the persons who work with Research at the GDE Head Office.



UNIVERSITY *of the*  
WESTERN CAPE

**APPENDIX G**



UNIVERSITY *of the*  
WESTERN CAPE



Date:	28 April 2006
Name of Researcher:	Ebrahim Ruebecca
Address of Researcher:	20 Delhi Street
	Laudium
	Pretoria 0001
Telephone Number:	(012) 3744150
Fax Number:	(012) 3740775
Research Topic:	An investigation into the practice of oral and perioral piercings
Number and type of schools:	6 Secondary Schools
District/s/HO	Tshwane North & South

**Re: Approval in Respect of Request to Conduct Research**

This letter serves to indicate that approval is hereby granted to the above-mentioned researcher to proceed with research in respect of the study indicated above. The onus rests with the researcher to negotiate appropriate and relevant time schedules with the school/s and/or offices involved to conduct the research. A separate copy of this letter must be presented to both the School (both Principal and SGB) and the District/Head Office Senior Manager confirming that permission has been granted for the research to be conducted.

Permission has been granted to proceed with the above study subject to the conditions listed below being met, and may be withdrawn should any of these conditions be flouted:

1. *The District/Head Office Senior Manager/s concerned must be presented with a copy of this letter that would indicate that the said researcher/s has/have been granted permission from the Gauteng Department of Education to conduct the research study.*
2. *The District/Head Office Senior Manager/s must be approached separately, and in writing, for permission to involve District/Head Office Officials in the project.*
3. *A copy of this letter must be forwarded to the school principal and the chairperson of the School Governing Body (SGB) that would indicate that the researcher/s have been granted permission from the Gauteng Department of Education to conduct the research study.*

Office of the Senior Manager – Strategic Policy Research & Development  
Room 525, 111 Commissioner Street, Johannesburg, 2001 P.O.Box 7710, Johannesburg, 2000  
Tel: (011) 355-0488 Fax: (011) 355-0286

4. A letter / document that outlines the purpose of the research, and the anticipated outcomes of such research must be made available to the principals, SGBs and District/Head Office Senior Managers of the schools and districts/offices concerned, respectively.
5. The Researcher will make every effort obtain the goodwill and co-operation of all the GDE officials, principals, chairpersons of the SGBs, teachers and learners involved. Persons who offer their co-operation will not receive additional remuneration from the Department while those that opt not to participate will not be penalised in any way.
6. Research may only be conducted after school hours so that the normal school programme is not interrupted. The Principal (if at a school) and/or Senior Manager (if at a district/head office) must be consulted about an appropriate time when the researcher/s may carry out their research at the sites that they manage.
7. Research may only commence from the second week of February and must be concluded before the beginning of the last quarter of the academic year.
8. Items 6 and 7 will not apply to any research effort being undertaken on behalf of the GDE. Such research will have been commissioned and be paid for by the Gauteng Department of Education.
9. It is the researcher's responsibility to obtain written parental consent of all learners that are expected to participate in the study.
10. The researcher is responsible for supplying and utilising his/her own research resources, such as stationery, photocopies, transport, faxes and telephones and should not depend on the goodwill of the institutions and/or the offices visited for supplying such resources.
11. The names of the GDE officials, schools, principals, parents, teachers and learners that participate in the study may not appear in the research report without the written consent of each of these individuals and/or organisations.
12. On completion of the study the researcher must supply the Senior Manager: Strategic Policy Development, Management & Research Coordination with one Hard Cover bound and one Ring bound copy of the final, approved research report. The researcher would also provide the said manager with an electronic copy of the research abstract/summary and/or annotation.
13. The researcher may be expected to provide short presentations on the purpose, findings and recommendations of his/her research to both GDE officials and the schools concerned.
14. Should the researcher have been involved with research at a school and/or a district/head office level, the Senior Manager concerned must also be supplied with a brief summary of the purpose, findings and recommendations of the research study.

The Gauteng Department of Education wishes you well in this important undertaking and looks forward to examining the findings of your research study.

Kind regards



ALBERT CHANEE  
ACTING DIVISIONAL MANAGER OFSTED

<b>The contents of this letter has been read and understood by the researcher.</b>	
<b>Signature of Researcher:</b>	
<b>Date:</b>	

**APPENDIX H**



UNIVERSITY *of the*  
WESTERN CAPE

19<sup>th</sup> April 2006

To Whom It May Concern

Department of Education  
Pretoria

Dear Sir/Madam

I am doing my Masters in Dental Public Health at the University of Western Cape. My thesis research topic is "An Investigation into the practice of oral and Perioral Piercings," for which I am required to interview people with piercings of the mouth and tongue. As this practice is common among teenagers and young adults, I am likely to find many candidates at secondary schools and colleges.

I have spoken to Mr. Michael Nkwane, who gave me the necessary documentation.

Regarding my request for permission to interview students at secondary institutions in Tshwane, please find attached:

1. Research Request Form
2. Protocol
3. Questionnaire and Consent Form
4. Declaration by Supervisor


Many Thanks  
Ruebecca Ebrahim



**APPENDIX I**



UNIVERSITY *of the*  
WESTERN CAPE



# ATTENTION

Do you have your lip and / or tongue pierced?

Do you want your name entered in a lucky draw?

You do?


**Come and see me at the STUDENT SUPPORT CENTRE, on Friday 24 February 2006, between 9h00 and 12 midday, for a chat.**

**RUEBECCA EBRAHIM**  
Contact number- 0836597786

**APPENDIX J**



UNIVERSITY *of the*  
WESTERN CAPE



# ATTENTION

Do you have your lip and / or tongue  
pierced?

You do?

Come and see me

*At*

**PRETORIA CAMPUS STAFF ROOM-1<sup>st</sup> FLOOR**

*On*

**WEDNESDAY – 24 MAY 2006**

*And*

**THURSDAY – 25 MAY 2006**

**BETWEEN 09H00 AND 12.00**

RUEBECCA EBRAHIM  
Contact number- 0836597786

**APPENDIX K**



UNIVERSITY *of the*  
WESTERN CAPE

**CONSENT FOR ORAL EXAMINATION**

**March/April 2006**

I am a Masters student at the Faculty of Dentistry, Department of Community Dentistry at the University of the Western Cape. We are interested in looking at your mouth and teeth to look for any problems related to your piercing and mouth jewellery. We are doing this to see if there are ways in which we can prevent any problems or help with any problems you may have.

The procedure will take about 15-20 minutes. There are no risks in participating and there should be no more discomfort than in a routine dental check up examination. All information gathered in the study, will be strictly confidential. No one will have access to this information except the researcher. Neither your name nor anything that identifies you will be used in any reports of this study. All information collected, will be stored in such a way as to keep it as confidential as possible. You may leave the study at any time without any penalties. We may take photographs, but this will only be of your mouth and teeth and no one will be able to identify you or recognise you in any way.

If you would like to take part in the study, please sign the bottom of this letter. If you would like to know anything more about the study, please contact Ruebecca Ebrahim on telephone number 012 - 374 4150 or 083 659 7786.

Thank you for your co-operation

Yours sincerely  
Ruebecca Ebrahim

-----  
I understand what will be required of me to take part in the study. I agree to participate in the research being undertaken by Ruebecca Ebrahim and that at any time I may withdraw from this study without giving a reason.

Name: .....  
(print in block letters)

.....  
(Signature)

Telephone Number: .....

Date: .....

Witness: .....



**APPENDIX L**



UNIVERSITY *of the*  
WESTERN CAPE

### MOUTH PIERCING: Data Capture Sheet

Date of examination: .....

1. Name & Record Number: .....

2. Age (years): .....

3. Gender: M                      F

4. Ethnic Group: .....

5	Where in the mouth do you have piercings?					
5.1	Lips (outside)	Y	N	No.	Type:	Metal:
5.2	Lips (inside)	Y	N	No.	Type:	Metal:
5.3	Tongue	Y	N	No.	Type:	Metal:
5.4	Fraenum	Y	N	No.	Type:	Metal:
5.5	Cheek	Y	N	No.	Type:	Metal:
5.6	Uvula	Y	N	No.	Type:	Metal:
5.7	Other (specify):					
5.8	Who did the piercing(s) for you?					
	Piercing studio					
	Tattoo studio					
	Dentist					
	Doctor					
	Myself					
	Other:					

6	For how long have you had the piercings ?				
		<b>&lt;6months</b>	<b>6-12months</b>	<b>1-2 years</b>	<b>&gt;2 years</b>
6.1	Lips				
6.2	Tongue				
6.3	Gums				
6.4	Other site (specify):				

<b>7</b>	<b>What were your main reasons for piercing your mouth?</b>

\*\*\*Type: barbells, tongue rings, lip rings, balls, labrette etc

Metal: 14k gold, 18k gold, silver, surgical stainless steel, titanium, niobium, silver plate etc

<b>8</b>	<b>Immediately after the piercing did you experience any of the following:</b>		
8.1	Pain	Y	N
8.2	Swelling	Y	N
8.3	Irritation	Y	N
8.4	Itchiness	Y	N
8.5	Change in taste sensation	Y	N
8.6	Difficulty with speaking, eating, swallowing	Y	N
8.7	Other (specify)		

<b>9</b>	<b>After the piercing what did you do:</b>		
9.1	Nothing	Y	N
9.2	Used antiseptic, gargle, mouthwash	Y	N
9.3	Took painkillers	Y	N
9.7	Other (specify):		

<b>10</b>	How long did it take to heal?	Few days	1 week	more than a week	months
-----------	-------------------------------	----------	--------	------------------	--------


<b>11</b>	Since the piercing, did you notice any damage to your teeth or gums?	Y	N
	If yes, please specify:		

<b>12</b>	<b>Since the piercing, have you experienced any of the following problems:</b>		
12.1	Pain	Y	N
12.2	Difficulty eating	Y	N
12.3	Difficulty speaking	Y	N
12.4	Difficulty swallowing	Y	N
12.5	Swelling in your glands	Y	N
12.6	Infection around the pierced area	Y	N
12.7	Other (specify):	Y	N
<b>13</b>	<b>If you had experienced problems since the piercing, what did you do:</b>		
13.1	Removed the item	Y	N
13.2	Took pain killers	Y	N
13.3	Used a mouth wash/gargle/rinse	Y	N
13.4	Other (specify):	Y	N

14	<b>If you had experienced problems since the piercing, did you go to a:</b>		
14.1	Dentist	Y	N
14.2	Doctor	Y	N
14.3	The person who did the piercing	Y	N
	<b>If yes, what did he/she do?</b>		
14.3	Removed the item	Y	N
14.4	Gave me pain killers	Y	N
14.5	Gave me antibiotics	Y	N
14.6	Gave me a mouth wash/gargle/rinse	Y	N
14.7	Other (specify)	Y	N

15	<b>How do you clean your piercing? Please describe.</b>		

<b>Photographs taken</b>	Y	N
--------------------------	---	---



**APPENDIX M**



UNIVERSITY *of the*  
WESTERN CAPE

**PIERCERS' CONSENT FORM**

**August 2006**

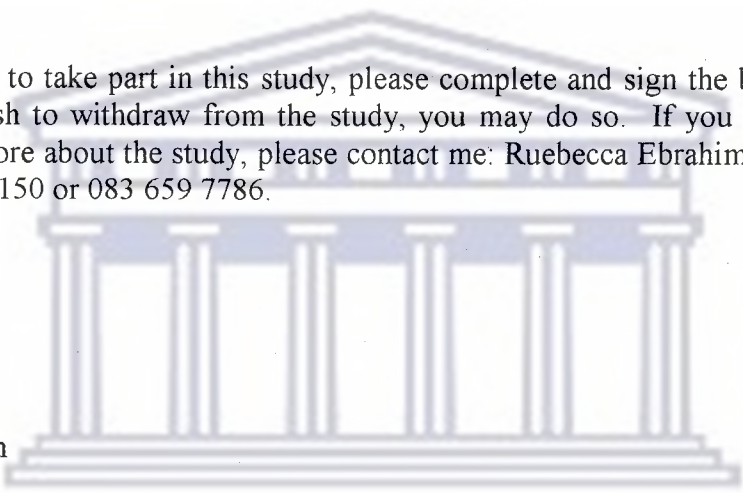
I am a Masters student at the Department of Community Dentistry, Faculty of Dentistry, at the University of Western Cape. We are interested in any problems related to piercings of the mouth or mouth jewellery. We are doing this to see if there is any way in which we can prevent or help with any problems that may occur.

The interview will take about 10-15 minutes. All information gathered in this study is strictly confidential, and only the researcher will have access to this information. Neither your name nor anything that identifies you will be used in any reports of this study. All information collected, will be stored in such a way as to keep it as confidential as possible.

If you would like to take part in this study, please complete and sign the bottom of this letter. If you wish to withdraw from the study, you may do so. If you would like to know anything more about the study, please contact me: Ruebecca Ebrahim on telephone number 012-3744150 or 083 659 7786.

Yours sincerely

Ruebecca Ebrahim



-----  
**I agree to participate in the research being undertaken by Ruebecca Ebrahim. I also understand what is required of me to participate in this study. I am aware that I am free to withdraw from this study at any time without providing a reason.**

**Name:** .....  
**(print in block letters)**

.....  
**(Signature)**

**Telephone Number:** .....

**Date:** .....

**Witness:** .....



**APPENDIX N**



UNIVERSITY *of the*  
WESTERN CAPE

## PIERCERS QUESTIONNAIRE

Name: ..... Date of interview: .....

**1. What metal do you use for piercing?**

Silver	
Silver plate	
Stainless steel	
14 k gold	
18 k gold	
Titanium	
Niobium	
Other	

**2. Have clients reported any complications following piercing?** Yes / No

**3. If yes, have any of the following complications been reported?**

	Yes	No
Pain		
Swelling		
Irritation		
Itchiness		
Change in taste sensation		
Difficulty with eating, speaking, swallowing		
Infection		
Other (specify)		

**4. Which one is most commonly reported? .....**

**5. Do you use any disinfectant to clean the area before piercing?** Yes/No

**6. If yes, what do you use: .....**

**7. Do you use any anaesthetic before performing piercing?** Yes / No

**8. If yes, do you use disposable needles?** Yes / No

**9. Do you have an emergency/first aid kit?** Yes / No

**10. Do you give clients after-care instructions?** Yes / No

**11. If yes, do you give instructions regarding the following problems?**

	Yes	No
Pain		
Swelling		
Irritation		
Itchiness		
Change in taste sensation		
Difficulty with eating, speaking, swallowing		
Infection		
Other (specify)		

Ref: Piercer's Questionnaire